

HTA REPORT

**Wireless Capsule Endoscopy
in the diagnosis of small bowel disease**

This report should be cited as "Age.na.s. HTA Report - Wireless Capsule Endoscopy in the diagnosis of small bowel disease, Rome, September 2008"

Contributions

Authors:

Fabio Bernardini, Marina Cerbo, Tom Jefferson, Alessandra Lo Scalzo, Marco Ratti
*Age.na.s. Agenzia nazionale per i servizi sanitari regionali,
Sezione ISS (Innovazione, Sperimentazione e Sviluppo), Rome (Italy)*

Corresponding author:

Alessandra Lo Scalzo (loscalzo@agenas.it)

Experts:

Lucio Capurso
Senior Consultant (Gastroenterology) - Azienda Ospedaliera "San Filippo Neri", Rome (Italy)

Antonio Migliore
*Consultant (Biomedical Engineering) - age.na.s. Agenzia nazionale per i servizi sanitari regionali,
Sezione ISS (Innovazione, Sperimentazione e Sviluppo), Rome (Italy)*

External Reviewers:

Roberto De Franchis
*Department of Medical Sciences,
University of Milan (Italy)*

Brendan C. Delaney
*Primary Care Clinical Sciences,
University of Birmingham, Birmingham (UK)*

Francesco Martelli
*Dipartimento Tecnologie e Salute,
ISS – Istituto Superiore di Sanità, Rome (Italy)*

In this report Given Imaging GmbH and MG Lorenzatto S.p.A. are not cited as "external reviewers" since, although they had been involved in its production process, they communicated that they do not agree with the report's conclusions. Given Imaging GmbH and MG Lorenzatto S.p.A. stated that the report does not include/consider some of the important comments and points they made.

Il presente report non contiene il riferimento delle aziende Given Imaging GmbH e MG Lorenzatto S.p.A. come "external reviewers". Tali aziende, pur essendo state contattate durante l'elaborazione del report, hanno comunicato di non riconoscersi nelle conclusioni dello stesso, dal momento che non ritengono essere stati presi in considerazione i commenti e le modifiche dalle stesse proposti.

Editing and layout

Dario Fella

Age.na.s. Agenzia Nazionale per i Servizi Sanitari Regionali

Acknowledgements:

The Agenzia Nazionale per i Servizi Sanitari Regionali (age.na.s.) thanks all the external reviewers who kindly provided comments on an earlier draft of this report.

The Age.Na.S. also thanks those who contributed to the realisation of this report providing market details, Paolo Gazzaniga and Fernanda Gellona from Association of producers and distributors of medical devices (ASSOBIOMEDICA) and the responding medical centres of endoscopy and gastroenterology (see Appendix 7).

Age.Na.S. also thanks Carlo Di Pietrantonj and Alessandro Rivetti from SEREMI (Servizio di riferimento Regionale di Epidemiologia, ASL 20, Alessandria, Italy) for their help in designing and carrying out the search strategy.

HTA REPORT
Wireless Capsule Endoscopy
in the diagnosis of small bowel disease

Executive summary	11
Sintesi	13
1. Background	
1.1 Clinical problem and indications	19
1.1.2. Obscure gastrointestinal bleeding (OGIB)	19
1.1.3 Crohn Disease (CD)	20
1.1.4 Coeliac disease (COD)	20
1.1.5 Familial Adenomatous Polyposis (FAP)	20
2. Technology, procedure and alternatives	
2.1. Technology	23
2.2 Procedure	23
2.3 The alternatives	24
3. The marketing status of WCE and current reimbursement arrangements	27
4. Report's objectives: policy question and research questions	29
5. Assessing the available evidence	
5.1 Methods	31
5.1.1 Health Technology Assessments reports and systematic reviews	31
5.1.2 Primary studies	31

5.1.3 Inclusion criteria	31
5.2 Assessing the available evidence: diagnostic accuracy	32
5.3 Assessing the available evidence: safety of WCE	38
5.4 Assessing the available evidence: Systematic reviews and meta analyses	40
5.5 Assessing the available evidence: WCE acceptability to patients	41
5.6 Results	41
6. Collecting context specific data	
6.1 Appropriateness of WCE use and related costs in the Italian context	45
6.1.1 Objective, materials and methods	45
6.1.2 Results	46
6.2 An assessment of patient's acceptability of the WCE procedure	62
6.2.1 Objective, materials and methods	62
6.2.2 Results	63
6.2.2.1 Socio economical characteristics of patients	63
6.2.2.2 Acceptability dimensions for the WCE and other endoscopies	65
7. Discussion	69
8. Recommendations	71
9. Funding	73
10. Conflict of interest	75
Glossary	77
Abbreviations	83
Bibliography	85
Appendix	
1. Expert Opinion Questionnaire Wireless Capsule Endoscopy (WCE)	89
2a. Wireless capsule endoscopy (WCE)	91

2b. Standard technology for diagnosis of bowel diseases	97
3. Search Strategy	105
4. Tables of comparative studies	107
5. Tables on Safety	129
6. List of citations and reasons for exclusion	133
7. Author questions	159
8. Responding Centres	161
9. Questionnaire Wireless Capsule Endoscopy	163
10. Wireless capsule and traditional Endoscopy: patient acceptability	173

Executive summary

One-liner

A quick diagnosis for occult bleeding in the gut is necessary. We summarised the evidence of performance and impact of the video capsule developed for this purpose.

Background

The Wireless Capsule Endoscopy (WCE) is a recent technology that allows imaging of the small intestine, an anatomic site that has proved peculiarly difficult to visualise. The patient swallows a small capsule, which whilst moving through the gastrointestinal tract, captures images. The main indication for WCE use is diagnosis of Obscure Gastrointestinal Bleeding in adults, which is defined as bleeding of unknown origin that persists, or recurs, or is visible after a negative colonoscopy and/or upper endoscopy result. Obscure Gastrointestinal Bleeding is a syndrome or group of symptoms rather than a single pathology, and as such makes it difficult to make reliable estimates of prevalence. In recent years indications for WCE use are increasing, but this may not be supported by sufficient evidence. Anecdotal evidence and expert opinion about the diffusion of WCEs imply that Italy is the country where its use is most widespread. A systematic assessment of this device for the Italian context has become urgent since new models of the WCE at higher prices are currently becoming available on the International market.

Objectives

To identify and summarise available evidence about the diagnostic accuracy and safety of WCE for Obscure Gastrointestinal Bleeding, Crohn's disease, familial polyposis, and Celiac disease in the small bowel, its related costs and acceptability.

Methods

We ran searches on Medline, Embase and Cochrane Library, looking for evidence of safety, diagnostic accuracy, economic impact and patient's acceptability. We identified recent evidence synthesis studies on which to base our assessment, updated and transferred results to the Italian context and collected primary data on safety, use and acceptability of WCE in Italy.

Results

We included the latest HTA report (with 10 studies fulfilling our inclusion criteria) and 17 primary studies to update the HTA report. We identified only one randomised controlled trial comparing WCE with Push Enteroscopy. The remainder of the studies were affected by poor study design

and their results could not be interpreted. We sent 116 questionnaires to centres performing the WCE requesting information on indications, diagnosis, safety and costs. We received 56 answers (48%) indicating very high variability of WCE use across the country. The main indication was a positive fecal occult blood test (45%), followed by Inflammatory Bowel Disease (19%). Angiodysplasia was the most frequent diagnosis (39.5%) followed by Inflammatory Bowel Disease (18.3%) and polyposis (7.8%). In 2006, 2457 WCE procedures were carried out, with 17 serious harm cases (1%) and 375 failed procedures (15.3%) reported. The average cost per procedure in 2006 was €1.108 in a medium throughput centre (44 WCEs per annum). We surveyed 126 patients in the 5 centres with the highest annual WCE throughput. Sixty eight percent of patients (84) found the WCE procedure tolerable compared with 33% (39 patients) for colonoscopy or oesophago-gastro-duodenoscopy patients. The equivalent data for the induction of anxiety were 25 (20%) and 60 (52%).

Conclusions

Based on evidence from one randomised controlled trial the WCE appears dominant for the diagnosis of Obscure Gastrointestinal Bleeding in the small bowel compared to Push Enteroscopy. However its dominance is based on tolerability, rather than proof of a superior diagnostic accuracy. The WCE procedure has a high failure rate, results in serious harms in 1% of cases, but is more acceptable to patients than its alternatives. Given its tiny evidence base, high cost, and potentially high failure rate, the WCE procedure should be only be reimbursed if used in a valid evidence-generating framework.

Sintesi

Problema clinico e indicazioni per l'utilizzo della VCE

Le particolari caratteristiche dell'intestino tenue, una configurazione complessa e una lunghezza che si aggira in media intorno ai 6 metri, rendono difficile la sua visualizzazione che è possibile solo in parte attraverso endoscopia tradizionale e/o esami radiologici. Quando queste procedure danno esito negativo, è necessario poter visualizzare anche le parti di intestino non raggiunte ricorrendo a tecniche alternative, come la Video Capsula Endoscopica (VCE) che permette la visualizzazione dell'intero tratto gastrointestinale. Le indicazioni per la VCE sono oggi molteplici: sangue occulto nelle feci (OGIB), ma anche diagnosi e valutazione della severità della malattia di Crohn (CD), diagnosi per la celiachia (COD) e poliposi familiare (FAP).

Per OGIB, acronimo di *Obscure Gastrointestinal Bleeding*, si intende la presenza, permanente e/o ricorrente, di sangue di origine sconosciuta nelle feci, sospetto e/o identificato a seguito di test IDA (*Iron Deficiency Anemia*), test FOBT (*Faecal Occult Blood Test*) o sanguinamento visibile anche dopo colonoscopia e gastroscopia, che abbiano dato esito negativo (Zuckerman, 1999). Si stima che l'OGIB sia dovuto nel 5% dei casi a lesioni nell'intestino tenue (American Gastroenterological Association, 2007). La causa più comune delle lesioni nel tenue è l'angiiodisplasia, all'origine del 70%-80% di tutti i casi di OGIB, seguita dal tumore (Lewis, 1994).

La malattia di Crohn (CD) è un'enterite subcronica idiopatica, che interessa soprattutto l'ileo terminale ed è caratterizzata da ulcerazioni che possono causare fistole e stenosi dell'intestino. L'incidenza in Europa meridionale è di 3.6/100,000, mentre in Italia una recente ricerca ha stimato che 1 persona ogni 100.000 è affetta da CD (Schivanada et al, 1996). La Celiachia (COD) è una malattia dovuta all'intolleranza al glutine, che provoca infiammazione cronica e atrofia della mucosa dell'intestino. Secondo la National Digestive Diseases Information Clearinghouse, in Italia circa 1 persona su 250 è celiaca. La Poliposi familiare ereditaria comporta la tendenza a sviluppare polipi intestinali precancerosi che, se non trattati in tempo, possono trasformarsi in tumori. In caso di poliposi adenomatosa la crescita dei polipi si presenta come molto lenta. L'incidenza della FAP varia da 1 ogni 7,000 a 1 ogni 22,000 individui (Genetics Home Reference).

Descrizione della tecnologia e sue alternative

L'endoscopia mediante Video Capsula Endoscopica (VCE) può essere eseguita in ambulatorio, in ricovero ordinario o in day hospital. Il paziente ingoia la capsula dopo avere digiunato durante la notte (8-12 ore), e questa riprende con una micro video camera tutto il tratto intestinale mentre lo percorre. Dopo circa 8 ore la batteria della videocamera si esaurisce e le immagini ed i dati registrati dalla capsula sono scaricati sul PC, dal registratore posto su una cintura applicata sul corpo del paziente. La procedura non è raccomandata in pazienti che hanno una storia di restringimenti intestinali e/o ostruzioni, portatori di pacemaker cardiaci o di altre apparecchiature elettroniche impiantate. Rispetto ai possibili comparatori della VCE, alcune tecniche endoscopiche che vengono annoverate tra le alternative in realtà non permettono la visualizzazione di tutto l'intestino tenue. In letteratura, gli studi individuati si basano sul confronto tra VCE e diversi altri comparatori (vedi Appendici n.2a e 2b nel testo del report). Tra esse, come confermato da una nostra indagine che ha coinvolto 56 gastroenterologi, la DBE rappresenterebbe l'unico comparatore valido.

Obiettivi

In questo quadro, a fronte di una diffusione della VCE in Italia che gli esperti giudicano ampia, il lavoro svolto ha avuto due obiettivi:

- 1) valutare le evidenze disponibili in letteratura per le diverse indicazioni di utilizzo della capsula;
- 2) quantificare l'effettiva diffusione della tecnologia in Italia, le sue modalità di rimborso ed utilizzo, i costi ad essa connessi, l'accettabilità da parte del paziente.

Metodi

Nel caso del primo obiettivo, è stata svolta una revisione sistematica della letteratura. Per il secondo obiettivo sono state effettuate un'analisi di contesto, per identificare la situazione di mercato della VCE in Italia, ed un'indagine nazionale per la raccolta di dati primari (survey), data la natura, fortemente legata al contesto d'uso, di questo tipo di informazioni e l'assenza, in letteratura, di informazioni relative a costi e diffusione della VCE in Italia.

Per la revisione sistematica, le fonti consultate sono state Medline, Embase e la Cochrane Library e, per il reperimento di report di HTA sulla VCE, è stato consultato il database dello "York Centre for Review and Dissemination". Il report più recente sulla VCE, "Endoscopie par Capsule" del Health Care Knowledge Centre (KCE) belga, pubblicato nel 2005, è stato il nostro punto di partenza: la ricerca bibliografica compiuta è stata, infatti, finalizzata all'aggiornamento, per gli anni dal 2005 al 2007, della revisione sistematica presente nel report del KCE. L'applicazione dei nostri criteri di inclusione ha portato alla identificazione di un totale di 27 studi (per i dettagli completi relativi a strategia di ricerca e criteri di inclusione vedi cap. 5.1 e Appendici 1 e 3 del report). Gli outcome considerati sono stati, oltre all'accuratezza diagnostica, anche l'accettabilità da parte del paziente, l'impatto economico e la sicurezza della VCE.

Per l'analisi di contesto e l'indagine nazionale abbiamo dovuto prima individuare tutti i centri di endoscopia e/o gastroenterologia italiani che, nell'anno 2006, hanno erogato prestazioni diagnostiche con VCE. A questo scopo è stato utilizzato il database clienti fornitori dal distributore italiano, M.G. Lorenzatto S.p.a., di cui abbiamo controllato la completezza attraverso il confronto con le fonti ministeriali (database di tutti i centri di gastroenterologia e endoscopia in Italia) e con altri database non istituzionali (database dei gastroenterologi iscritti al CICE – Club Italiano della Video Capsula). Ai centri identificati è quindi stato inviato un primo questionario finalizzato alla rilevazione di dati e informazioni sulle modalità d'utilizzo della VCE e sui suoi costi, in termini di materiali, ma anche di tempo speso da parte dei professionisti impegnati nella procedura (periodo rilevazione: dicembre 2007 - marzo 2008). Un secondo questionario rivolto ai pazienti è stato inviato a 5 centri, selezionati ex post sulla base dei volumi annui di utilizzo della capsula, allo scopo di valutare l'effettiva soddisfazione del paziente relativamente all'utilizzo della VCE, nonché alcuni costi indiretti, come il tempo speso per essere sottoposto alla procedura, in confronto ad altri esami endoscopici (periodo rilevazione: febbraio-maggio 2008).

Risultati

Revisione sistematica

È stato individuato un unico trial randomizzato (De Leusse et al.) pubblicato, tra l'altro, di recente, nel 2007, dopo 6 anni dall'entrata della VCE sul mercato italiano. Questo studio su pazienti OGIB è di buona qualità, ma oltre ad avere alcuni limiti di potenza campionaria, non confronta la VCE con il suo effettivo comparatore (la DBE), ma con la PE che non visualizza, come accennato, l'intero tratto intestinale. Gli autori, infatti, concludono consigliando l'utilizzo della capsula come metodo complementare, e non alternativo, alla DBE.

Rispetto all'accuratezza diagnostica, tutti gli studi sull'utilizzo della VCE in pazienti OGIB, indicano per la VCE una maggiore accuratezza diagnostica se confrontata con quella di PE, DBE e altre tecniche radiologiche. D'altra parte, eccetto il caso del trial di De Leusse, vi sono limiti nel disegno adottato da tutti gli altri studi, che rendono le conclusioni non attendibili. Essi presentano, infatti, un disegno di tipo sequenziale, in cui lo stesso paziente a intervalli di tempo variabile da studio a studio, non sempre riportati, viene sottoposto alla VCE e quindi al comparatore, o viceversa, fungendo sostanzialmente da "controllo" di sé stesso. Il tempo che intercorre tra una procedura e l'altra appare però molto rilevante in termini diagnostici nel caso dei pazienti OGIB, dato che il sanguinamento occulto è spesso dovuto a lesioni angiodisplastiche. Queste lesioni, possono, infatti, variare molto velocemente, con il risultato che uno stesso paziente dopo una sola settimana, può non presentarsi più con le stesse caratteristiche. Il disegno dunque, se punta a minimizzare le variabili confondenti, con il confronto dello stesso paziente in tempi diversi, rischia di ottenere il risultato opposto. Si confrontano infatti i dati clinici ottenuti su un individuo con una procedura e poi con l'altra, ma dal punto di vista delle lesioni da identificare quello stesso soggetto potrebbe essere molto diverso da sé stesso, anche dopo una sola settimana.

Gli studi individuati, inoltre, oltre a non avere un disegno appropriato, sono anche in numero non alto, una volta distinti in base sia al tipo di indicazioni, sia al tipo di comparatore. Per i pazienti OGIB abbiamo, infatti, identificato 7 studi che comparano PE e VCE, 5 DBE vs VCE, mentre 5 riguardano varie procedure di tipo radiologico vs VCE. Per il morbo di Crohn sono stati identificati 6 studi, che comparano la VCE a varie tecniche radiologiche e/o alla PE, mentre per la FAP sono stati identificati solo 3 studi. Per la celiachia nessuno tra gli studi individuati, ha soddisfatto i criteri di selezione per la revisione sistematica.

Rispetto alla sicurezza, aggregando i dati degli studi che riportano informazioni su questa dimensione, risulta che su un totale di 1236 pazienti il numero di eventi avversi è molto alto ed è pari a circa il 3%, mentre si incorre in problemi tecnici nel 7% circa dei casi. Per la parte economica nessuno degli studi selezionati contiene informazioni, mentre per la accettabilità da parte dei pazienti solo 3 studi su 27, trattano l'argomento sebbene, per lo più, in modo non metodologicamente fondato, ed evidenziando una generica preferenza del paziente per la tecnica diagnostica in analisi.

Analisi di contesto e raccolta di dati primari (survey nazionale)

L'analisi di contesto ci ha permesso di identificare l'esistenza, dal 2001 al 2006, di un solo distributore sul mercato italiano la M.G. Lorenzatto S.p.a, e di un solo produttore, la GIVEN Imaging Ltd (nel 2007 la Olympus Corporation è entrata come produttore alternativo). I dati di vendita per l'Italia, forniti da M.G. Lorenzatto S.p.a, mostrano che nel periodo dal 2001 al 2006, sono state comprate 12.451 capsule, con un aumento negli acquisti pari al 20% annuo a partire dal 2005. Dal 2001 al 2007, per la sola strumentazione d'esame (VCE e macchinari di lettura risultati esami), sono stati spesi un totale di €16.608.000. La VCE risulta rimborsata come procedura ambulatoriale, in Piemonte, Basilicata, Sardegna e Valle d'Aosta (Orecchia, 2007), ma dai dati della nostra survey risulta eseguita anche in regime di ricovero ordinario e in Day Hospital. Rispetto al numero di VCE vendute i dati aggregati a livello regionale, mostrano molta variabilità: per esempio, il numero maggiore di VCE vendute ogni 100.000 abitanti (13/100.000) è in Liguria e nelle Marche, mentre in Calabria il dato scende molto (1/100.000).

La survey per la raccolta di dati relativi all'utilizzo e ai costi della VCE ha coinvolto tutti i 116 centri individuati (Cap 6 e Appendice 7) con una percentuale di ritorno del questionario su utilizzo e costi, del 48% (56 centri su 116). I centri rispondenti sono nel 91% dei casi pubblici e, nel 2006, risultano avere effettuato un totale 2457 endoscopie con VCE. Il regime ambulatoriale viene utilizzato nel 31% dei casi, il regime di ricovero nel 43% e il day hospital nel 26%. Dal punto di vista clinico, in media, ogni paziente prima di essere sottoposto alla VCE risulta avere già eseguito almeno 2 altri esami endoscopici con esito negativo e, nel 40% dei casi la diagnosi principale dopo la VCE è di angiodisplasia (vedi Figura 6.10 nel testo del report). Dal punto di vista della sicurezza, nell'1% dei casi si sono verificati eventi quali ritenzione della capsula, occlusioni intestinali e/o subintestinali. Più alte sono le percentuali di fallimento dell'esame (15%), dovuto nel 6% dei casi a scaricamento della batteria pre termine, e nel 9% dei casi alle caratteristiche fisiche dei pazienti. Il 3% dei pazienti ha invece ripetuto l'esame per inadeguata preparazione (vedi Tabella 6.12 nel testo del report).

Dal punto di vista dei costi, una forte variabilità è stata rilevata per i prezzi di hardware e software (€ 43.108 in media), mentre il prezzo di vendita della capsula appare invece costante (in media € 642,00 IVA compresa). I dati relativi al tempo dedicato da medici, infermieri e altro personale nello svolgimento della procedura, hanno permesso una stima del budget impact in tre diversi scenari, distinti in base al numero alto (190/anno), medio (44/anno) o basso (10/anno) di esami VCE effettuati in un anno. Il numero di esami annuali risulta influire, in ragione della variabile tempo/operatore, sui costi unitari: l'impatto economico di un singolo esame nel caso di un centro con volumi bassi di utilizzo è di € 1.624,30, mentre nel caso di volumi medi scende a € 1.108,41, per ridursi ulteriormente in centri con almeno 190 VCE anno, il cui costo unitario è stimato pari a € 998,28 (Tavola 6.14 nel testo del report).

L'indagine sui pazienti ha interessato 116 individui evidenziando che non c'è risparmio di tempo da parte del paziente nel sottoporsi alla VCE piuttosto che ad altre procedure più invasive: il 70% di coloro che si sottopongono alla VCE perdono più di 7 ore della propria giornata (Figura 6.15 nel testo del report). Dal punto di vista della facilità della procedura e dei livelli di stress connessi la VCE, questa appare invece meglio tollerata di altre procedure, e ciò anche dal punto di vista del dolore, che non è assolutamente percepito dall'83% dei rispondenti nel caso della VCE (Figura 6.18 nel testo del report).

Discussione

La valutazione relativa alla qualità degli studi è negativa e questo determina una qualche incertezza rispetto alla affidabilità delle loro conclusioni su accuratezza diagnostica e sicurezza. Esiste al momento un solo trial randomizzato, pubblicato nel 2007 (De Leusse et al), e riguarda i pazienti con OGIB e la comparazione tra performance della VCE e della PE, che però non raggiunge tutto il tratto dell'intestino tenue. Gli altri studi sono distinguibili in studi che coinvolgono pazienti OGIB, FAP o Crohn, ed ogni gruppo di studi è ulteriormente diviso in base al "comparatore". In ogni gruppo e sottogruppo è presente lo stesso disegno di studio "sequenziale" fonte di forte bias nei risultati finali, dato che le lesioni che causano sanguinamento sono, in altissima percentuale, di tipo angiodisplasico e, dunque, con una alta variabilità morfologica in tempi molto brevi (dato presente in letteratura e confermato dalla nostra indagine nazionale). Questo rende il disegno utilizzato inaffidabile, ed i risultati ottenuti su questa base di evidenza, potenzialmente non affidabili. L'analisi di contesto e la survey hanno evidenziato un'alta diffusione della procedura, ed un uso che non pare essere basato su criteri di efficienza ed economie di scala, se si considerano i risultati della budget analysis effettuata sui tre scenari. Alla raccolta di dati di costo non è stato possibile fare seguire una valutazione economica di costo efficacia per la mancanza di un chiaro comparatore, di evidenze solide e di stime di prevalenza attendibili per le varie indicazioni.

Raccomandazione

Sarebbe importante che nel futuro il rimborso della VCE fosse legato alla produzione di evidenze fondate su trial randomizzati ben costruiti, il cui obiettivo sia testare le performance della tecnologia per le sue diverse indicazioni, sotto la supervisione di una commissione scientifica ed etica. Questo tipo di approccio, che a livello internazionale è già in uso (ed è chiamato Coverage with Evidence Development), dovrebbe essere adottato per tutte le tecnologie emergenti prima che queste si diffondano, in modo non governato e spesso senza sufficienti evidenze, in Italia. In particolare, rispetto al contesto italiano alcune nuove indicazioni proposte, come per la diagnosi di celiachia, appaiono inutili in quanto per tale diagnosi è comunque necessaria una biopsia che affermi l'effettiva presenza della patologia.

Bibliografia

American Gastroenterological Association (AGA) Institute Technical Review on Obscure Gastrointestinal Bleeding. *Gastroenterology* 2007;133:1697-1717.

De Leusse A, Vahedi K, Edery J, et al. Capsule endoscopy or push enteroscopy for first-line exploration of obscure gastrointestinal bleeding? *eng. Gastroenterology*. 2007 Mar; 132(3):855-62; quiz 1164-5; ISSN: 0016-5085

Genetics Home Reference (<http://ghr.nlm.nih.gov>)

Lewis BS, Small Intestinal Bleed. *Gastroenterology Clinics of North America*, 1994;23(1):67-91.

Orecchia G, Oral communication at 2° CONGRESSO NAZIONALE sulla Videoendoscopia - Second Italian Congress on WCE - 28-30 June 2007, Feltre (Italy).

Schivanada S, Lennard Jones J, Logan R et al. Incidence of inflammatory bowel disease across Europe: is there a difference between north and south? Results of the European Collaborative Study on Inflammatory Bowel Disease (EC IBD) *Gut* 1996;39:690-697.

Zuckerman GR, Prakash C, Askin MP, Lewis BS. AGA technical review on the evaluation and management of occult and obscure gastrointestinal bleeding. *Gastroenterology* 1999;118:201-221.

1. Background

1.1 Clinical problem and indications

The characteristics of the human small bowel, a complex looped configuration/structure and a huge length (around 6 metres), make its examination difficult. For the diagnosis of small bowel diseases endoscopy can be used to determine the causes of obscure gastro intestinal bleeding (OGIB), Crohns disease (CD) and coeliac disease (COD) (see relative sections for definitions).

Visualisation of the small bowel is possible using different radiological and traditional endoscopic procedures, the latter such as Push Enteroscopy (PE) does not always allow the examination of the entire organ (see section 2). When a source of bleeding cannot be detected with the above procedures, and this occurs in 5-10% of OGIB cases (Myers¹, and results of the Italian survey held at Torgiano's Gastroenterologist meeting in 2007, see Appendix 1), the lesion causing the bleeding could be located in the part of the small bowel not yet visualised.

Wireless Capsule Endoscopy (WCE), approved in 2001 by the Food and Drug Administration in the United States, allows visualisation of the entire small bowel. The capsule is being used for OGIB; for the diagnosis of CD, and for the assessment of its extent and severity; in the diagnosis of small bowel tumours; in the detection of small bowel injury associated with the use of non steroidal anti-inflammatory drugs; in the delineation of type of abdominal pain and in the assessment of COD.

1.1.2. Obscure gastrointestinal bleeding (OGIB)

OGIB is defined as bleeding of unknown origin that persist or recurs, as in recurrent or persistent Iron Deficiency Anemia (IDA), positive Faecal Occult Blood Test (FOBT), or visible bleeding after a negative colonoscopy and/or upper endoscopy result. Obscure bleeding can thus have two clinical forms: obscure-occult, as manifested by recurrent IDA and/or recurrent positive FOBT results, and obscure-overt, with recurrent passage of visible blood (Zuckerman²).

OGIB could be due to lesions that are overlooked in the esophagus, stomach, and colon during initial workup or lesions in the small intestine that are difficult to visualise with conventional endoscopy and radiologic imaging. Overall lesions in the small intestine account for approximately 5% of causes of OGIB (American Gastroenterological Association, 2007³). Medical imaging of the small intestine has been a very difficult due to limited visualisation of the lumen.

The principal causes of small bowel bleeding are:

- Angiodysplasia;
- Vascular lesions;
- Adenocarcinoma;
- Lymphoma;
- Carcinoid Tumour;

- Ulcers;
- Crohn's disease;
- Polyps.

The most common cause of small intestine bleeding is Angiodysplasias: 70%-80% of all OGIB are due to these kind of lesions, while tumours are in fact the second most common cause (Lewis⁴).

1.1.3 Crohn Disease (CD)

CD is a subacute chronic enteritis, of unknown cause, involving the terminal ileum and less frequently other parts of the gastrointestinal tract; characterised by patchy deep ulcers that may cause fistulas, and narrowing and thickening of the bowel by fibrosis and lymphocytic infiltration, with noncaseating tuberculoid granulomas that may also be found in regional lymph nodes. Symptoms include fever, diarrhea, cramping abdominal pain, and weight loss (Stedman's Medical Dictionary⁵).

Incidence rates for CD were generally lower and were similar for men and women, with rates for both sexes declining with increasing age. The European Collaborative Study on Inflammatory Bowel Disease (EC-IBD) indicated that in Northern Europe the incidence rates of CD patients for 100,000 population aged 15 years or over 6.3/100,000, while in Southern Europe the number of CD patients was 3.6/100,000. Data from the 4 Italian centres involved in the research showed that 1/100,000 had CD (Schivanada et al.⁶).

1.1.4 Coeliac disease (COD)

COD occurs in both children and adults and is characterised by sensitivity to gluten, with chronic inflammation and atrophy of the mucosa of the upper small intestine; symptoms include diarrhoea, malabsorption, steatorrhea, nutritional and vitamin deficiencies, and failure to thrive, or short stature (Stedman's Medical Dictionary⁵). This digestive disease damages the small intestine and interferes with the absorption of nutrients.

Data on the prevalence of COD is spotty and more research is needed to learn the true prevalence, as in Italy, a National register on inflammatory bowel diseases (to which COD belongs) is not yet available. According to the National Digestive Diseases Information Clearinghouse⁷, in Italy about 1 in 250 people have COD. However, it could be underdiagnosed due to symptoms which are common to other pathologies, unfamiliarity with the disease and lack of specific expertise.

1.1.5 Familial Adenomatous Polyposis (FAP)

FAP is an inherited disorder characterised by cancer of the large intestine (colon) and rectum. People with the classic type of familial adenomatous polyposis begin to develop multiple noncancerous (benign) growths (polyps) in the colon, which may become malignant (cancerous). Some


people have a variant of the disorder, called attenuated familial adenomatous polyposis, in which polyp growth is delayed. In both classic familial adenomatous polyposis and its attenuated variant, benign and malignant tumours are sometimes found in other places in the body, including the duodenum (a section of the small intestine), stomach, bones, skin and other tissues. A milder type of familial adenomatous polyposis, called autosomal recessive familial adenomatous polyposis, has also been identified. People with the autosomal recessive type of this disorder have fewer polyps than those with the classic type. The colonoscopy confirms disease diagnosis. The reported incidence of familial adenomatous polyposis varies from 1 in 7,000 to 1 in 22,000 individuals (Genetics Home Reference⁸).

2. Technology, procedure and alternatives

2.1. Technology

Wireless Capsule Endoscopy (WCE) (figure 2.1) is a recent technology primarily designed to provide imaging of the small intestine, an anatomic site that has proved particularly difficult to visualise. Devised by an Israeli engineer, Gavriel Iddan in 1981: 15 years later, the capsule was tested on animals, whilst the first trials on adult humans began in 2001 (see Appendix 2a).

Figure 2.1 Video Capsule Endoscopy



- 1) optical cupola;
- 2) lock for the lens;
- 3) lens;
- 4) lighting system to LED (Light Emitted Diode);
- 5) CMOS imager (Complementary Metal Oxide Semiconductor);
- 6) Batteries;
- 7) Transmitter ASIC (Application Specific Integrated Circuit);
- 8) Antenna.

2.2 Procedure

The procedure can be performed in an ambulatory or hospital setting on an outpatient basis. The patient swallows a small capsule after fasting overnight (8-12 hours). The capsule contains a micro-imaging video technology, a light source and a wireless circuit for the acquisition and transmission of images. The system also includes a software that provides localisation of the device during its passage through the intestine. While moving through the gastrointestinal tract, images are captured at the rate of two per second. These images are transmitted to a data recorder worn on a belt outside the patient's body and approximately eight hours after ingestion, the patient returns to the clinic where images and data are downloaded. The capsule is passed in the patient's stools within 24-48 hours. It is not reusable.

The WCE procedure involves a high degree of expertise and providers of the service should

be specialists who have undertaken a specific training program. The procedure is not recommended in patients suspected of, or with a history of, intestinal stricture or obstruction, or who carry a cardiac pacemaker or other implanted electronic devices. The main indication for WCE use is the diagnosis of the site of Obscure Gastrointestinal Bleeding (OGIB) in adults. OGIB is defined as bleeding of an unknown origin that persists or recurs after a negative initial endoscopy (colonoscopy and/or upper gastrointestinal endoscopy). The capsule is being used for the diagnosis, assessment of its extent and severity of CD, in the diagnosis of small bowel tumours, in the detection of small bowel injury associated with the use of non steroidal anti-inflammatory drugs, delineation of the type of abdominal pain and in the assessment of COD.

2.3 The alternatives

The following are the main comparators divided by indication (table2.1). A brief description of each technology is provided in the text (for a more thorough description see Appendix 2b).

Table 2.1 Principal comparator of WCE

	Comparator
Endoscopic procedures	Double Balloon Enteroscopy (DBE), Intraoperative Enteroscopy (IE), Push Enteroscopy (PE).
Imaging procedures	Angiography, Computer Tomography (CT), Enteroclysis, Magnetic Resonance Imaging (MRI), Small Bowel Series (SBS) - Small Bowel follow through (SBTS)

Double-balloon enteroscopy (DBE)

This is a recent endoscopic technique (2001) that allows the real-time visualisation of the entire gastrointestinal tract. The technique involves the use of a special enteroscope and an overtube (a tube that fits over the endoscope). Silicone inflatable balloons are embedded one on the enteroscope and one on the overtube. The enteroscope is inserted through the mouth and passed in conventional fashion into the small bowel. DBE is also applied through the anal route.

Enteroclysis

Enteroclysis is a minimally invasive radiographic procedure of the small intestine, which requires the introduction of a catheter into the small intestine followed by the injection of barium and methylcellulose. The catheter is passed from the nose or mouth through the stomach and into part of the small bowel and injects the barium which coats the intestine and the methylcellulose which distends the lumen allowing real-time fluoroscopic visualisation of the entire small bowel.

Intraoperative Enteroscopy (IE)

IE (per-orally, trans-nasally, per-rectum, or through single or multiple intestinal incisions) is usually applied in cases of bleeding that has not been localised in spite of extensive diagnostic evaluation and in which the risks of continued bleeding are judged to outweigh the risks of laparotomy.

Standard push enteroscopy (PE)

This standard procedure allows visualisation of the bowel. It requires the oral insertion of a long endoscope and allows examination of the distal duodenum and proximal jejunum. Due to the anatomical features of gastrointestinal tract, this kind of device cannot reach all the parts of the bowel and therefore some "dark areas" cannot be observed.

Angiography

Angiography is the x-ray study of the blood vessels. An angiogram uses a radio opaque medium to highlight the blood vessels in a fluoroscopy suite. Angiography requires the injection of a contrast medium that makes the blood vessels visible to x-rays. The patient's vascular system is displayed on a monitor in real-time. For examination of the small bowel, the procedure is called mesenteric angiography and involves x-ray exploration of the celiac and mesenteric arteries, the arterial branches that supply blood to the abdomen and digestive system.

Computer Tomography (CT)

Computer Tomography scanning (CT or CAT, Computer Assisted Tomography) is a non-invasive, painless imaging technique. CT uses special x-ray equipment to produce multiple images of the inside of the body and a computer joins them together in cross-sectional views of the area being studied. CT scans of internal organs, bone, soft tissue and blood vessels provide greater clarity than conventional x-ray examinations.

Magnetic Resonance Imaging (MRI)

Unlike conventional x-ray examinations and CT scans, MRI does not depend on radiation. Instead, radio waves are directed at hydrogen atoms, in a strong magnetic field.

Small Bowel Series (SBS) or Small Bowel follow-Through (SBTS)

STS or SBTS is an x-ray examination of the small intestine. This procedure requires that the patient swallows a radio-opaque contrast medium, usually barium sulphate, and then is placed in various positions on the x-ray table while the radiologist uses a fluoroscope connected to a monitor to acquire x-ray images usually every 20 to 30 minutes (this exam often takes 2 hours or more to complete).

3. The marketing status of WCE and current reimbursement arrangements

Two main companies are competing in the worldwide market:

- Given Imaging Ltd, with its PillCam;
- Olympus Corporation, with its EndoCapsule

The latter in 2007 developed a wireless capsule endoscope (EndoCapsule EC type 1) using a different image sensor with electronic enhancement of image quality. In Italy Olympus started-commercialisation of the Endo Capsule in 2007.

The capsule by Given Imaging Ltd has been on the world market since 2001 (M2A capsule), receiving approval from the U.S. Food and Drug Administration (FDA) in August 2001 for use in the United States. As regards the European market, Given Imaging Ltd received approval (CE Mark) by the Regulatory Authorities of the European Union in May 2001. The European directives on biomedical devices have been incorporated into the Italian legislative system. Its main requirements are related mainly to safety and technical performance. In Italy, market introduction of biomedical technologies, is not subordinated to further regulation by any national or regional bodies. However the 2003 financial law (L. 266/2002) foresaw the establishment of a national data-base of all medical devices available in the Italian market ("Repertorio generale dei dispositivi medici commercializzati"). Therefore the use of biomedical devices such as the WCE is usually started and developed in a bottom up fashion. The WCE capsule by Given Imaging Ltd has been sold in Italy since 2001, and its use is widespread. Data from Given Imaging Ltd, shows that over 3,500 centres from more than 65 countries use WCE (Orecchia G⁹). Data provided by M.G.Lorenzatto S.p.a., exclusive distributor of the Given Imaging Ltd WCE in Italy, show that in the period 2001 - 2006, 12.451 capsules were purchased, with a yearly increase of 20% from 2005 onwards. WCE is reimbursed as an outpatient procedure in 4 Regions: Piemonte, Basilicata, Sardegna and Valle d'Aosta (Orecchia⁹).

4. Report's objectives: policy question and research questions

According to expert opinion, the WCE has been widely distributed and used in Italy since its introduction in 2001. However no data on its use has ever been collected.

Our policy question was: what is the evidence of diagnostic accuracy underpinning the use of WCE and what are its uses and costs in Italy?

Our research question was: what is the scientific evidence of WCE's diagnostic accuracy compared to other commonly used techniques and what is the evidence of its safety, patients' acceptability and economic impact in Italy?

The report's objectives are:

- To retrieve, assess and appraise the available evidence about diagnostic accuracy, safety, cost effectiveness, and patient's acceptability of WCE for OGIB, Crohn's Disease, Familiar Polyposis and Celiac Disease.
- To produce context-specific data and information by collecting primary data and information from all the Italian providers of WCE, from patients, physicians and from the Italian Regional health services.

5. Assessing the available evidence

5.1 Methods

We performed a systematic review of the evidence from primary and secondary studies to identify:

- a) Health Technology Assessments reports and systematic reviews;
- b) Primary studies to update the reports identified in step a);
- c) Primary economic evaluations and patients acceptability studies.

5.1.1 Health Technology Assessments reports and systematic reviews

We conducted searches on the database of the “York Centre for Review and Dissemination” (CRD). We selected reports published from January 2001 to July 2007, we chose the online versions in English, and assessed them on the base of quality criteria (see INAHTA and EUnetHTA’s checklist for transferability of HTA reports: <http://www.inahta.org/HTA/>). We identified three reports (from Australia¹⁰, Britain¹¹ and Belgium¹²) for an in-depth analysis of data transferability. No report contained an economic evaluation or a survey of patient acceptability.

5.1.2 Primary studies

We selected the most recent reports to update the Belgian WCE diagnostic efficacy systematic review¹². As this had been published in early 2006, we overlapped the searches to June 2005 to minimise the risk of missing studies. On the basis of our own inclusion criteria we selected studies dated before 2005 included in the Belgian report. Searches were conducted on the following databases:

- Medline
- Embase
- Cochrane Library (CL)

Complete details on the strategy criteria and search terms are presented in Appendix 3.

5.1.3 Inclusion criteria

We included comparative studies (excluding editorials, letters, news articles, clinical guidelines, conference papers, interviews, surveys, opinion pieces, anonymous articles and non systematic reviews) on patients with OGIB, Crohn’s disease, COD and Familiar Polyposis reporting an appropriate outcomes (diagnostic performance, effect on clinical management and/or health outcome, tolerability, efficiency and direct and indirect costs) comparing WCE to different diagnostic

techniques (DBE, Enteroclysis, IE, PE, Angiography, CT, MRI, SBTS). Studies with fewer than 10 participants and those not carried out on humans were excluded.

5.2 Assessing the available evidence: diagnostic accuracy

WCE versus PE diagnostic accuracy in patients with OGIB

Six studies compared the performance of WCE with that of PE in OGIB: Mylonaki et al.¹³, Mata et al.¹⁴, Adler DG. et al.¹⁵, Saurin et al.¹⁶, Neu et al.¹⁷, De Leusse et al.¹⁸. PE does not allow the visualisation of the entire small bowel, therefore it does not seem to be a suitable or fair comparator, nevertheless most of the included studies compared the diagnostic accuracy of PE versus WCE. All patients included in the study had OGIB, and had already undergone upper and lower endoscopic procedures. Among selected studies there was only one randomised trial (De Leusse et al.¹⁸) published in 2007 (see below), while the other studies show varied and numerous design and reporting limitations, as described below.

32



Randomised controlled trials

De Leusse et al.¹⁸ is the only randomised trial in our evidence base. Minor shortcomings are related to the generalisability of results due to the low number of patients enrolled (78) and to the clinical characteristics of patients, which seem to be very specific to the French context (for example very high haemoglobin levels at baseline). Reasons for patients lost to follow up are not reported. This trial shows that WCE has a higher diagnostic yield than PE in patients with OGIB. The two strategies tested (WCE or PE first, followed if negative, by the alternative) were not (DY, 95% CI) statistically different in terms of diagnostic yields, clinical remission rate, therapeutic impact, need of alternative exploration during first year. However, the authors conclude that using the WCE first would be the best option, since it is simpler and better tolerated. The diagnostic yield of WCE vs PE for definite sources of bleeding were 17 of 40 patients (43%; 95% CI: 29-59) and 4 of 38 patients (11%; 95% CI: 4-25), respectively for small bowel lesions (P=.02), 3 of 40 patients (8%; 95% CI: 3-20) and 4 of 38 patients (11%; 95% CI: 4-25) for gastric lesions and 0 of 40 patients (0%; 95% CI: 0-7) and 1 of 38 patients (3%; 95% CI: 1-14) for colonic lesions. Performance of WCE for all lesions were: sensitivity 79% (60-86); specificity 87% (67-90); PPV 88% (75-90) and NPV 77% (50-85). For small bowel lesions: sensitivity 100% (61-100); specificity 90% (77-92); PPV 85%(69-88) and NPV 100%(71-100). Performance of PE for all lesions was: sensitivity 41% (30-53); specificity 100% (91-100); PPV 100% (89-100) and NPV 56% (35-72). For small bowel lesions: sensitivity 33% (21-43); specificity 100 (93-100); PPV 100% (83-100) and NPV 62% (41-75).

Non randomised studies

In Mylonaki et al.¹³, Mata et al.¹⁴, Adler et al.¹⁵, Neu et al.¹⁷ all patients enrolled served as their own controls, with PE performed within 3-14 days after WCE (in two studies, Adler et al.¹⁵, Neu et al.¹⁷, the time range is not reported).

Saurin et al.¹⁶ is a "follow up study", involving 58 patients already enrolled in a previous prospective study (comparing WCE with PE). Patients were contacted after a year. The authors concluded that WCE is a sensitive examination for the detection of small-bowel lesions in patients with

OGIB, with a specificity lower than that of PE and a high negative predictive value, making it a useful first line technique before PE (sensitivity 95% CI) of WCE 0,92 (0.82-1.00) and PE 0.69 (0.53-0.87) - specificity (95% CI) of WCE 0.48 (0.32-0.68) and PE 0.80 (0.54-0.94). PPV of WCE 0.62, and of PE 0.75 - NPV of WCE 0.87 and NPV 0.74).

According to the studies by Mylonaki et. al.¹³, Mata et al.¹⁴, Neu et al.¹⁷ Adler et al.¹⁵, WCE diagnostic accuracy would seem superior to that of PE. Mylonaki et al.¹³ is based on 52 consecutive patients and report that WCE can provide small intestinal imaging comparable with PE, and can diagnose intestinal bleeding sources at sites beyond the reach of PE: WCEs diagnostic yield in the small bowel was 68% and in total was 76% compared with PE. PE identified a bleeding source in the same location in 32% of patients, while its total diagnostic yield was 38%.

The Mata et al.¹⁴ study is based on 42 consecutive patients undergoing WCE first and PE after 1 week. The authors report that WCE increases the diagnostic yield in patients with OGIB and allows modification of the therapy strategy in a remarkable proportion of patients: WCE diagnostic yield: 31/42 (74%) and PE diagnostic yield: 8/42 (19%). Most of the findings detected by WCE were located in the distal jejunum and ileum, probably out of reach of the enteroscope. WCE led to a change in treatment strategy in 7/31 patients (22%). The authors suggest that WCE should be used before PE and after a negative upper and lower conventional endoscopy.

Neu et al.¹⁷ is a multicenter prospective study carried out in five German centres and compare the diagnostic yield of WCE to a group of other technologies (OT). Time range and sequence of technologies is not reported, since it varies from centre to centre. The authors underline that the diagnostic yield of WCE vs PE is higher above all in the parts of small bowel not reachable by PE and that WCE tends to visualise and identify many small lesions which were too small to be the cause of bleeding. The report is confusing, with aggregate findings, although tables showing results for each single technology are presented, but not discussed. WCE detected 42% of lesions with low probability of being a bleeding source, and 58% of lesions with a high probability. PE detected 27% of minor lesions and 73% of major lesions.

Adler et al.¹⁵ is a study based on 20 consecutive patients undergoing WCE first and then PE (time range not reported). According to the authors WCE affects long term management of patients with clearly seen lesions, but does not affect the management of patients with lesions which are not necessary the source of bleeding). Definitive sources of bleeding in the small bowel were identified by WCE in 6 out of 20 patients (30%) and only two of them were found to have small bowel angioectasias at PE. Five of them underwent targeted endoscopic or surgical therapy based on WCE and PE findings.

WCE and DBE diagnostic accuracy in patients with OGIB

Randomised controlled trials

None were identified

Non randomised studies

Five studies involving patients with OGIB compared WCE versus DBE: Matsumoto et al.¹⁹, Hadithi et al.²⁰, Nakamura et al.²¹, Gay et al.²², Xiao-bo et al.²³. DBE is probably a fairer comparator than PE, as the use of two balloons should allow the exploration of the entire small bowel, although this can not be taken for granted due to each patient's individual variability. Three studies are based on very small numbers. In addition the same patient undergoes both procedures at different times, introducing a strong time bias affecting results. Time between the two interventions is always reported and ranges from 2 to 14 days. In only one study patients undergo DBE first (Matsumoto et al.¹⁹) this may be due to the fact that authors aim was to evaluate how much farther WCE travels behind the last part of intestine reached by DBE. All the studies, except Matsumoto's, seem to reach similar conclusions, indicating WCE as the first option in OGIB cases and DBE as last option given its therapeutic ability and histopathologic capacity.

Matsumoto et al.¹⁹ enrolled 22 patients to compare WCE and DBE diagnostic accuracy. The value for diagnosing OGIB is similar in the two procedures for the area reached by DBE. According to the authors DBE appears superior to WCE in the diagnosis of small-intestinal polyps. DBE identified positive findings in 12 patients (54.5%), while WCE identified positive findings in the area explored by DBE in 8 patients (36.4%), and in the unexplored area in 11 patients (50%). Five of them underwent a new DBE. In 2 cases it did not discern the small intestinal pathology suggested by the WCE.

The Hadithi et al.²⁰ study is based on 35 consecutive patients and the authors report that the diagnostic detection rate of WCE is 80% (28/35) and that of DBE 60% (21/35). The authors report that WCE has a higher detection rates than DBE, but also has limits lacking any related therapeutic potential (unlike DBE) and tends to overestimate the density of lesions by also visualising trivial ones (high number of false positive). According to the authors WCE and DBE are complementary: WCE is a good candidate to be the first diagnostic step in approaching selected patients with OGIB, DBE may verify WCE findings and provide therapeutic options. The study by Nakamura et al.²¹ includes 32 consecutive patients. The authors evaluated the access rate to the entire small intestine of the two procedures. WCE succeeded in accessing the entire intestine in 90.6% of patients (29/32), while DBE in just 62% (10/16 $p < 0.05$). The diagnostic rate of WCE is 59.4% (19/32) and for DBE is 42.9% (12/28 $p = 0.30$). According to the authors in many suspected small bowel bleeding cases WCE should be selected for the initial diagnosis and DBE for treatment or histopathologic diagnosis after detection of the bleeding site by WCE. However if it is suspected that the bleeding site is located in the distal ileum, DBE may be chosen initially since WCE is unable to reach this due to food residues or battery failure.

The study by Gay et al.²² involves a group of 160 consecutive patients. Half of them underwent just WCE, while 42 had DBE, 87 cases were confirmed as OGIB. The objective of this study was not to compare the diagnostic accuracy of WCE vs that of DBE. The authors assume the diagnostic dominance of WCE on the basis of the evidence provided by previous studies (Saurin et al.¹⁶, Ell et al.²⁴) and they conclude that WCE should be used as a filter for DBE.

The study by Xiao-bo et al.²³ published in 2007 is large: 218 participants with OGIB, diarrhoea or abdominal pain who had undergone other diagnostic procedures. They were "categorised" into 2 groups undergoing first either WCE or DBE. Patients with negative or equivocal findings on WCE underwent DBE and vice versa. The time range between DBE and WCE was 12.9 days (2-50

days.) As a whole the “categorisation” is not well explained and it is not possible to say if any randomisation occurred. The authors report that the detection rate of small bowel diseases with DBE is relatively lower than that with WCE. The two procedures are complementary but the authors conclude that WCE is a better initial diagnostic approach for suspected small bowel diseases especially for OGIB. With regard to the relatively high non-diagnostic (i.e. unknown pathology causing bleeding) rate (28%) of small bowel diseases and inability to provide diagnostic sampling, DBE still appears to be a viable instrument to complete and/or confirm the negative and non-diagnosis made by WCE

WCE versus other techniques in patients with OGIB

Randomised controlled trials

None were identified

Non randomised studies

Five studies compared WCE with different diagnostic techniques. One of the studies compared WCE with Intraoperative Enteroscopy (IE), while the other comparisons are all imaging technologies, such as Small bowel barium follow through (SBFT), Computed Tomography (CT), Magnetic Resonance Enteroclysis (MRE), Standard Angiography (ANGIO).

The study by Costamagna et al.²⁵, compares the clinical outcomes of small bowel radiographs (SBFT) with WCE in a prospective study, where 22 consecutive patients with suspected small bowel disease were enrolled and underwent both barium follow-through and the WCE at different times was carried out 4 days before WCE. The endoscopist was blinded to the SBFT results. The authors report that WCE was superior to small bowel radiograph for the evaluation of small bowel disease. For OGIB, the diagnostic potential of barium follow-through was much worse compared with that of WCE (5% vs 31%, $P < 0.05$). Findings were classified as diagnostic, suspicious or failed (no source of bleeding identified). Barium follow-through was normal in 17 patients and showed ileal nodularity in 3 patients. WCE was normal in 3 patients and showed positive findings in the remaining 17 patients. The barium study was considered diagnostic in 4 (20%) patients, suspicious in 0 and failed in 15 (73%). The capsule endoscopy was considered diagnostic in 9 (45%) patients, suspicious in 8 (40%) patients and failed in 3 (15%) patients.

The study by Hara et al.²⁶ compared WCE findings with barium studies or computed tomography (CT) in 22 patients. This is a retrospective study where 36 patients underwent SBFT, 4 enteroclysis, and 19 CT of abdomen and pelvis. Imaging results were retrospectively reviewed and compared to WCE, standard endoscopy, and surgical results. Findings of any examinations between WCE and imaging that were discrepant were retrospectively reviewed by a radiologist not blinded to WCE results. The proportion of positive WCE findings was compared with the proportion of positive findings from barium studies and CT in the same patients. In patients without a small-bowel stricture in the barium study, more small-bowel diseases were found with WCE when findings were retrospectively compared with barium examination and CT findings. Barium examina-

tion findings were positive in one (3%) of 40 patients; WCE findings were positive in 22 (55%) ($P < 0.001$). CT demonstrated small-bowel findings in four (21%) of 19 patients, but WCE demonstrated findings in 12 (63%) of 19 patients ($P = 0.02$). The most common WCE findings (11 cases of angioectasia), were not detected at any imaging study. More ulcers ($n = 8$) were detected with WCE than with barium study (one of eight) and CT (three of six). At WCE, three of five surgically confirmed masses (carcinoid, intussusceptions, lymphangioma) were identified, but two jejunal tumours were not detected in a patient with poor bowel preparation. Barium studies detected no masses (zero of five), CT detected one of four masses.

The study by Golder et al.²⁷ assessed the diagnostic yield of WCE compared with that of MR enteroclysis in the detection of small bowel pathologies. This is a prospective study involving 36 consecutive patients, of whom 14 had OGIB and it is focused mainly on CD patients. Although in general, the diagnostic yield of WCE was different on each part of the small bowel the authors conclude that MRE had no diagnostic benefit in patients with OGIB versus WCE, which is clearly superior to MRE.

The study by Saperas et al.²⁸ compared the diagnostic yield of WCE with that of Computed Tomography (CT) or Standard Angiography (ANGIO) in patients with OGIB. Twenty eight patients underwent WCE within 7 days of imaging. A source of bleeding was detected by WCE in 72% patients (18/25), by CTA in 24% of patients (6/25), by ANGIO in 56% patients (14/25). In this study WCE detected more lesions than CTA or ANGIO in patients with OGIB.

Hartman et al.²⁹, compared the diagnostic yield of WCE with that of Intraoperative Enteroscopy (IE), which could be considered the only proper comparator. The study involved 46 patients that underwent IE 6 days after having WCE. The authors report that the diagnostic yield of WCE is different according to the kind of OGIB. In overt ongoing bleeding a diagnosis was made in 100% of patients (11/11), in overt previous bleeding 67% (16/24) of patients had a lesion detected by WCE and in cases of occult bleeding, WCE found a lesion in the same percentage of patients 67% (8/12). IE performed similarly in overt ongoing bleeding (100%, 11/11), better than WCE in overt previous bleeding 70.8% (17/24) and in occult bleeding 50.0% (6/12). The authors report that WCE performs better in occult bleeding cases.

WCE versus other techniques in patients with CD

Randomised controlled trials

None were identified

Non randomised studies

Seven studies were carried out in patients with CD: Albert et al.³⁰, Buchman et al.³¹, Eliakim et al.³², Ho Chong et al.³³, Golder et al.²⁷, Gay et al.²², Voderholzer et al.³⁴. In those studies WCE is compared to different imaging diagnostic procedures: SBFT (2 studies), CT (1), MRI (2). Gay et al.²² (14 out of 160 enrolled patients had CD) compared WCE to both endoscopic and imaging procedures (PE and Enteroclysis). The first group of studies assessing WCE compared with visual

techniques, appear to show a similar sensitivity for WCE (except Eliakim et al.³²), but there is a strong attrition bias in the studies with almost 10-15% of patients lost to follow up or for whom WCE is contraindicated due to strictures in the small bowel which were detected previously with the comparator (Appendix 4).

Albert et al.³⁰ report a prospective blinded study comparing WCE with MRI on 52 consecutive patients with suspected recurrence of CD. They were enrolled on the basis of abdominal pain, diarrhoea, anaemia, and/or arthralgias. Results showed that WCE and MRI are complementary techniques having very similar sensitivity in both suspected and diagnosed CD. Buchman et al.³¹ involved 30 patients with clinical suspected CD recurrence and compared WCE to SBFT. The authors report that WCE and SBFT have similar sensitivity and accuracy for the diagnosis of CD. The study by Eliakim et al.³² involved 35 consecutive patients with suspected CD and the authors report that WCE is a more sensitive diagnostic tool than SBFT and entero-CT in the target population. The study by Ho Chong³³ compares WCE with PE and Enteroclysis. The authors report that WCE has a higher yield than the other two procedures in patient with suspected CD. The study by Gay et al.²² involves a group of 160 consecutive patients. Fourteen of them had CD. The objective of this study was not to compare the WCE diagnostic accuracy versus that of the DBE. The superiority of WCE is assumed by the authors also for CD on the basis of the evidence provided by previous studies. The authors report that WCE should be used as a filter for DBE. Voderholzer et al's³⁴ prospective study involved 56 patients (of whom 14 were excluded due to strictures detected with CT). The study compared WCE to CT enteroclysis and the authors report that WCE improves the diagnosis of small bowel CD and changes patient's therapeutic plan.

WCE versus other techniques in patients with FAP

Randomised controlled trials

None were identified

Non randomised studies

Three prospective studies assess the performance of WCE in FAP: Caspari et al.³⁵, Schulman et al.³⁶ and Wong et al.³⁷. Comparators were PE (2 studies) and MRI (1). The total numbers of patients involved in the three studies were 92. The authors report that WCE tends to have problems in detecting large polyps, while it can overestimate the number of polyps, having a high sensitivity (Appendix 4).

Systematic reviews and meta analyses

In Marmo et al.³⁸ the studies were examined with respect to the following criteria: study design; inclusion and exclusion criteria; patient characteristics; technical detail of CE and other diagnostic procedures; definition of study outcomes and their monitoring methods. Information on objective quality-related characteristics was also collected and the quality of the studies included was assessed using 17 of the 22 items of the CONSORT statement (Altman et al.³⁹). Results from the trial reports were reproduced where possible. The systematic review was performed according to the QUOROM statement (Mother et al.⁴⁰).

Marmo et al.³⁸ report that WCE proved significantly superior to PE and small bowel radiology in the diagnosis of ileal disease. Patients evaluated were 526 (289 assigned to WCE for OGIB, 237 assigned for known or suspected CD). The rate difference between WCE and alternative techniques for small bowel disease was: 41% (95% CI 35.6-45.9); 37% (95% CI 29.6-44.1) for OGIB; and 45% (95% CI 30.9-58) for CD. Failure to visualise the caecum occurred in 13%, significantly more often in occult bleeders (17%) than in patients with CD (8%) ($P < 0.006$).

In Triester et al.⁴¹ the studies were examined for prospective trials comparing WCE to one or more alternate modalities for evaluation of the small intestine in patients with suspected or established CD using the MEDLINE, EMBASE and Cochrane Central Trials databases.

The review by Triester et al.⁴¹, included only studies assessing WCE for the diagnosis of CD. The authors report that WCE is better than all other considered techniques for the diagnosis of non stricturing small bowel CD, with a number needed to test NNT of 3 to yield one additional diagnosis of CD over small bowel barium radiography and a NNT of 7 over colonoscopy with ileoscopy. Nine studies (N=250) reported the yield for WCE versus BR equal to 40%. Four studies (N=114) report that the yield for WCE versus colonoscopy with ileoscopy was 61% e 46%. Three studies (n=93) assessing WCE vs CT enterography showed 69% and 30% diagnosed patients respectively.

5.3 Assessing the available evidence: safety of WCE

In the identified studies the issue of safety is not always reported and when present, is not dealt with in a systematic manner: 21 out of 27 studies describe events related to safety events.

We analysed the information reported in the studies by categorising it into two major groups: Adverse Events (AE) and Technical Problems (TP). The events within the first category are directly related to the patient's safety, while TPs are indirectly related. Those events can cause repetition of a procedure which has an impact on the patient's safety as they undergo another procedure, increasing their overall chance of having an AE. The AE category can be further divided into four types of events on the basis of their severity: None, Self Resolving Symptoms (SR), e.g. problems in swallowing capsule, problems in passing the stomach, Therapy (T), e.g. retention of capsule for more than 1 day but not requiring invasive interventions, Surgery/Intervention (SI), e.g. retention of capsule requiring intervention with PE or surgical, and Mortality (M). The TP category can be divided into two types: the Battery Failure (BF) and Battery expiry (BE). In the first case it is a technical problem due to the technology itself, while in the second case the WCE battery can end up by running out before reaching the small bowel, this being related to the specific characteristics of the patients.

In OGIB the five studies comparing WCE with DBE (Matsumoto et al.¹⁹, Hadithi et al.²⁰, Nakamura et al.²¹, Gay et al.²², Xiao-bo et al.²³) report safety information, although in Gay et al.²² was limited to a one-line sentence stating that both procedures had no "major complications". WCE had no complications in 3 out of 5 studies, and DBE in 2 out of 5. All events reported about DBE are SR: Hadithi et al.²⁰ describe abdominal pain in 29% patients, while in 2 patients the procedure had to be interrupted (3%); Nakamura et al.²¹ report that 1 patient refused DBE (3%), while Xiao-bo et al.²³ state that 18% of patients reported discomfort after DBE. Complications reported for WCE were almost all self resolving, but some did require surgery, and were related to the expiry of the battery. In the study by Xiao-bo et al.²³ involving 218 patients, 0.5% had the capsule detained in the lower oesophagus and one of them interrupted the examination. In 2%

of patients the capsule was retained, and 2 patients underwent surgical removal. 19% patient's capsule battery expired before reaching the caecum. Three of the 4 studies comparing WCE and PE (Mylonaki et al.¹³, Mata et al.¹⁴, Adler et al.¹⁵) provide information about safety. PE did not have any complication, while WCE had both different types of adverse events, such as self resolving and surgical interventions, and technical problems. Mylonaki et al.¹³ describe that in 1 out of 50 patients the WCE remained in the oesophagus for 7 hours and was pushed in the stomach by an endoscope. In 7 patients the capsule passed into the pylorus and returned to the stomach (in one patient this occurred 7 times), while Mata et al.¹⁴ report that 1 patient retained asymptotically WCE for 48 days (natural expulsion) and in 1 patients it was removed by laparoscopy. Mylonaki et al.¹³ describe the battery running out in 16 patients (28%), while in 3 patients there was a loss of images due to temporary electrical disconnection. In 1 patient the battery expired after 2 hours. Mata et al.¹⁴ in 3 patients (7%) illustrate that WCE did not reach the ileocecal valve by the end of the recording time.

Costamagna et al.²⁵ Golder et al.²⁷ and Hartman et al.²⁹ report just 1 case (5%) of battery failure (Costamagna et al.²⁵) and 1 case of malfunctioning (3%) of the capsule (Golder²⁷), while Hartmann²⁹, comparing WCE versus Intraoperative endoscopy reports 1 mortality case for IE. Percentages and data for the two main categories of complications in all the studies about OGIB patients are summarised in Tab. 5.1. (see Appendix 5, for a detailed analysis of each category of complications and type of problems in each study).

Table 5.1 Complications with WCE in OGIB patients

	N° of patients	%
Technical problems	80	9%
Adverse events	23	3%
Total OGIB patients	863	

In CD studies adverse events occurred on average in 2% of patients (Appendix 4). In an average of 2.5% of cases the capsule battery expired (Golder et al.²⁷; Voderholzer et al.³⁴), while Ho Chong³³ reports that the capsule failed in 29% of patients. For CD studies we had to introduce a further variable while synthesising data on safety, otherwise the incidence of capsule retentions could have been underestimated. In most of the studies testing the diagnostic accuracy of WCE in detecting CD lesions, patients often undergo RX first, which is also a means of selecting patients with no intestinal strictures (a widespread characteristic of CD disease) and enrolling them in the study as eligible to WCE. As a result 10% of the CD patients cannot undergo the WCE procedure as retention problems might occur (see tab. 5.2).

Table 5.2 Complications with WCE in CD patients

	N° of patients	%
Technical problems	2	1%
Adverse events	6	2%
N° patients not eligible for strictures detected before WCE	29	10%
Total eligible CD patients	281	

For FAP, just two of the three studies reported data on safety. In Wong et al.³⁷, 8 patients retained the capsule which was later removed, and in Schulmann al.³⁶, the battery expired in 1

case and the capsule was retained by two patients. AD occurred in 9% of cases and technical problems just in 1%.

Table 5.3 Complications with WCE in FAP patients

	N° of patients	%
Technical problems	1	1%
Adverse events	8	9%
Total OGIB patients	92	

The studies selected for our review involved a total of 1236 patients: adverse events with WCE occurred in the 3% of cases and technical problems in 7%.

These data from literature must be compared with the primary data collected in our national survey involving a number of patients which is almost double (see Par. 6.1.2). In our research WCE procedure caused harms in 1% of cases, while in the 15% of patients WCE failed for different reasons: in 202 patients the battery failed and in 272 the WCE expired (see Ch. 6, Figure 6.12). Due to these differences between secondary and primary data (whose "power" is supposed to be higher given the number of participating patients) it is possible that a plausible estimation of the real percentage of TP and AE is respectively 1,5% and 12%. Technical problems do not seem to be related to the use of a mark 1 WCE: data of our survey refers to 2006, and in the reviewed studies the year of publication does not seem to affect safety results by decreasing in the number of complications in most recent studies¹ (see Appendix 5).

Table 5.4 Complications with WCE in all patients

	N° of patients	%
Technical problems	82	7%
Adverse events	37	3%
Total patients	1236	

5.4 Assessing the available evidence: Systematic reviews and meta analyses

Marmo et al.³⁸ highlights that failure to visualise the caecum occurs 13% significantly more often in occult bleeders (17%) than in patients with CD (8%) ($P < 0.006$). Authors point out that adverse events were recorded in 29 patients (6%). Capsule retention was more frequent in patients with CD (3% vs 1% OR 4.37). Triester et al.⁴¹ for OGIB report that the risk of capsule retention is 0, 75% in the considered studies, while for CD it is higher.

¹We consider the year to which the data refer and the year of publication of the study as proxies of new version /improved equipment in use.

5.5 Assessing the available evidence: WCE acceptability to patients

Some of the selected studies dealt with the acceptability and tolerability aspects, although few of them did it in a systematic and structured way, e.g. by using questionnaires and explaining the methodology used to collect data from patients. For instance, short passages are dedicated to this issue in many of the assessed articles, but authors tend to take it for granted that patients prefer WCE over any other endoscopic procedures. This means that usually no good evidence is collected in support of this statement, by either qualitative or quantitative methods. We did not consider citations and statements of this kind in our analysis unless supported by evidence. Out of 27 studies, only 3 reported information and data in a more or less systematic manner: Mylonaki et al.¹³, Hadithi et al.²⁰ and Buchaman et al.³¹.

The first three studies compared WCE to procedures considered “more invasive”, while the last one compared it to SBFT, which is an imaging technology supposed to be less invasive. The methods used, although described, are not always well explained: they range from multiple choice questionnaire filled by patients, or views collected by physician’s interviews with patients. No table summing up data and number of respondents is provided and data are reported in a discursive manner in most of cases. The studies by Hadithi et al.²⁰ and Buchaman et al.³¹ do not consider a comprehensive range of dimensions that may define acceptability, focusing above all on pain or swallowing difficulties. All of them report that WCE was preferred to the other procedures.

In the study by Mylonaki et al.¹³, patients were interviewed at follow up and asked to compare WCE and PE painfulness and state their preference: 49/50 preferred WCE over PE, while just 2 patients found it difficult to swallow. PE was painful for 34/50 ($p < 0.05$). Hadithi et al.²⁰ used questionnaires to gather information on tolerability, administrating them during follow up. Questions were about discomfort and other problems related to procedure: DBE resulted to be less tolerated than WCE (40% vs 94%, $p < 0.001$).

5.6 Results

The systematic review of this report is based on 27 studies. Seventeen of them were published after the Belgian report¹² and date from 2005 to 2007. A total of 349 primary studies were identified by the search, of which 17 met our criteria. The chart in Figure 5.1 summarises the flow of studies in the review. A complete list of the studies identified in the literature search and excluded is at Appendix 6. In addition we selected 10 studies published before 2005 from the KCE report¹² by applying our inclusion criteria, and we re-assessed them.

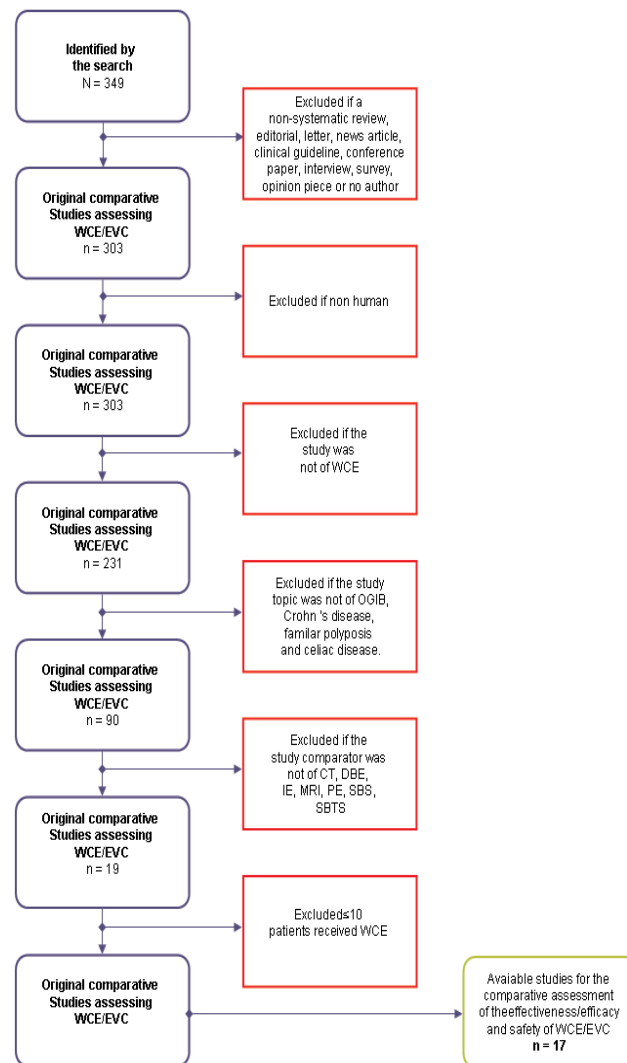
Among the selected literature we could not find any study dealing with costs or economic evaluations. Two studies were supposedly meta analyses. One is from Marmo et al.³⁸, and is about WCE and different comparators used for OGIB and Crohn’s Disease (CD), while the other is from Triester et al.³¹. The authors assessed the evidence comparing WCE with various technologies and for the diagnosis of non stricturing small bowel CD (Appendix 4).

We could identify only one randomised trial out of the 27 assessed studies. Almost all primary studies, no matter the indication and/or comparator, were found to have an unusual study design. This kind of design is simply called by authors “prospective” or “blinded and prospective” when physicians performing the alternative are blinded to the WCE’s results. A rather small num-

ber of consecutive patients are enrolled and serve as their own controls. This means that they undergo both WCE and then comparator (or vice versa) after a certain range of time: in 7 studies the range was not reported, in 6 it went from 1-6 days, and in 9 from 7 to 14 days, while in two studies the time range between one procedure and the other was more than 15 days (Figure 5.2).

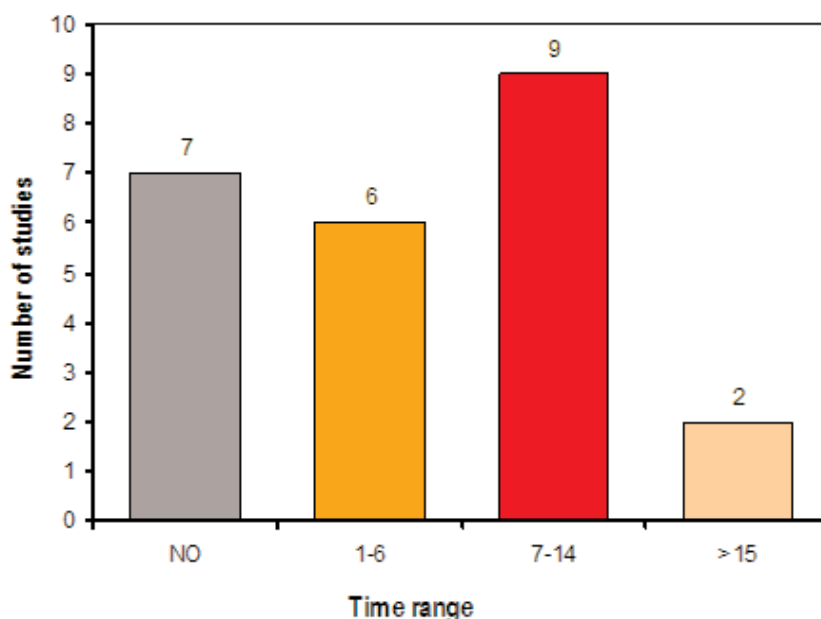
This design has two major linked biases. One due to the absence of randomisation and the other related to the time range in the various studies. The lesions causing OGIB, in many cases, may vary and change in a few days. The most frequent reason for OGIB is angiodysplasia (Lewis⁴) which, by its very nature, undergoes very rapid morphological changes (Norman⁴³). This implies that the results of the final studies are not fully reliable due to the too long or even not declared time range between one procedure and the other. In conclusion the studies compared the incomparable.

Figure 5.1 Flow Chart A total of 349 primary studies were identified by the search, of which 17 met the criteria for the comparative assessment of the effectiveness/efficacy and safety.



Key: EVC=Video Capsule Endoscopy

Figure 5.2 Time range (days) in the eligible twenty-four primary studies.



Given the absence of randomised trials and the peculiarities of the chosen design, we tried to understand reasons for design and comparator asking the authors directly, by sending them a formal e-mail with some questions. We received 7 answers (out of 18 authors contacted) from which we understood that choosing the same group of patient was seen as the best option guaranteeing comparability of results. The confounding variable related to the morphological change of many potential sources of bleeding was usually underestimated or ignored. In addition no motivation was provided about not choosing to randomise patients into two groups undergoing different diagnostic procedures (see Appendix 7).

In the preceding sections we described shortcomings, characteristics and results of each study by dividing and grouping them according to the disease/s they referred to and to the comparator. For each study we focus on three main dimensions and related outcomes: diagnostic accuracy, safety and patient's acceptability of WCE and comparator. The two systematic reviews are described and assessed in a separate paragraph.

However findings and subsequent conclusions from the selected literature about WCE and its diagnostic accuracy, safety etc. have to be regarded as uncertain, as these results are based on low quality evidence. The only reliable results are those from the RCT by De Leusse et al.¹⁸.

6. Collecting context specific data

The collection of context specific data was important to gain a complete picture of the diffusion and use of the WCE, its costs, appropriateness of use and patient's tolerability in Italy. In our country WCE was introduced in the market with no governance at regional or national level in 2001 and according to experts it is being used in many centres.

We carried out two surveys. The first was aimed at collecting data on the actual diffusion of WCE in the year 2006, its direct costs and appropriateness of its use from Italian centres delivering WCE; the second was about patient satisfaction with WCE compared to other endoscopic interventions, and involved 5 centres, chosen amongst those which completed the first survey's questionnaires, on the basis of the highest use of WCEs per year. The following sections provide a detailed description of materials, methods and main results for each of the two surveys.

6.1 Appropriateness of WCE use and related costs in the Italian context

6.1.1 Objective, materials and methods

The aim of the survey was to collect primary information and data on the diffusion of WCE (2006), appropriateness of WCE use and on costs to generate an economic impact scenario for the use of the technology.

We identified all Italian centres that could potentially provide WCE, to obtain a comprehensive population denominator for the survey. Due to Italian informative system shortcomings this was not an easy task and the merging of three different databases and sources of information was necessary. Our final denominator was 116 Italian centres providing WCE diagnostics in 2006 (Lorenzatto s.p.a. data). This inclusive list was drawn from three sources:

- a) Ministry of Health Database (gastroenterology and endoscopy centres)
- b) Italian Club of Wireless Capsule Endoscopy(CICE)
- c) Data from the Italian distributor M.G. Lorenzatto S.p.a..

A structured questionnaire was sent by post to all the 116 physicians identified as responsible of the various endoscopic and gastroenterology centres providing WCE. The collection of data lasted from December 2007 to April 2008.

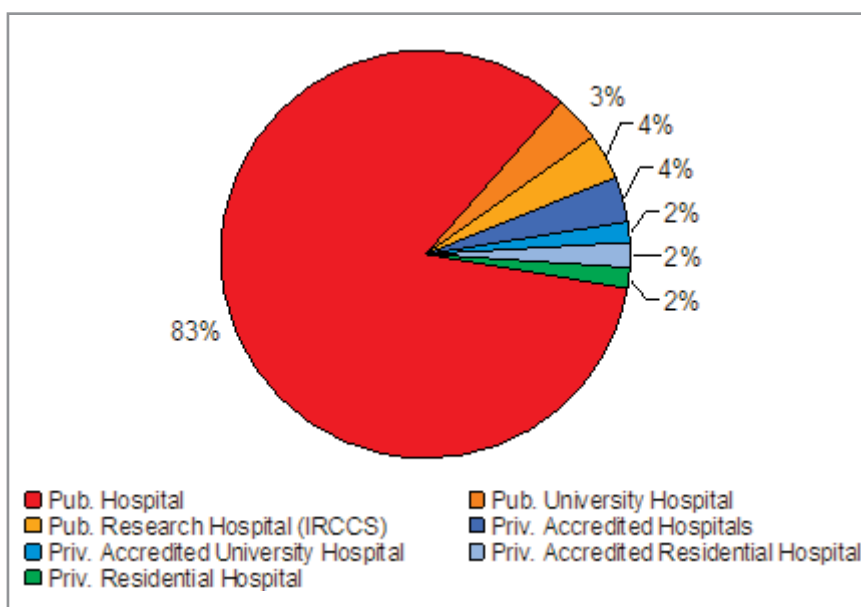
Responding centres (Appendix 8) were 48% of the total (56/116 filled questionnaires returned). The questionnaire aimed at gathering information on three areas: characteristics of the centre, clinical information about patients undergoing WCE, costs of WCE procedure in terms of human resources, device and equipment and consumption material (Appendix 9).

6.1.2 Results

Characteristics of responding centres

Among the 56 responding centres delivering WCE, the majority were public: 51 were public structures (91%, 46 public hospitals, 2 university hospitals, 2 research hospitals-IRCCS), while only 4 were private accredited providers (2 hospital trusts, 1 university hospital, 1 residential hospital) with a contractual agreement (7%) and 1 was a completely private centre (Figure 6.1). Accredited centres with contractual agreement can provide services on behalf of the public health service, and are reimbursed. Completely private centres provide services which are paid directly by patients or private insurance. The majority of responding centres (32, 57%) were located in Northern Italy, 8 were from Central Italy (14%), while 16 (29%) were from Southern Italy and Islands.

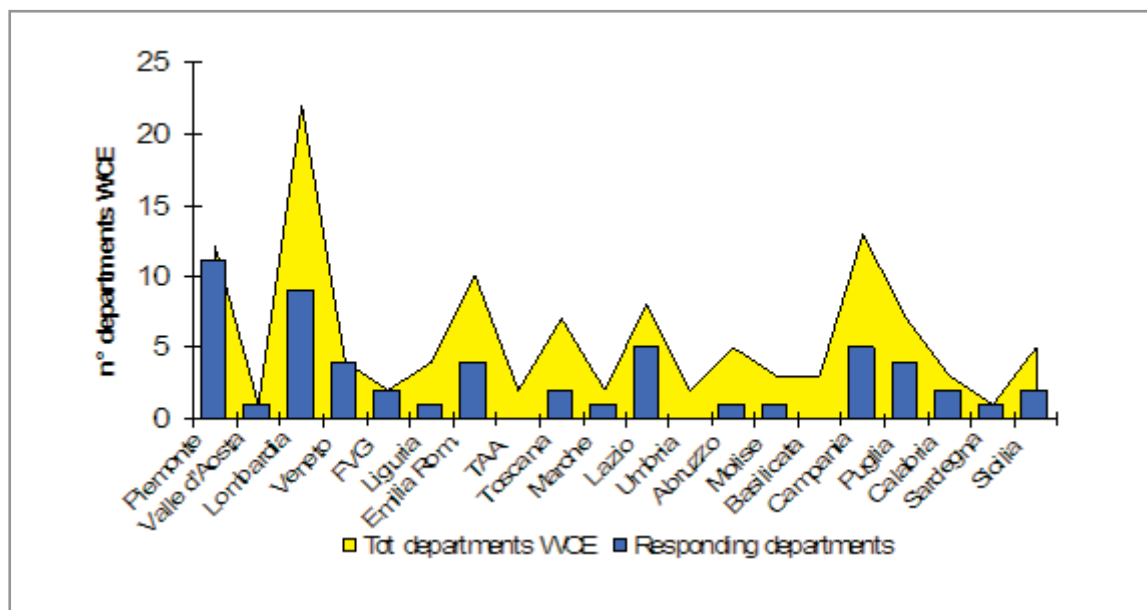
Figure 6.1 Type of centres delivering WCE (year 2006)



Source: data from responding centres analysed by age.na.s

Comparing the data provided by the only Italian distributor of WCE in 2006, with the data obtained from the survey, we can see that the highest number of centres providing WCE is in Lombardy (22 centres) of which 9 (41%) answered to the questionnaire (Figure 6.2), while none of the centres of Basilicata (3 centres), Umbria (2 centres) and Trentino Alto Adige (2 centres) replied to the questionnaire. At regional level responsiveness was 58%.

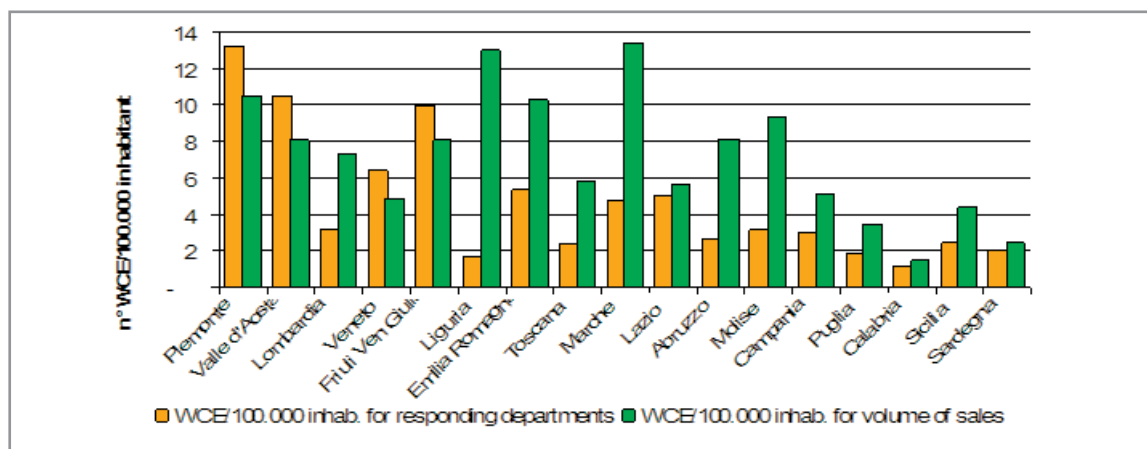
Figure 6.2 regional distributions of centres



Source: age.na.s and M.G. Lorenzatto S.p.a., 2006

The data provided by M.G. Lorenzatto S.p.a./Given Imaging Ltd show that the highest number of WCE sold per 100.000 population is in the Liguria and Marche Regions, where 13 capsules every 100.000 population were used. More than 10 capsules per 100.000 population were used in Emilia Romagna and Piemonte (10 and 11 WCE/100.000 respectively). The Region with the smallest number of WCE per 100.000 population is the Calabria region with 1/100.000 population (Figure 6.3). Comparing these data with data obtained from the survey highlights the fact that in some cases the total number of WCE purchased in 2006 was higher than the total of WCE examinations performed in same year.

Figure 6.3 Regional distribution of WCE per 100.000 population and WCE/100.000 inhabitant for volume of sales - year 2006



Source: age.na.s and M.G. Lorenzatto S.p.a., 2006

Clinical information

The 56 responding centres performed a total number of 2.457 WCE procedures (63% of the total number of WCEs sold by the Italian distributor in 2006). A WCE procedure can be performed on inpatients, outpatients or in a day hospital basis. Data from the survey show that on a total of 2447 WCE performed in Italy, 43% involved admission to hospital of the patient (length of stay > 1 day), while 31% were performed in ambulatory care and 26% in day hospital (Table 6.1)

Table 6.1 Number of WCE by level of care

Total WCE/2006	Levels of care		
	Inpatient/hospital	Outpatient/ambulatory	Day Hospital
2447*	43%	31%	26%

48

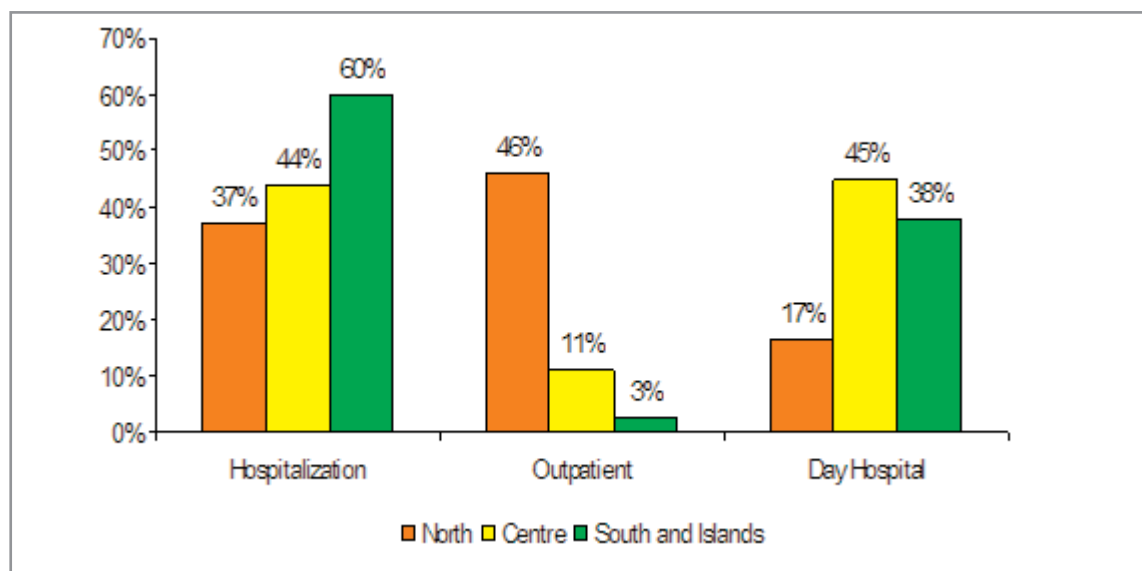
Key: * missing data on 8 WCE

Source: data from responding centres analysed by age.na.s



Responding Northern Regions tended to perform this diagnostic procedure more in ambulatory care (46%), although the difference is not large (Fig 6.4). Central Regions use more day hospital (45%) and inpatient care (44%), while just 11% of the responding centres in those regions performed WCE in ambulatory care. In the responding centres from the South and Islands inpatient care is prevalent (60%), followed by day hospital (38%) and inpatient care (3%).

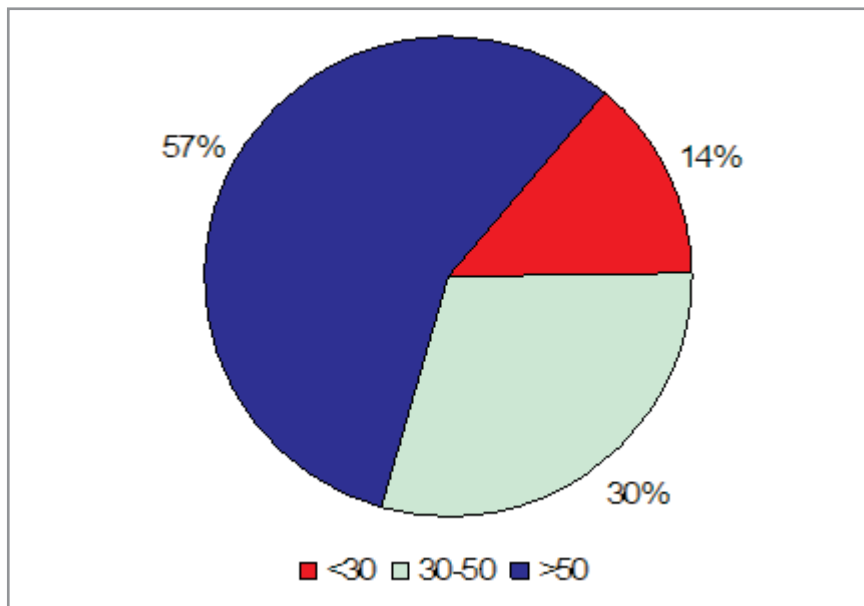
Figure 6.4 Levels of care and geographical distribution of diagnostic procedure per year (2006)



Source: data from responding centres analysed by age.na.s

The 57% of patients undergoing WCE in the responding centres were older than 50 (1391; 57%), 30% (734) were aged 30-50 years and 14% were less than 30 years old (Figure 6.5).

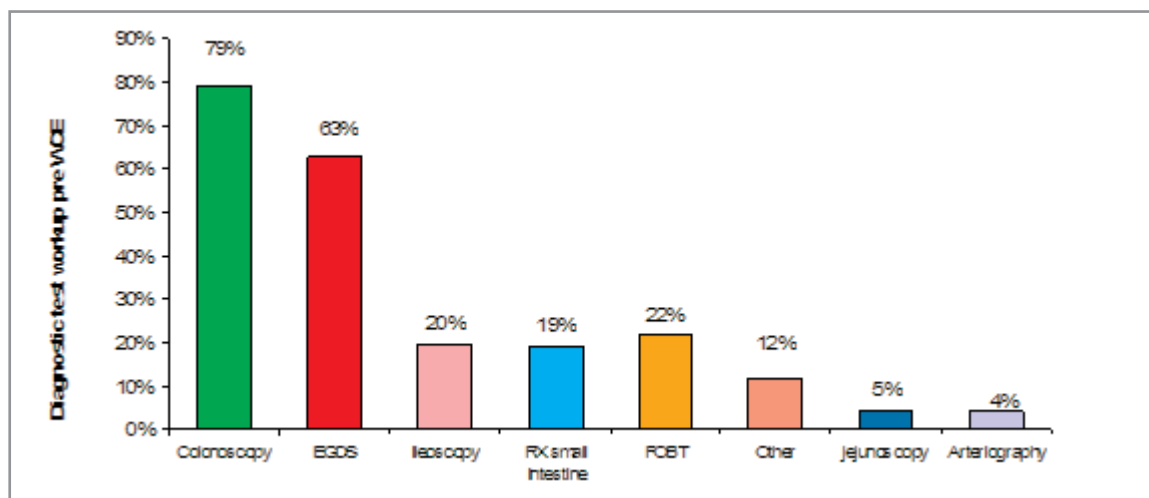
Figure 6.5 Age distribution of users (2006)



Source: data from responding centres analysed by age.na.s

Patient's diagnostic work up was reported by 93% of centres (52/56). The main exams performed before WCE were: colonoscopy, performed by 79% of patients, Esophagogastroduodenoscopy - EGDS (63%), followed by Faecal Occult Blood Test - FOBT (22%), Ileoscopy (20%), RX of small intestine (19%), and Other (5%: Abdominal CT, Abdominal MR, Scintigraphy, PET, etc.), jejunoscopy (5%) and Arteriography (4%). Patients underwent an average of 2 diagnostic examinations before WCE (Figure. 6.6).

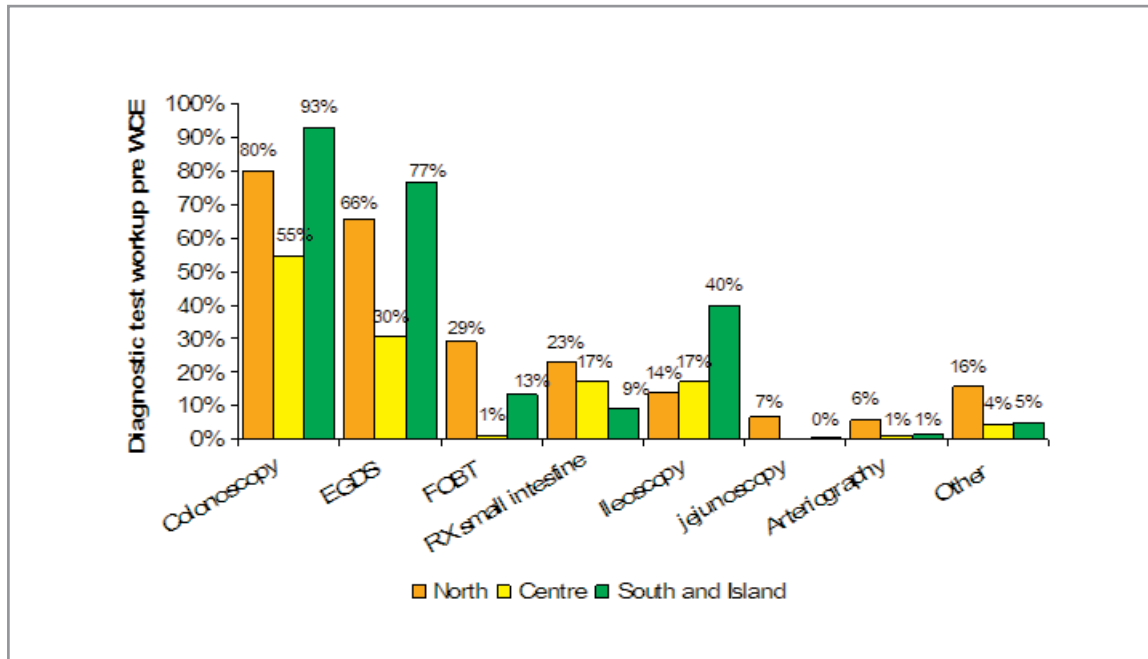
Figure 6.6 Diagnostic test workup pre WCE in Italy (2006) (N=2374 Total WCE N =5300 Total Diagnostic Tests)



Source: data from responding centres analysed by age.na.s

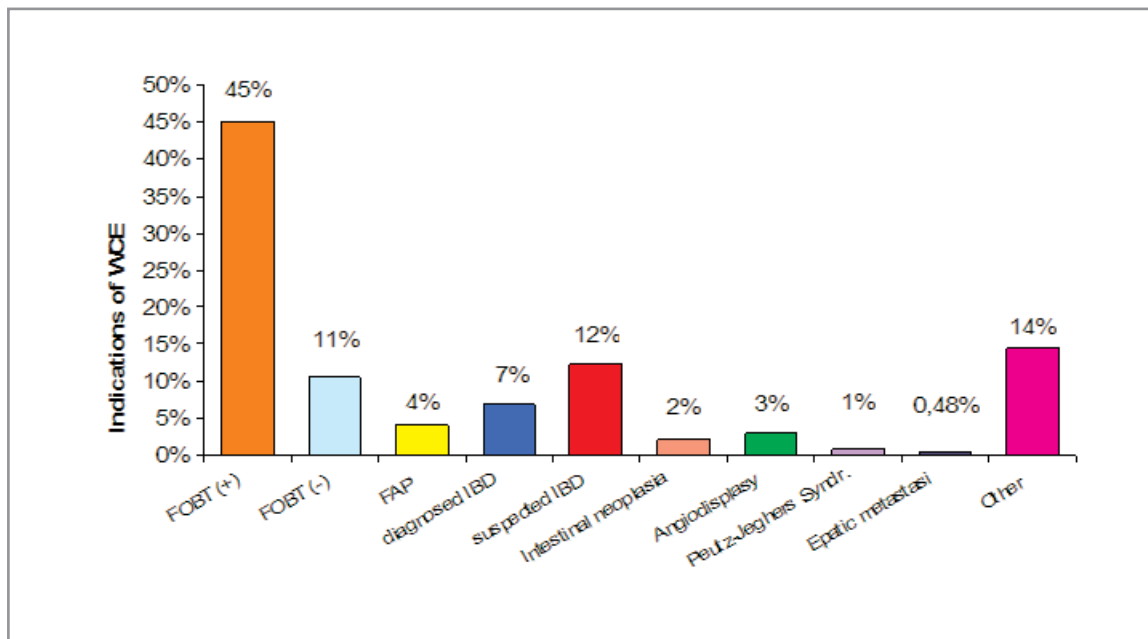
In the three geographical areas, the diagnostic tests performed prior to WCE are similar, however in the central Regions' centres FOBT is less common (0.7%), compared to its average use (10%) (Figure 6.7).

Figure 6.7 Diagnostic Test workup prior to WCE by geographical location (n=2374 WCE; n=5300 DT)



Source: data from responding centres analysed by age.na.s

Figure 6.8 Indications for WCE use (n=2504)

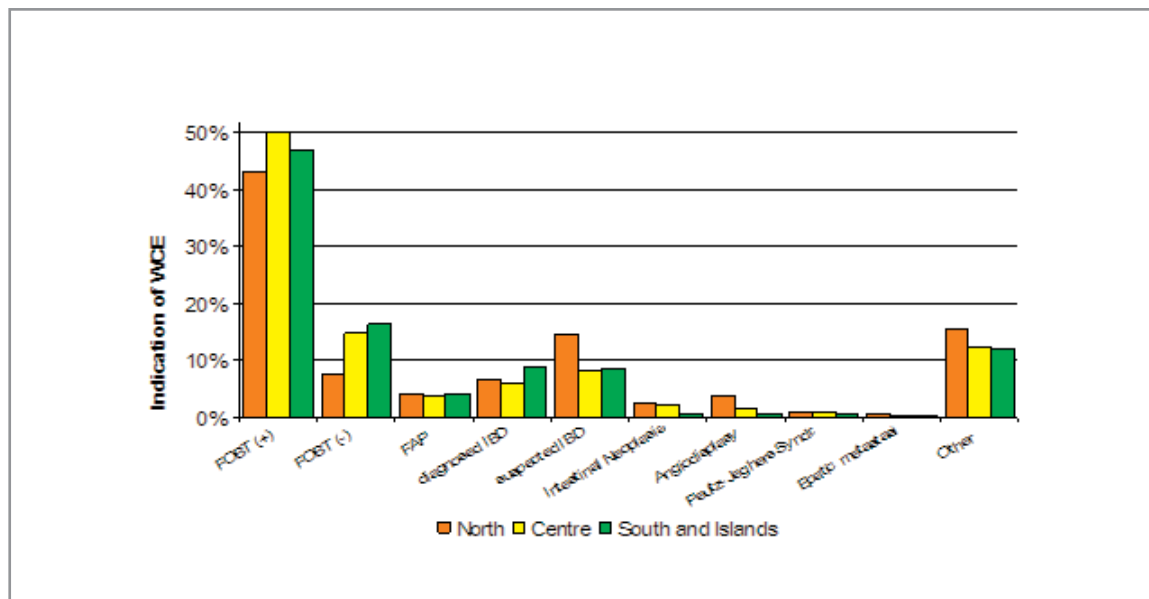


Source: data from responding centres analysed by age.na.s

The most frequent indication to undertake WCE was a positive FOBT (45%) and in 11% a negative FOBT, while 12% of patients had a suspected or diagnosed (7%) IBD. In 4% of patients the indication was FAP. Angiodysplasia, which is the mostly frequently detected pathology by WCE (see results below) was the indication in only 3% of patients (Figure 6.8).

The distribution of indications to undertake a WCE diagnostic test, in the three geographical areas, shows no relevant differences. (Figure 6.9)

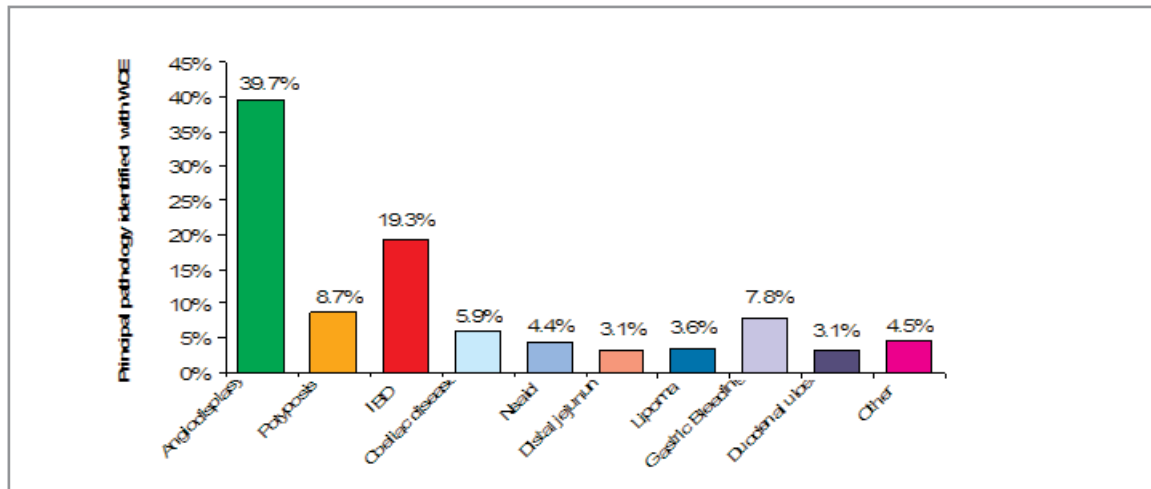
Figure 6.9 Reasons to carry out WCE by geographical location (n=2504)



Source: data from responding centres analysed by age.na.s

All 56 responding centres reported diagnoses made by WCE (Figure 6.10). The most frequent were angiodysplasia (39.7%) (751 patients) and Inflammatory Bowel Disease (IBD, 366 patients, 18%).

Figure 6.10 Main pathologies identified with WCE (n=1900)



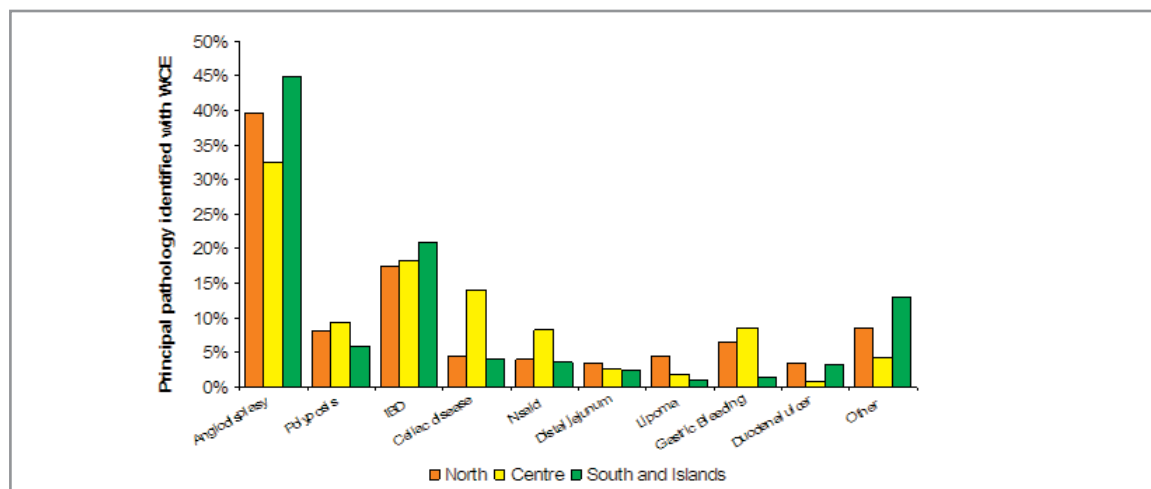
52

Source: data from responding centres analysed by age.na.s



The geographical distribution (divided into North, Centre, South and Islands, see Figure 6.11) shows consistency for the most frequently diagnosed pathologies (Angiodysplasia, Polyposis, IBD, Distal jejunum, Lipoma and Duodenal ulcer) when compared to the National situation. However, diagnosis of CDO is more prevalent in the Centre of Italy (14% of diagnosis compared with 4.5% of the North and the 4% of the South and Islands), the same goes for NSAIDs with a prevalence in the Centre of 8.21% compared with 3.8% in the North and the 3.5% in the South and Islands. Finally, the diagnosis of gastric bleeding is more frequent in central Italy (8.5%) and in the North (6.5%) in comparison to the South and Islands (1.4%).

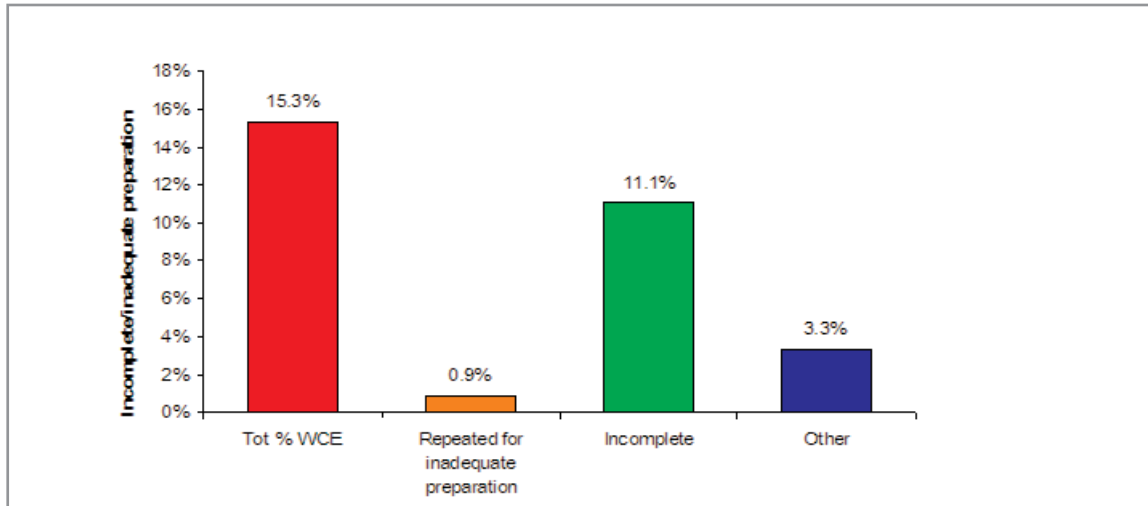
Figure 6.11 Principal pathology identified with WCE by geographical location (n=1900) year 2006



Source: data from responding centres analysed by age.na.s

The WCE procedure caused harms in 1% of cases (17 patients): 9 patients retained the capsule, 6 had an intestinal occlusion and 2 a delayed clearance and sub-occlusion. In 375 (15%) of patients the WCE procedure failed for various reasons: in 202 patients the battery failed and in 272 the WCE expired. Three percent of patients had to repeat the exam for inadequate preparation (Figure 6.12).

Figure 6.12 Incomplete/inadequate preparation for WCE procedure in Italy (n=375) year 2006



Source: data from responding centres analysed by age.na.s

Intervention after WCE

Ninety one percent of responding centres (51/56) answered the open questions which were based on the most frequent clinical decisions following a WCE test (Table 6.3). In most cases respondents reported medical therapy (including for IBD), and surgical intervention as the two most frequent types of intervention.

Table 6.3 Interventions after the WCE test

Surgical/clinical decisions after performing WCE
Medical Therapy
Medical management of IBD
Surgery
Push Enteroscopy
Gluten-free diet
Laparoscopy
Endoscopic therapy
Enteroscopic treatment with argon plasma
Chemotherapy
Clinical remission within three years
Enterography to remove polyps
Chemotherapy against lymphoma
Therapy with argonplasma coagulation
Thermic coagulation therapy for bleeding from Angiodysplasia
Endoscopic examination for Angiodysplasia
Follow up
Laser therapy
Embolisation
Iliac-release mesalazine for patients with iliac CD
Angio-Tac Scan
Gastroscopy with General Anaesthetic

Key: IBD=inflammatory bowel disease

Costs related to the use of the WCE

Health personnel and average time per WCE procedure

Responding centres were asked to indicate the average time (in minutes) spent by four types of hospital personnel: physicians, nurses, support operators, administrative officers. Procedures were divided into three phases, and we asked how much time each figure spent in each phase.

- Preparation: the time for the preparation of the patient (wearing of the recording belt, WCE swallowing, etc.);
- Medical reporting: scanning and analysis of the acquired images and diagnosis;
- Consultation: time spent in meeting the patient and discussing procedure and diagnosis.

Almost all the responding centres (53/56, 94.5%) returned data on average time spent by the different actors on a standard WCE procedure (Table 6.4). The distribution of reported time values are reported as the mean time spent, its 95% confidence interval (CI), the minimum, the maximum and the mode as calculated from data returned from responding centres.

Table 6.4 Average time (in minutes) spent in a standard WCE procedure by type of healthcare worker

	Preparation	Medical Reporting	Patient Meeting
Physician			
Average	22	123	21
CI (95%)	(19-25)	(108-138)	(18-24)
min-max	(10-45)	(45-240)	(10-45)
Mode	15	90	15
Nurse			
Average	26	20	13
CI (95%)	(22-30)		(8-17)
min-max	(15-45)	20	(10-15)
Mode	20	20	(10-15)
Support operator			
Average	10		
CI (95%)	(6-14)		
min-max	(5-20)		
Mode	10		
Administrative officer			
Average	10	7	4
CI (95%)	(7-12)		
min-max	(3-20)	(3-10)	(2-5)
Mode	10		

Note: A support operator is solely involved in preparation for an average time of 10 minutes.

Source: data from responding centres analysed by age.na.s.

For a standard WCE procedure, the mean time spent by the physician was estimated at around 166 minutes (22 minutes for WCE preparation; 123 minutes for medical reporting; 21 minutes for meeting the patient). Considering the mode values, a standard WCE procedure takes a total of 120 minutes (15 minutes for preparation; 90 minutes for medical reporting; 15 minutes for patient meeting).

The average time for a nurse was estimated at 39 minutes (26 minutes for preparation; 13 minutes for meeting the patient). In only one of the responding centres the nurse collaborated in medical reporting for an average time of 20 minutes. The mode was estimated as 30-35 minutes (20 minutes for preparation; 10-15 minutes for meeting the patient).

An administrative officer is involved in preparation for an average time of 10 minutes but few centres report that this professional figure is further involved in medical reporting (mean time of 7 minutes) and patient meeting (mean time of 4 minutes).

We performed further analysis on the average time that the physician spends for the scanning/analysis/examination of the acquired images. The number of WCEs performed in one year in the responding department has been considered as the relevant parameter (Table 6.5). We grouped centres as:

- Centres performing up to 30 WCE procedures per year;
- Centres performing between 30 and 60 WCE procedures per year;
- Centres performing 60 or more WCE procedures per year.

The data shows less time spent in medical reporting in those centres performing a high rate of WCE procedures per year.

Table 6.5 Average time for medical reporting stratified by the number of WCE procedures performed per year

Physician	<30 WCE	30-60 WCE	>60 WCE
Average	127	85	82
Mode	120	90	60

Source: data from responding centres analysed by age.na.s.

Disposables

During the observation period (2006) all of the 56 responding centres used the Given Imaging Ltd WCE supplied by Lorenzatto s.p.a. Since the capsule cannot be reused after the procedure, it was considered a disposable item. Some of the responding centres (12/56, 21%) used the patency-test capsule prior to the WCE. This device is used to identify strictures prior to the introduction of the WCE (see Appendix 2a for technical details). Disposables used are reported in Table 5 and 6 and were: gauzes, gloves, disposable sheets, razors, disinfectants, prokinetic drugs, water (0.5 litres), photographic paper, A4 paper, printer cartridges and printer toner (Table 6.66.7).

Table 6.6 Disposables used for one WCE procedure

	N. of centres
Wireless capsule for endoscopy	56
Patency-test capsule	13
Gauzes	13
Gloves	31
Disinfectants: Alcohol, detergent soap, Clorhexidine, Citrosil	12
Disposable sheets	34
Prokinetic drugs: Metoclopramide, Plasil, Dimeticone, Simiticone,	16
Valium	1
Razor	4
Glass and water 0.5 litres	4

Source: data from responding centres analysed by age.na.s.

Table 6.7 Other items used for one WCE procedure

	N. of centres
Toner	14
Printer cartridge	36
Photographic paper	20
Paper (A4 format)	6

Source: data from responding centres analysed by age.na.s.

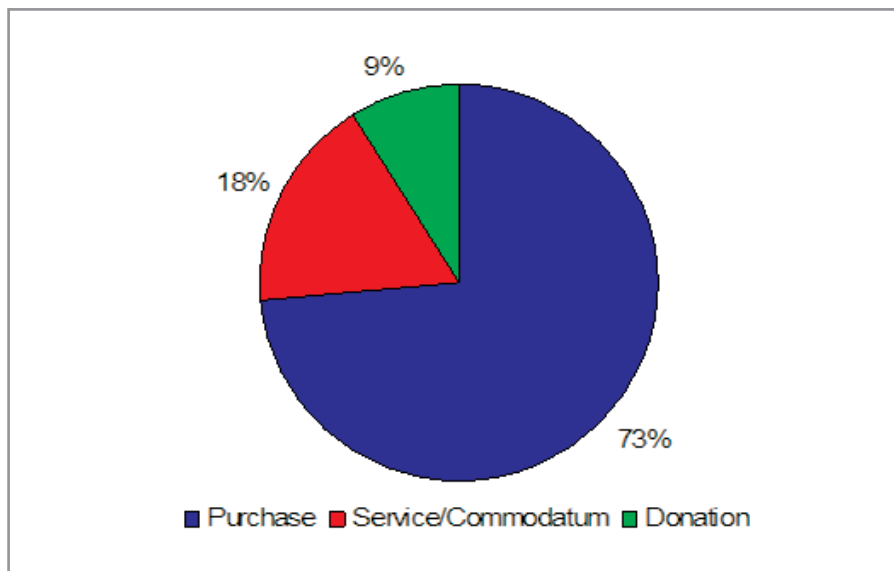
Equipment

Thirty four of the 56 responding centres (61%) returned data about the equipment required for WCE procedures purchased in the period between 2000 and 2006. All the equipment was supplied by Lorenzatto s.p.a. Different methods of acquisition have been identified: purchasing (25 centres), service and commodatum (6 centres), donation (3 centres) (Table 6.13) .

The questionnaire (Appendix 9) allows data reporting of equipment used in aggregate (hardware and software) or as a single element form (hardware and software separately). Data are shown in Table 7.

The majority of centres (34/56, 61%) returned equipment data in an aggregate form. Every acquisition procedure differed in relation to the configuration selected, i.e., basic configuration (Table 6.8) or customised configuration (Table 6.9) with optional equipment.

Figure 6.13 Method of acquisition of WCE equipment



Source: data from responding centres analysed by age.na.s.

Table 6.8 Equipment used in a single WCE

	N. of centres
Hardware+software	34
Software	3
Monitor	4
Computer	5
Equipmant trolley	4
Other equipment:	
Software update	3
Battery	1
Imaging Equipment	4

Source: data from responding centres analysed by age.na.s.

58

Table 6.9 Standard equipment WCE Given Imaging Ltd (2008)

Quantity	Standard Equipment WCE
1	Data recording system for WCE (recording data DR2C with battery, recording belt, 1 battery charger, 1 recording sensor SB, 1 recording sensor ESO, briefcase, 2 tables of instructions)
1	Processing unit Pillcam capsule SB-ESO-COLON (Computer, monitor lcd 20, software rapid 5.2, colour printing, accessory).

Data from M.G. Lorenzatto S.p.a.

Table 6.10 Optional Equipment WCE Given Imaging Ltd (2008)

Quantity	Optional equipment WCE
1	Real time micro read (support for verification of the functionality capsule before the beginning of the examination and for the verification that the WCE transits over the stomach)
1	Software rapid reader (used for viewing and to see the videotaped video rapid 5.1 again on personal computer and to manage an WCE from peripheral unit Given Imaging Ltd)
1	Agile patency capsule Given Imaging Ltd (for the follow-up of the intestinal patency through dissolute capsule)
1	Scanner for the follow-up of the agile patency capsule in the intestine given imaging Ltd
1	Portable hard disk 320 GB Given Imaging Ltd
1	Package of clinical technical training
1	Kit of training to the videoendoscopy capsulare pillcam given imaging

Data from M.G. Lorenzatto s.p.a.

Budget impact of WCE for the Italian NHS

For the assessment of the elements of cost the method of the standard costing has been used. The costs attributed to the various elements used in the WCE was derived as an average of the declared values by centres or when incomplete were derived from market prices. All costs are inclusive of VAT (20%). The average personnel costs (table 6.11) were estimated using the National Collective Contract of Category 2004 inclusive of employer's contributions.

Table 6.11 Average cost of personnel involved in the WCE procedure in Euros

	WCE	Medical Reporting	Consultation
Physician			
average	€ 24,06	€ 135,36	€ 23,06
range	€20,90-€27,50	€118,80-€151,80	€19,80-€26,40
Nurse			
average	€ 11,09	€ 8,53	€ 5,33
range	€9,39-€12,80		€3,41-€7,25
Support Operator			
average	€ 3,38		
range	€2,03-€4,74		
Administrative costs			
average	€ 3,38	€ 2,37	€1,35
range	€2,37-€4,06		

Source: data from responding centres analysed by age.na.s.

The costs of consumed materials were valued as indicated by the responding centres and when incomplete were based on market prices (Table 6.12). For some items (standard WCE and patency test WCE) price data were provided by the only manufacturer of WCEs in 2006 (Lorenzatto s.p.a. authorised distributor of Given Imaging Ltd).

Table 6.12 Cost of consumables for a single WCE procedures

	Quantity	Unit Costs in Euros
WCE	1	€ 642,00
Patency test WCE	1	€ 117,60
Surgical Gauze	4	€ 0,08
Surgical gloves	2	€ 0,02
Disinfectant		€ 0,05
Disposable sheets	1	€ 0,18
Prokinetics drugs: Metoclopramide, Plasil, Dimeticone, Simiticone,	10 mg	€ 0,24
Valium	2 mg	€ 0,34
Razor	1	€ 0,10
Paper cup + 1/2 lt. Water	1	€ 0,40
Paper and computer consumables		€ 0,60

*note that the "Patency test capsule" is only used in some centres.

Source: data from responding centres analysed by age.na.s.

The average costs of equipment were derived by the average indicated by responding centres. The single costs of purchasing were discounted to 2006 (the year of reporting) to make them comparable. The depreciation rate is 8 years as declared by the responding centres. Depreciation has been estimated with the method of straight-line depreciation (Table 6.13).

Table 6.13 Average cost of equipment

	N. Centres	Quantity	Purchase year	Depreciation	Average cost
Equipment WCE	25	1	2000-2006	8	€ 43.108

Source: data from responding centres analysed by age.na.s.

The overall average cost of a single examination with WCE is subject to variation on the basis of the volume of annual examinations carried out by each centre. Three different budget impacts (table 13) have been estimate according to the volume of examinations carried out in the centres with a high, medium and low throughput:

- 10 annual WCE examinations;
- 44 annual WCE examinations;
- 190 annual WCE examinations.

In the first case (centres with 10 annual WCE examinations) the estimate of economic impact caused by a single examination WCE is € 1.624,30, in the second case (centres with 44 annual WCE examinations) it is € 1.108,41 and in the third case (centres with 190 annual WCE examinations) € 998,28. The number of annual examinations undertaken influences the unit costs in presence of a set number of annual WCE examinations (Table 6.14).

Table 6.14 Average direct costs of a single WCE for volumes of examinations

Average direct cost in Euros of a single WCE procedure by centre throughput			
	Low use (n=10 WCEs)	Medium use (n=44 WCEs)	High use (n=190 WCEs)
Staff	€ 203,64	€ 161,82	€ 158,52
range	€ 176,02-€ 231,16	€ 145,26-€ 178,26	€ 141,96-€ 174,96
Equipment	€ 581,71	€ 132,21	€ 30,62
Capsule Endoscopy	€ 642,00	€ 642,00	€ 642,00
Materials of consumption	€ 2,00	€ 2,00	€ 2,00
Average unit cost per WCE procedure	€1.429,35	€ 938,03	€ 833,14
range	€ 1.402,37-€1.457,51	€ 921,47-€ 954,47	€ 816,58-€ 851,58
Other WCE costs			
	Department WCE=10	Department WCE=44	Department WCE=190
Patency test WCE	€ 117,60	€ 117,60	€ 117,60
General costs (5%)	€ 77,35	€ 52,78	€ 47,54
Average unit cost per WCE procedure	€ 1.624,30	€ 1.108,41	€ 998,28
range	€ 1.595,97-€ 1.653,87	€ 1.091,02-€ 1.125,67	€ 980,89-€ 1.015,54

*note that the "Patency test capsule" is only used in some centres.

Source: data from responding centres analysed by age.na.s.

6.2 An assessment of patient's acceptability of the WCE procedure

6.2.1 Objective, materials and methods

Our objective was to collect information on the acceptability of the WCE by patients compared to other endoscopic interventions (Colonoscopy, EGDS) which are supposed to be more "invasive" and thus less acceptable, and to gain a better understanding on the indirect costs of the two procedures from a social point of view.

Five centres amongst the ones that completed our questionnaire were selected on the basis of the highest number of WCE procedures performed per year: from a minimum of 80 to a maximum of 190 WCE per year (Appendix 10). Each centre's physicians who returned the questionnaire and were nominated as responsible for the procedure received a questionnaire for all consecutive patients that, during the chosen time period (February to May 2008), underwent the WCE test. Questionnaires were self administrated. All hospital centres involved sent back the questionnaires. The final analysis was based on a total of 120 questionnaires.

We constructed the questionnaire based on the available literature dealing with WCE patient's satisfaction or acceptability (see section 5 on acceptability), and with the advice of the

gastroenterologists participating in the survey. It was piloted in 20 patients in Lazio Region, to assess filling time, clarity and wording. The final questionnaire was divided into two specular parts aimed at gathering information on the WCE and the latest previous endoscopic procedures undergone by the respondent. Questions dealt with three main aspects that define "acceptability": difficulty of intervention (e.g. problems in capsule swallowing, retention time etc), painfulness during and after the procedure, individual problems in term of movements and anxiety, and final judgement on tolerability of the whole procedure. Socio-demographic data were also collected together with a quantification of the time lost by patients to undergo each procedure.

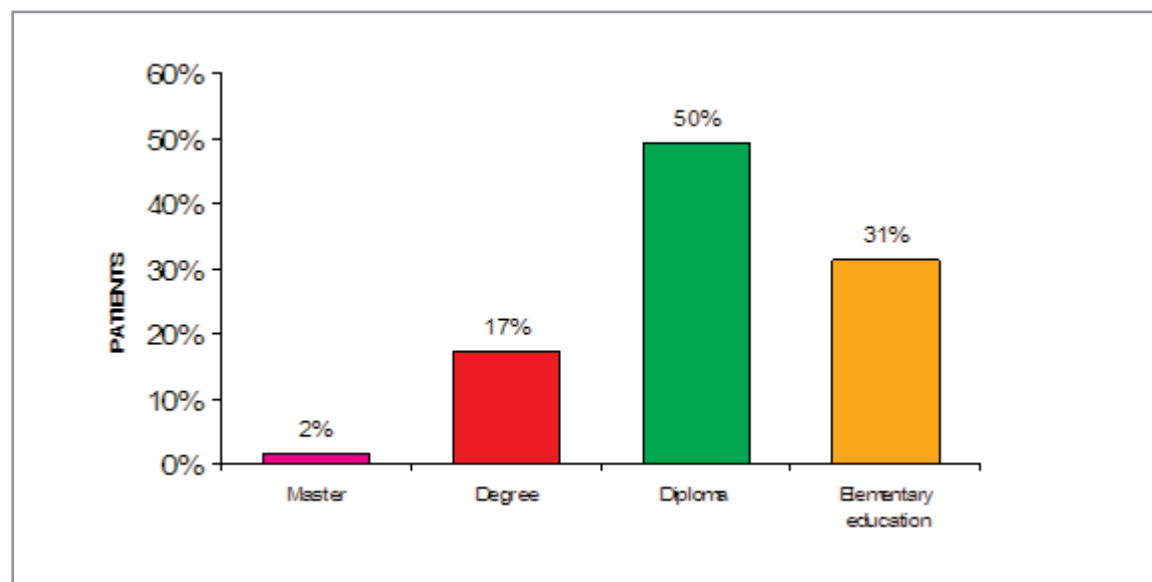
6.2.2 Results

6.2.2.1 Socio economical characteristics of patients

The five selected centres distributed 127 patient questionnaires (54 male e 64 female and 3 not specified). 62% (79) were married, 23% (25) single and 5% cohabiting (17 not specified).

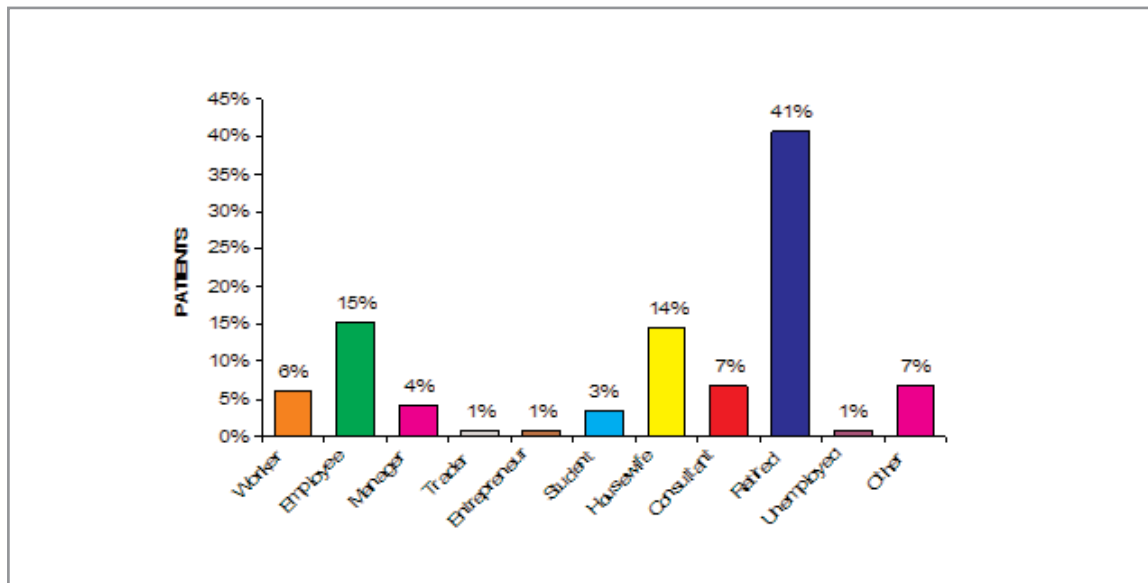
The patient's educational achievements were high school diploma (50%), primary education (13%), university degree (17) and postgraduate diploma (2%) (Figure 6.13). The reported occupations of patients were manual worker (6%), employee (15%), manager (4%), trader (1%), entrepreneur (1%), student (3%), housewife (14%), consultant (7%), retired (41%), unemployed (1%), other (7%) (Figure 6.14).

Figure 6.13 Educational qualification of patients (n=115)



Source: data from responding centres analysed by age.na.s.

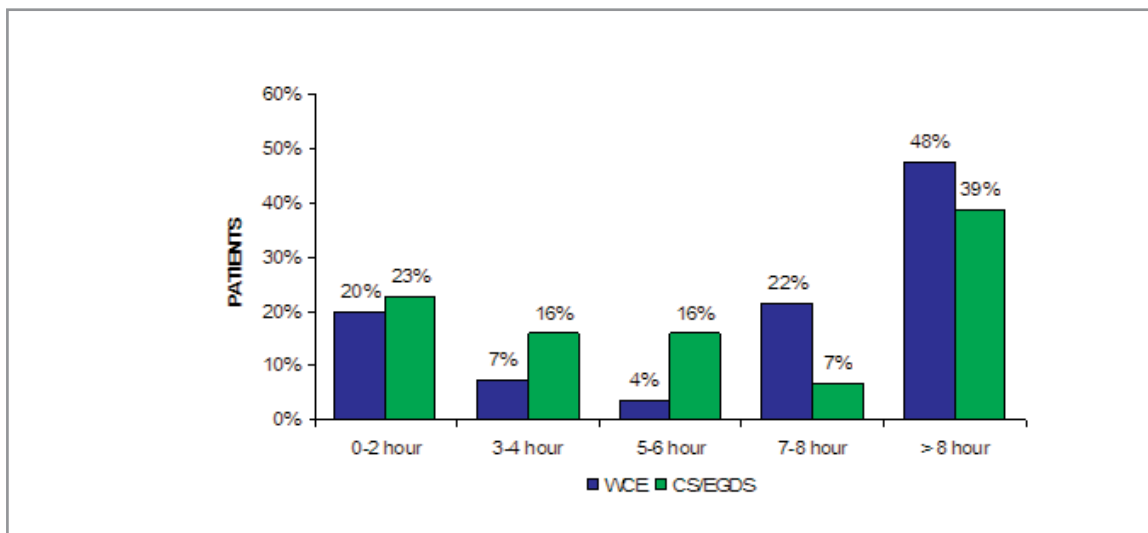
Figure 6.14 Occupation of patients (n=118)



Source: data from responding centres analysed by age.na.s.

Patients undergoing WCE took more than 7 hours off work in 70% of cases. Twenty-two per cent of those undergoing the WCE procedure lost 7-8 hours and 48% more than 8 hours). Forty six percent of those undergoing CS/EGDS lost more than 7 hours (7% lost 7-8 hours and 39% more than 8 hours) (Figure 6.15).

Figure 6.15 Time off work for WCE (n=111) and for CS/EGDS (n=106) recipients

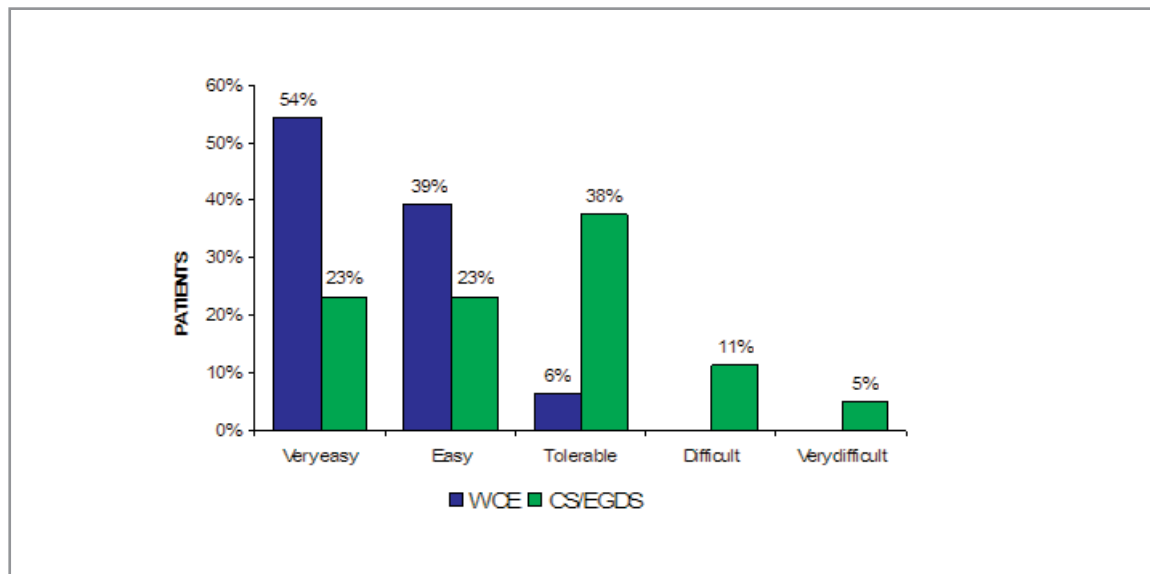


Source: data from responding centres analysed by age.na.s.

6.2.2.2 Acceptability dimensions for the WCE and other endoscopies

Patients indicated a greater ease of performing the WCE in comparison to CS/EGDS (Figure 6.16). Sixteen percent of patients undergoing CS/EGDS indicated a degree of difficulty in the procedure (11% difficult, 5% very difficult).

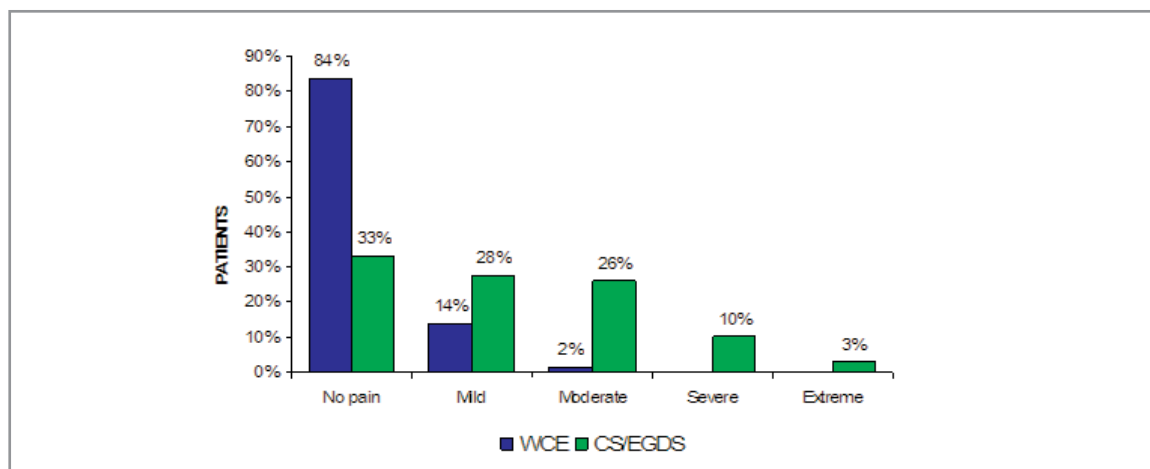
Figure 6.16 Ease of execution of the procedure WCE (n=125) and CS/EGDS (n=125)



Source: data from responding centres analysed by age.na.s.

During the procedures 84% of patients undergoing WCE had no perceivable pain, compared to 33% with CS/EGDS (Figure 6.17). Patients undergoing CS/EGDS felt severe pain in 10% of cases and extreme in 3% of cases.

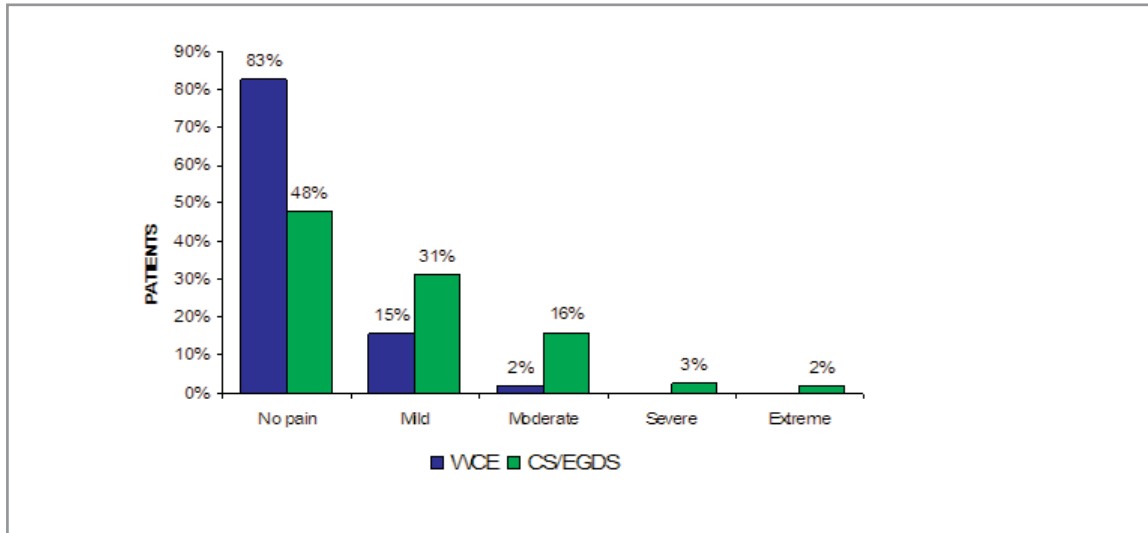
Figure 6.17 Pain during the procedure with WCE (n=123) and CS/EGDS (n=126)



Source: data from responding centres analysed by age.na.s.

After the WCE procedure, 83% of patients experienced no perceivable pain compared to 48% with CS/EGDS (Figure 6.18). Patients who underwent CS/EGDS, felt severe (3%) or extreme (2%) pain after the procedure.

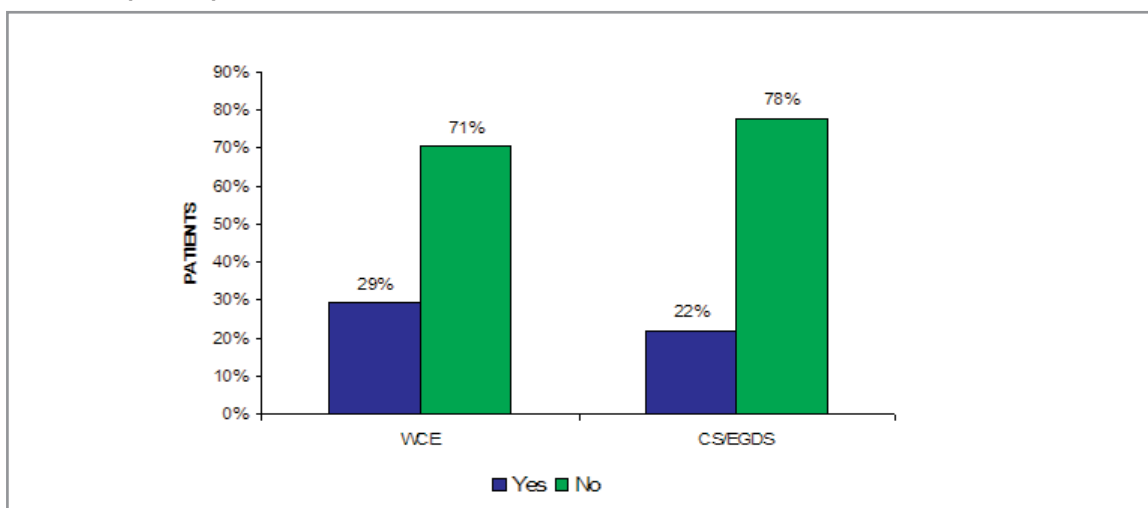
Figure 6.18 Pain after the procedure with WCE (n=110) and CS/EGDS (n=119)



Source: data from responding centres analysed by age.na.s.

Twenty nine percent of patients undergoing the WCE procedure recorded difficulty of movement during the recording and procedure compared with of 22% undergoing CS / EGDS (Figure 6.19).

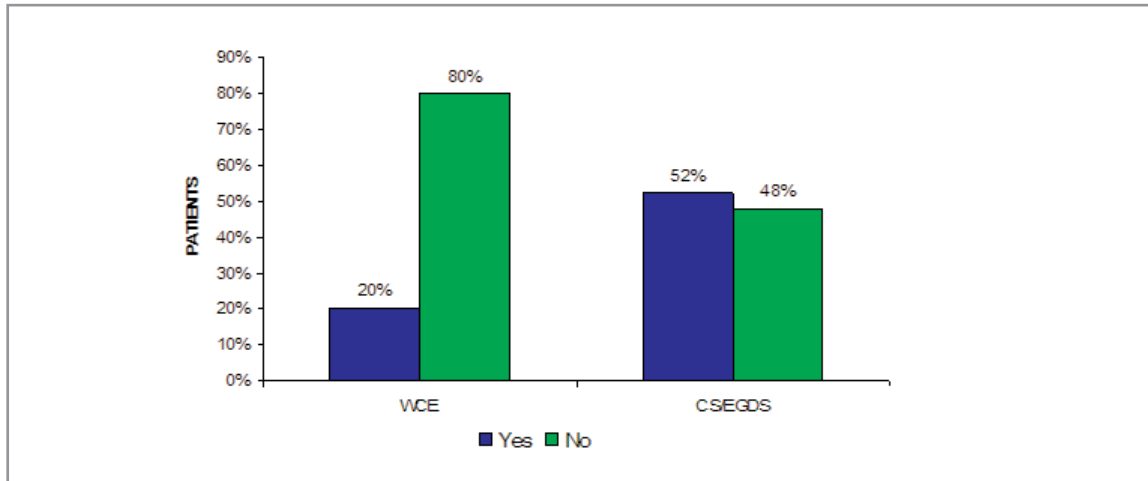
Figure 6.19 Difficulty of movement during the recording/procedure with WCE (n=126) and CS/EGDS (n=117)



Source: data from responding centres analysed by age.na.s.

Twenty percent of patients undergoing WCE reported a state of anxiety compared with 52% of those undergoing CS/EGDS (Figure 6.20).

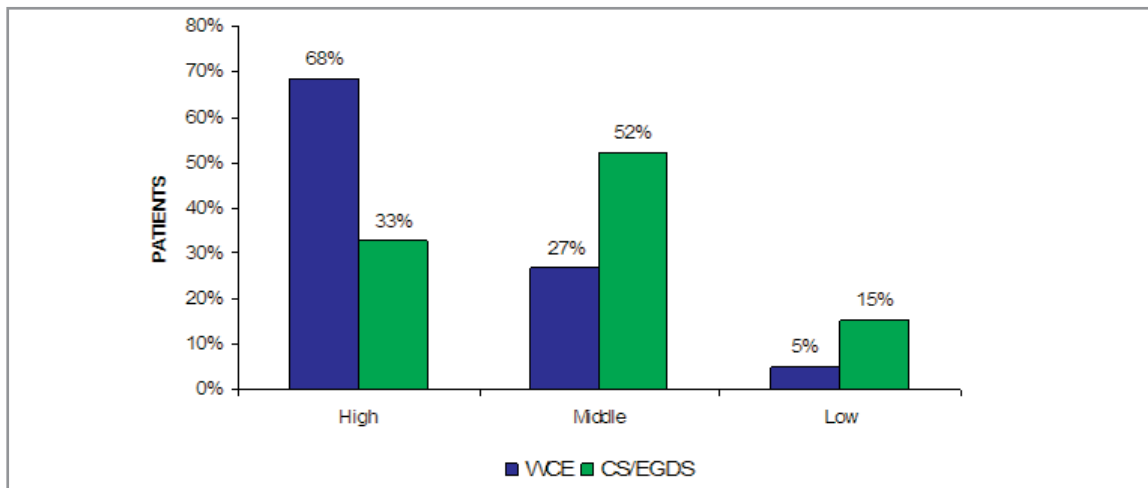
Figure 6.20 Anxiety in patients undergoing the WCE procedure (n=124) and CS/EGDS (n=115)



Source: data from responding centres analysed by age.na.s.

Altogether the level of tolerability in patients is high in 68% of the cases, medium in 27% and low in 5% in the WCE. The patients who underwent CS/EGDS indicated a high tolerability in 33% of cases, 52% a medium level and 15% a low level (figure 6.21).

Figure 6.21 Total level of tolerability of WCE procedure (n=123) and CS/EGDS (n=119)



Source: data from responding centres analysed by age.na.s.

7. Discussion

We found a sizeable amount of low quality literature which dramatically reduced our capability to draw conclusions on the diagnostic accuracy of the wireless capsule for endoscopy. Most studies had faulty design and faulty reporting. The typical sequential study design used by the majority of researchers in which the same patient underwent the WCE procedure and the reference standard, introduced a notable element of time bias into the observation period. As angiodysplasia and other variable morphology lesions were the most diagnosed and often the most frequent indications for use of the WCE, the capability of comparing like with like (i.e. of having the same probability that similar patients had lesions of roughly the same appearance and evolution stage) would have been the basic pre-requisite for a meaningful comparison. Such comparability can only be achieved by a randomised design in which a set of people are given an equal chance of being assigned to the WCE procedure or its comparator so that all differences between participants are balanced and results are comparable. This is the reason why the trial by De Leusse et al¹⁸ is the only credible piece of evidence at our disposal, however small its denominator. The majority of researchers justified the choice of study design with the idea that each patient provided his or her own control, thus minimising the effect of confounders. Far from this being the case, in rapidly evolving lesions the time bias present in the sequential design used maximised the effects of confounding making images from the same patient non-comparable in the majority of cases. Respondents to our questionnaire appeared not to have understood the basic requirement to compare like with like. In addition some experts expressed the view that conducting a clinical trial of such a dominant and safe device as the WCE would be unethical. This view is particularly dangerous because as we have shown the WCE has not been tested in sufficient numbers against a comparator allowing visualisation of the entire small bowel mucosa (i.e. double balloon enteroscopy with double access or intraoperative enteroscopy). The De Lusse et al¹⁸ study was correctly designed (i.e. the methods used could answer the study objectives). However its results should be interpreted with caution. The trial is small (78 participants) highly contextualised and the authors draw conclusions not based on the finding of superior diagnostic accuracy but on the better tolerability of the WCE compared to PE.

Overall other problems with the rationale, design and reporting of the studies further weakened the validity of our evidence base. Few studies clearly stated the rationale for the choice of comparator and some even reported a "cross over" design, mistaking it for the sequential design actually used. Twenty nine percent of included studies with a sequential design failed to report the time interval between one procedure and the other and few reported funding source and/or contained an authors' conflicts of interest statement. The WCE seems to be better tolerated than a range of other procedures and our patient questionnaire results confirm this view. The WCE is not however free from harms and in 1% of cases its use and retention led to a major surgical procedure such as laparotomy for removal being carried out or in an anxious wait for the expulsion of a retained capsule. Few studies reported harms due to their small size, so our survey may provide the first reliable estimates of their incidence. In addition a thorough preparation of the patient and correct use of the WCE are necessary as shown by the high proportion of failures or of incomplete procedures (nearly 15% of those carried out in the 56 responding centres in 2006).

Our safety dataset of over two thousand observations is to our knowledge the largest in existence from a single nation although we are aware of large international case series (such as the one comprising 733 cases reported by Rondonotti et al⁴⁴).

Our data do not support the view that technical failures were more common in the earlier stages of WCE use, although we used date of publication as a proxy for date of execution of the study and of device type.

Our enquiries on the use of the WCE in the Italian context paint a varied picture with peaks and troughs of use probably unrelated to clinical need and some frankly disturbing indications for its use. For example a biopsy is necessary in all cases to make a definitive diagnosis in coeliac disease and its ethical use in situations of high likelihood of intestinal stenosis such as Crohn's disease is debatable. The enthusiasm of a few centres far outstrips the evidence base on which the appropriate use of the WCE procedure should take place. Variability of use is also reflected in the variability of costs which persist even after adjustment for the optional configuration of the WCE set. The WCE in Italy is an expensive procedure, but we cannot say whether it is cost-effective if compared to the alternatives available in 2006 or likely to be cost-effective compared to the current alternatives, as we lack clear evidence to guide indications and unbiased evidence of its comparative performance. Our evidence shows that centres in which the highest numbers of procedures are carried out have the lowest costs. This however should not be interpreted as a reason to increase WCE use in the absence of credible evidence of diagnostic accuracy.

8. Recommendations

Given the present and future development of the technology a reasonable way forward may be to link reimbursement of the WCE to its use in adequately designed and powered randomised controlled trials with a potential crossover design similar to that of the De Leusse et al trial¹⁸. These should test the performance of the WCE for present and future indications under the supervision of scientific and ethical committees. We further recommend that this process (called coverage with evidence generation), widely adopted abroad should be adopted in Italy for all promising new technologies.

9. Funding

Production of this report was made possible by financial contributions from the Italian Ministry of Health (CUD, Commissione Unica Dispositivi) and the Age.Na.S.

The Age.Na.S. takes sole responsibility for the final form and content of this report. The views expressed herein do not necessarily represent the views of the Italian Ministry of Health or any regional government.

10. Competing interests declaration

The authors declare that they will not receive either benefits or harms from the publication of this report. None of the authors have or have held shares, consultancies or personal relationships with any of the producers of the devices assessed in this document.

Glossary

Coeliac Disease (COD)

COD is a disease occurring in children and adults characterized by sensitivity to gluten, with chronic inflammation and atrophy of the mucosa of the upper small intestine; manifestations include diarrhoea, malabsorption, steatorrhea, nutritional and vitamin deficiencies, and failure to thrive, or short stature.

Cochrane Library (CLIB)

A collection of databases, published on disk, CD-ROM and the Internet and updated quarterly, containing the Cochrane Database of Systematic Reviews, the Cochrane Controlled Trials Register, the Database of Abstracts of Reviews of Effectiveness, the Cochrane Review Methodology Database, and information about the Cochrane Collaboration and other information.

Cochrane Review

A Cochrane Review is a systematic, up-to-date summary of reliable evidence of the benefits and risks of healthcare. Cochrane Reviews are intended to help people make practical decisions. For a review to be called a "Cochrane Review" it must be in the Parent Database maintained by the Cochrane Collaboration. The Parent Database is composed of modules of reviews submitted by Collaborative Review Groups (CRGs) registered with the Cochrane Collaboration. The reviews contributed to one of the modules making up the Parent Database are refereed by the editorial team of the CRG, as described in the CRG module. Reviewers adhere to guidelines published in the Cochrane Reviewers' Handbook.

Cost

A negative variation in utility.

Crohn's Disease

Crohn's Disease (CD) is a subacute chronic enteritis, of unknown cause, involving the terminal ileum and less frequently other parts of the gastrointestinal tract; characterised by patchy deep ulcers that may cause fistulas, and narrowing and thickening of the bowel by fibrosis and lymphocytic infiltration, with non caseating tuberculoid granulomas that also may be found in regional lymph nodes.

Decision Tree

Decision tree is a basic decision making tool used when in need of analysing a clinical problem with an underlining time and logic structure. The structure of the tree illustrates the three struc-

tural components: alternative actions that the decision maker can take; events that result from a specific decision and the influences on such actions (i.e. clinical information obtained or resulting clinical outcomes); patient outcomes connected to each possible action scenario.

Direct cost

A cost entirely related to the product, activity or service provided by the cost evaluation program. These costs can be allocated to a specific cost centre only if they can be directly attributed to the specified cost centre.

Discount rate

Discounting describes a method that calculates how much one euro is worth today if paid after one or more years.

78



Economic Evaluation

A comparative analysis of costs and outcomes of several alternative actions. Therefore the main function of such evaluation is to identify, measure, assign values and compare costs and outcomes of examined alternatives.

Fixed cost

Fixed cost is a cost that does not vary with the activity level. It is relatively stable and it is usually expressed in the units of time (usually as annual cost) rather than units of volume.

Incremental cost

Incremental cost is the cost necessary to increase the total production. It indicates the difference in terms of cost or effect, between two or more evaluated programs or treatments.

Indirect cost

Is the value that cannot be directly traced back to a specific activity, service or product used in the program.

Likelihood Ratios

1. Positive Diagnostic Likelihood Ratios

Diagnostic likelihood ratios (DLR), can be a valuable tool for comparing the accuracy of several tests to the gold standard, and they are not dependent upon the prevalence of disease.

The positive DLR represents the odds ratio that a positive test result will be observed in an infected population compared to the odds that the same result will be observed among a non infected population.

2. *Negative Diagnostic Likelihood Ratios*

The negative DLR represents the odds ratio that a negative test result will be observed in an infected population compared to the odds that the same result will be observed among a non infected population.

Mean cost

The mean cost for one unit of product is the total cost of N units of product divided by N.

Meta Analysis

Meta analysis uses statistical methods to combine and integrate results from a number of previous experiments or studies examining the same question, in an attempt to summarise the totality of evidence relating to a particular issue. This combination will produce a more robust conclusion than the one obtained in a single study.

Obscure bleeding

Recurrent or persistent IDA, positive FOBT, or visible bleeding with no bleeding source found at original endoscopy

Obscure occult bleeding

Subcategory of obscure bleeding characterised by recurrent or persistent IDA and/or positive FOBT with no source found at original endoscopy; no visible blood in faeces.

Obscure overt bleeding

Subcategory of obscure bleeding characterised by recurrent or persistent overt/visible bleeding with no source found at original endoscopy; bleeding manifest as visible blood in emesis or faeces.

Occult bleeding

Initial presentation of IDA and/or positive FOBT; no visible blood in faeces

Odds ratio (OR)

Both the odds ratio and the relative risk compare the likelihood of an event between two groups.

Overt or visible bleeding

Gastrointestinal bleeding manifest as visible bright red or altered blood in emesis or faeces

Outcome

Outcome is used to indicate results and value of a health intervention. Mortality and similar units are often used as outcome measurements to evaluate the effect on a population or a health care system. In other cases outcome is the result of a specific diagnostic or therapeutic procedure.

Relative risk (RR)

In statistics and mathematical epidemiology, relative risk (RR) is the risk of an event (or of developing a disease) relative to exposure. Relative risk is a ratio of the probability of the event occurring in the exposed group versus the control (non-exposed) group.

Sensitivity analysis

An analysis used to determine how sensitive the results of a study or systematic review are to changes in how it was done. Sensitivity analyses are used to assess how robust the results are to uncertain decisions or assumptions about the data and the methods that were used.

Sensitivity

The sensitivity of a test is the probability that the test is positive when given to a group of patients with the disease. Sensitivity is sometimes abbreviated Sn.

A large sensitivity means that a negative test can rule out the disease. David Sackett coined the acronym "SnNOuT" to help us remember this.

Specificity

The specificity of a test is the probability that the test will be negative among patients who do not have the disease. Specificity is sometimes abbreviated Sp.

A large specificity means that a positive test can rule in the disease. David Sackett coined the acronym "SpPIIn" to help us remember this.

Positive predictive value

The positive predictive value of a test is the probability that the patient has the disease when restricted to those patients who test positive. This term is sometimes abbreviated as PPV.

If the prevalence of the disease in your situation is different from the prevalence of the disease in the research study you are examining, then you can use likelihood ratios to estimate the PPV.

Negative predictive value

The negative predictive value of a test is the probability that the patient will not have the disease when restricted to all patients who test negative.

If the prevalence of the disease in your situation is different from the prevalence of the disease in the research study you are examining, then you can use likelihood ratios to estimate the NPV.

Time Preference for Health test:

This unit indicates the social discount rate at which decision makers exchange the present with future consumptions. This parameter is often approximated with the real interest rate (net inflation rate) of state bonds.

Abbreviations

AGA	American Gastroenterology Association
CCOHTA	Canadian Coordinating Office of Health Technology
CD	Crohn's Disease
COD	Coeliac Disease
CS	Colonoscopy
CT	Computer Tomography
CRD	Centre for Reviews and Dissemination
DBE	Double Balloon Enteroscopy
EGD	Esophago Gastro Duodenoscopy
FAP	Familial Adenomatous Polyposis
FDA	Food and Drug Administration
FOBT	Faecal Occult Blood Test
HTA	Health Technology Assessment
KCE	Centre Fédéral d'Expertise de soins de Santé
IE	Intraoperative Enteroscopy
MRI	Magnetic Resonance Imaging
NICE	National Institute for Clinical Excellence (UK)
NDDIC	National Digestive Diseases Information Clearinghouse
OGIB	Obscure Gastrointestinal Bleeding
PE	Push Enteroscopy

SBS	Small Bowel Series
SBTS	Small bowel follow through
SI	Small Intestine
SR	Systematic Review
WCE	Video Capsule Endoscopy

Bibliography

1. Mayers RT, *Diagnosis and Management of occult gastrointestinal bleeding: visualization of the small bowel lumen by fiberoptic colonoscope*, American Surgeon, 1976;42(2):92-95.
2. Zuckerman GR, Prakash C, Askin MP, Lewis BS. AGA technical review on the evaluation and management of occult and obscure gastrointestinal bleeding. *Gastroenterology* 1999;118:201221.
3. American Gastroenterological Association (AGA) Institute Technical Review on Obscure Gastrointestinal Bleeding. *Gastroenterology* 2007;133:1697-1717.
4. Lewis BS, Small Intestinal Bleed. *Gastroenterology Clinics of North America*, 1994;23(1):67-91.
5. Stedman medical dictionary, 2008. www.stedman.com accessed on the 7th April 2008
6. Schivanada S, Lennard-Jones J, Logan R et al. *Incidence of inflammatory bowel disease across Europe: is there a difference between north and south? Results of the European Collaborative Study on Inflammatory Bowel Disease (EC-IBD)* *Gut* 1996;39:690-697.
7. National Digestive Diseases Information Clearinghouse (<http://digestive.niddk.nih.gov/>) accessed on the 7th April 2008
8. Genetics Home Reference (<http://ghr.nlm.nih.gov>) accessed on the 7th April 2008
9. Orecchia G, Oral communication at 2° CONGRESSO NAZIONALE sulla Videoendoscopia - Second Italian Congress on WCE - 28-30 June 2007, Feltre (Italy).
10. MSAC. M2A(R) capsule endoscopy for the evaluation of obscure gastrointestinal bleeding in adult patients. Medical Services Advisory Committee 2003 (MSAC Application 1507), 2003;159.
11. NICE Wireless capsule endoscopy. For investigation of the small bowel. National Institute for Clinical Excellence (NICE) Interventional Procedure Guidance 101.2004. Available from www.nice.org.uk
12. KCE Endoscopie par capsule, Centre Federal d'Expertise des Soins de Santé, 2006;25B
13. Mylonaki M, Fritscher A, Swain P, Wireless capsule endoscopy: a comparison with push enteroscopy in patients with gastroscopy and colonoscopy negative gastrointestinal bleeding. *Gut*. 2003; 52:1122-1126
14. Mata A, Bordas M, Feu F, et al, Wireless capsule endoscopy in patients with obscure gastrointestinal bleeding: a comparative study with push enteroscopy, *Aliment Pharmacol Ther*, 2004;20:189-194.
15. Adler DG, Knipschild M, Cristopher G, A prospective comparison of capsule endoscopy and push enteroscopy in patients with GI bleeding of obscure origin. *Gastrointestinal Endoscopy*, 2004;59(4):492-498.

16. Saurin JC, Delvaux M, et al, *Clinical impact of Capsule Endoscopy Compared to Push Enteroscopy: 1 year follow up study*. Endoscopy 2005;37:318-323.
17. Neu B, Ell C, May A, Schmid E, et al. *Capsule endoscopy versus standard tests in influencing management of obscure digestive bleeding: Results from a German multicentre trial*. Am. J. Gastroenterol. 2005; 100(8):1736-1742; ISSN: 0002-9270.
18. De Leusse A, Vahedi K, Edery J, et al. *Capsule endoscopy or push enteroscopy for first-line exploration of obscure gastrointestinal bleeding?* eng. Gastroenterology. 2007; 132(3):855-62; quiz 1164-5; ISSN: 0016-5085
19. Matsumoto T, Esaki M, Moriyama T, et al. *Comparison of capsule endoscopy and enteroscopy with the double-balloon method in patients with obscure bleeding and polyposis*. eng. Endoscopy. 2005; 37(9):827-32; ISSN: 0013-726X.
20. Hadithi M, Heine GD, Jacobs MA, et al. *A prospective study comparing Wireless Capsule Endoscopy with double-balloon enteroscopy in patients with obscure gastrointestinal bleeding*, eng. Am J Gastroenterol. 2006; 101(1):52-7; ISSN: 0002
21. Nakamura M, Niwa Y, Miyahara R, et al. *Preliminary comparison of capsule endoscopy and double-balloon enteroscopy in patients with suspected small-bowel bleeding*. Endoscopy. 2006; 38(1):59-66; ISSN: 0013-726X.
22. Gay G, Delvaux M and Fassler I, *Outcome of capsule endoscopy in determining indication and route for push-and-pull enteroscopy*, eng. Endoscopy. 2006; 38(1):49-58; ISSN: 0013-726X
23. Xiao-Bo L, ZZ G, Dai J, et al., *The role of capsule endoscopy combined with double-balloon enteroscopy in diagnosis of small bowel diseases*, eng. Chin Med J (Engl). 2007; 120(1):30-5; ISSN: 0366-6999.
24. Ell C, Remke S, May A, et al. *The first prospective controlled trial comparing wireless capsule endoscopy with push enteroscopy in chronic gastrointestinal bleeding*. Endoscopy 2002;34:685689.
25. Costamagna G, Shah S, Riccioni ME, et al, *A prospective trial comparing small bowel radiographs and Wireless Capsule Endoscopy for suspected small bowel disease*. Gastroenterology 2002;123:999-1005.
26. Hara AK, Leighton AJ, Sharma VK, Fleischer DE, *Small Bowel: preliminary comparison of capsule endoscopy with barium study and CT*, Radiology, 2003;230(1):260-265.
27. Golder SK, Schreyer AG, Endlicher E, et al. *Comparison of capsule endoscopy and magnetic resonance (MR) enteroclysis in suspected small bowel disease*. eng. Int J Colorectal Dis. 2006; 21(2):97-104; ISSN: 0179-1958.
28. Saperas E, Dot J, Videla S, et al. *Capsule endoscopy versus computed tomographic or standard angiography for the diagnosis of obscure gastrointestinal bleeding*, eng. Am J Gastroenterol. 2007 Apr.
29. Altman DG, Schulz KF, Moher D, et al, *The revised CONSORT statement for reporting randomized trials: explanation and elaboration*. Ann Intern Med 2001;134:663694.

30. Albert JG, Martiny F, et al. *Diagnosis of small bowel Crohn's disease: a prospective comparison of capsule endoscopy with magnetic resonance imaging and fluoroscopic enteroclysis.* Gut 2005;54:1721-1727.
31. Buchman AL, Miller FH, Wallin A, et al. *Videocapsule Endoscopy versus Barium Contrast Studies for Diagnosis of CDRecurrence Involving the Small Intestine.* American Journal of Gastroenterology, 2004;99:2171-2177.
32. Eliakim R, Suissa A, Yassin K, et al. *Wireless capsule video endoscopy compared to barium follow-through and computerised tomography in patients with suspected Crohn's Disease final report.* Digestive and liver disease, 2004;36:519-522
33. Ho Chong AK, Taylor A, Miller A, et al. *Capsule endoscopy vs. push enteroscopy and enteroclysis in suspected small-bowel Crohn's disease.* Gastrointest. Endosc. 2005; 61(2):255-261; ISSN: 0016-5107.
34. Voderholzer WA, Beinhoelzl J, Rogalla P, et al. *Small bowel involvement in Crohn's disease: a prospective comparison of wireless capsule endoscopy and computed tomography enteroclysis.* eng. Gut. 2005; 54(3):369-73; ISSN: 0017-5749.
35. Caspari R, Falkenhausen M, Krautmacher C, et al. *Comparison of Capsule Endoscopy and Magnetic Resonance Imaging for the detection of polyps of the small intestine in patients with familial adenomatous polyposis or with peutz-jeghers' syndrome.* Endoscopy 2004;36:1054-1059.
36. Schulmann K, Hollerbach S, Kraus K, *Feasibility and Diagnostic Utility of Wireless Capsule Endoscopy for the Detection of Small Bowel Polyps in Patients with Hereditary Polyposis Syndromes,* American Journal Gastroenterol, 2005;100:27-37.
37. Wong RF, Tuteja AK, Haslem DS, et al. *Wireless Capsule Endoscopy compared with standard endoscopy for the evaluation of small-bowel polyps in persons with familial adenomatous polyposis (with video.* eng. Gastrointest Endosc. 2006; 64(4):530-7; ISSN: 0016-5107.
38. Marmo R, Rotondano G, Piscopo R, et al. *Meta-analysis: Capsule enteroscopy vs. conventional modalities in diagnosis of small bowel diseases.* Aliment. Pharmacol. Ther. 2005; 22(7):595-604; ISSN: 0269-2813.
39. Hartmann D, Schmidt H, Bolz G, et al. *A prospective two-centre study comparing wireless capsule endoscopy with intraoperative enteroscopy in patients with obscure GI bleeding,* eng. Gastrointest Endosc. 2005; 61(7):826-32; ISSN: 0016-5107.
40. Mother D, Cook DJ, Eastwood S, et al. *Improving the quality of reports of meta-analyses of randomised controlled trial: the QUORUM statement. Quality of reporting of metaanalyses.* Lancet 1999; 354:1896-1900.
41. Triester SL, Leighton JA, Leontiadis GI, et al. *A meta-analysis of the yield of capsule endoscopy compared to other diagnostic modalities in patients with obscure gastrointestinal bleeding.* Am. J. Gastroenterol. 2005; 100(11):2407-2418; ISSN: 0002-9270.
42. Van Gossum A, Hittelet A, Schmit A, et al. *A prospective comparative study of push and wireless-capsule enteroscopy in patients with obscure digestive bleeding.* Acta Gastro-enterologica Belgica, 2003;66:199-205.

43. Norman M. Dy, Gostout CJ, Balm RK. *Bleeding from the Endoscopically-identified Dieulafoy Lesion of the proximal small intestine and colon.* Am. J. Gastroenterol. 1995; 90(1):108-111; ISSN: 0002-9270.
44. Rondonotti E, Herrerias JM, Pennazio M et al. *Complications, limitations, and failures of capsule endoscopy: a review of 733 cases.* Gastrointest. Endosc. 2005; 62:712-716.

Appendix 1

Expert Opinion Questionnaire Wireless Capsule Endoscopy (WCE)

1) How many OGIB cases require the use of WCE?

- 0%
- 1%
- 2%
- 3%
- 4%
- 5%
- 6%
- 7%
- 8%
- 9%
- 10%

Other (define):

2) Which is the best diagnostic alternative to the WCE?

- Double Baloon Enteroscopy
- Push Enteroscopy
- Small Bowel RX
- Computer Tomography (CT)
- Magnetic Resonance Imaging (MRI)

Other (define):

Questionnaire results

Figure 1. Expert's opinion percentage of OGIB cases requiring a WCE after negative endoscopies

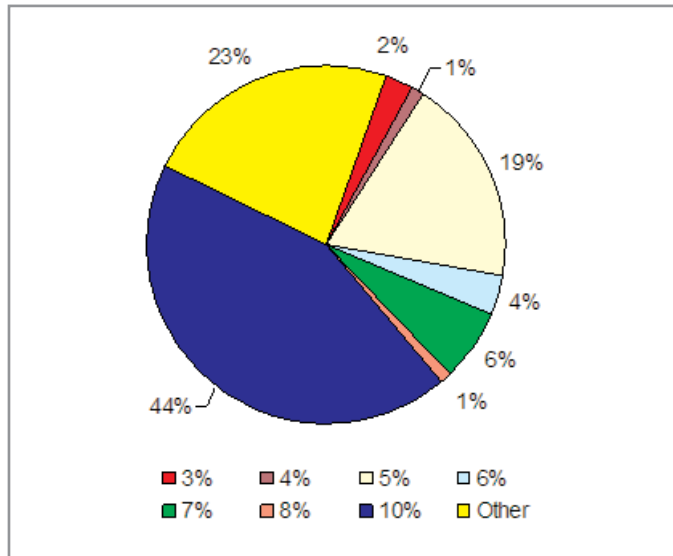
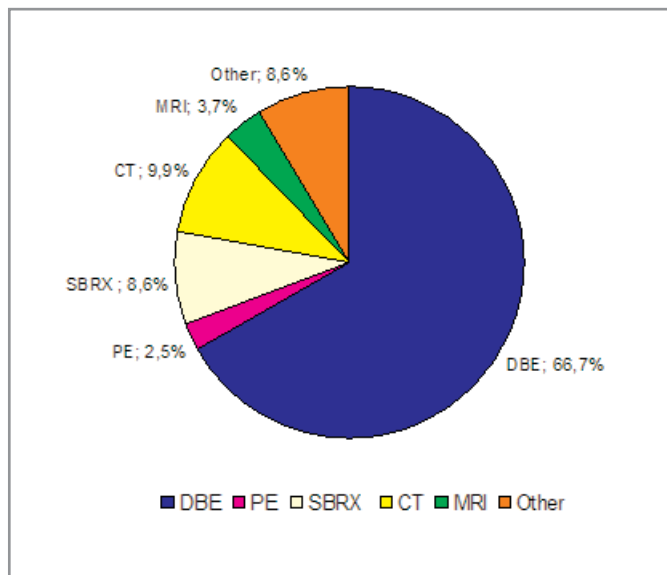


Figure 2. Diagnostic alternatives* to the WCE (n=82)



* SBRX= Small Bowel RX; PE= Push Enteroscopy; DBE=Double Ballon Enteroscopy; MRI=Magnetic Risonance Imaging; CT= Computer Tomography; Other= Scintigraphy, Arteriography, Angiography

Appendix 2a

Wireless capsule endoscopy (WCE)

Miniaturisation represents a continuing trend in technology toward ever-smaller scales for mechanical, optical and electronic devices. In the industry of medical devices this trend has carried out a variety of diagnostic and therapeutic procedures that are less invasive than only few years ago. In the field of endoscopy, miniaturisation means that, theoretically, even the deepest cavity of the body is reachable without difficulty.

A key-point is surely represented by the image sensors which have to be embedded on the tip of the endoscope for acquire the images that will be transmitted to the monitor outside the body. An image sensor is a device that converts a visual image (light) to an electric signal. The smaller the sensor the smaller the tip of the endoscope and thus less invasive will be the procedure.

In this field the CCD images sensor and the CMOS sensor are the most used technologies. Both types of sensor accomplish the same task of capturing light and converting it into electrical signals.

- CCD (Charge-Coupled Device): every pixel's charge is transferred through a very limited number of output nodes (often just one) to be converted to voltage, buffered, and sent off-chip as an analogical signal.
- CMOS (Complementary Metal-Oxide-Semiconductor): each pixel has its own charge-to-voltage conversion, and the sensor often also includes amplifiers, noise-correction, and digitisation circuits, so that the chip outputs digital bits. These other functions increase the design complexity and reduce the area available for light capture.

Both CCDs and CMOS imagers can offer excellent imaging performance.

CCDs offer good image quality and flexibility at the expense of system size. They remain the most suitable technology for high-end imaging applications, such as digital photography, broadcast television, high-performance industrial imaging, and most scientific and medical applications (Litwiller 2001).

CMOS imagers offer small system size at the expense of image quality (particularly in low light) and flexibility. They are the technology of choice for high-volume, space constrained applications where image quality requirements are low. This makes them a natural fit for security cameras, PC videoconferencing, wireless handheld device videoconferencing, bar-code scanners, fax machines, consumer scanners, toys, biometrics and some automotive in-vehicle uses (Litwiller 2001).

Wireless Capsules for Endoscopy (WCE)

WCE is also known as Video-Capsule for Endoscopy (VCE), capsule camera, video pill, or capsule endoscopy. It consists in a camera with the size and shape of a large pill used to acquire images of the gastrointestinal tract.

At the present time, the capsule camera is primarily used to visualise the small bowel (from the jejunum to ileum). Unlike the upper gastrointestinal tract (esophagus, stomach, and duodenum) and the colon (large intestine), that can be very adequately visualised with endoscopes, the small bowel is very long (more than 5 meters), very convoluted and thus hardly observable with endoscopes.

WCE represent a monumental advance in the diagnosis of small bowel diseases but at the moment biopsies and endoscopic interventions are not possible.

Operating principle of video-capsules for endoscopy

Although there are 2 different devices available on the market, the principle of operation of the endoscopic capsule is quite similar (at a first sight, the only difference seem to be the image sensor). Due to its mini-invasivity, this technology seems to be very promising and for this reason, the two manufacturers were involved in a long and very expensive patent litigation settled in April 2008. Under the terms, Olympus will pay Given Imaging Ltd. \$ 2.3 million. The companies will cross licence existing patents to each other without royalty payments and have agreed to work out royalty payments for future patents (marketwatch website).

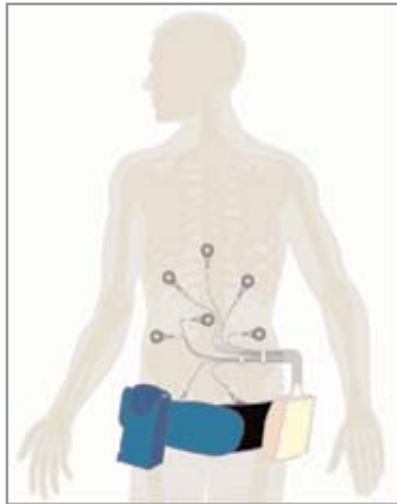
The two devices are the size of a large pill, and are composed by:

- one or more batteries;
- a strong light source (light-emitting diodes, LED);
- an image sensor;
- a small transmitter.

Once swallowed, the capsule begins transmitting images (for about 8 hours) of the inside of the gastrointestinal tube. Sensors are attached to the patient's abdomen and wired to a portable recorder. The recorder is battery-operated and is composed of a receiver, a processor, and a hard disk to store the images. These video images are transmitted by means of ultra-high-frequency radio telemetry to the sensor array, which subsequently sends the data to the recorder (Figure A2.1).

After some hours the patient returns the belt to the physician who loads the information into a computer and then can review in detail the pictures of the intestine, looking for abnormalities. Image interpretation takes from 30 minutes to 2 hours, depending on experience, but is typically one hour (Hara 2005). The capsule is disposable, propelled by peristalsis and excreted after 24-48 hours.

Figure A2.1: Sensors attached to the abdomen along with the battery pack and recorder



State of the Art

Two companies share the worldwide market for this technology:

- Given Imaging Ltd. with its PillCam SB;
- Olympus Corporation with its EndoCapsule;

PillCam SB (Given Imaging Ltd.)

The first capsule endoscope in the worldwide market was the M2A capsule by Given Imaging Ltd. M2A received approval from the U.S. Food and Drug Administration (FDA) and permission to affix the CE mark in 2001. In 2005, Given Imaging Ltd. brought the second generation capsule endoscope to the market (PillCam SB) with some new features like the real-time view system. PillCam SB consists of: a capsule "endoscope", an external receiving antenna with attached portable hard-drive, and a customised PC workstation with a dedicated software for reviewing and interpretation of images. The capsule weighs 3.7 grams and measures 11 mm in diameter x 26 mm in length (Figure A2.2). It includes a CMOS chip camera of 256x256 pixels, a short focal length lens, 4 to 6 white LED, two silver oxide batteries, and a UHF band radio telemetry transmitter. Image features include a 140° field of view, 1:8 magnification, 1 to 30 mm depth of view, and a minimum size of detection of about 0.1 mm. The activated capsule provides images at a frequency of 2 frames per second until the battery expires after 7±1 hours, which enables the device to take up to 55,000 images in jpg format (Figure A2.3) (Shelat 2006).

From the end of 2007 a newer version of PillCam SB is on the market: PillCam SB2. The main improvements consist of a better lens system, and a wider field of view (156° instead of 140°). (Given website). One of the concerns in the WCE procedure is the capsule retention that may occur when strictures of the lumen are present. To assess the patency of the gastro-intestinal tract, Given Imaging Ltd. has developed the Agile Patency System. This system consists of a radio-

frequency scanner and a test capsule having the same dimensions of the PillCam. The test capsule is swallowed prior to administration of the diagnostic capsule and consists of a dissolvable body containing a radio-frequency identification tag. If strictures are present, the retained test capsule will dissolve in about 30 hours.

Figure A2.2: PillCam SB (Given Imaging Ltd.)

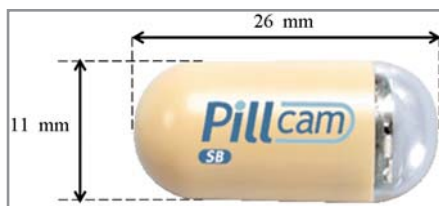
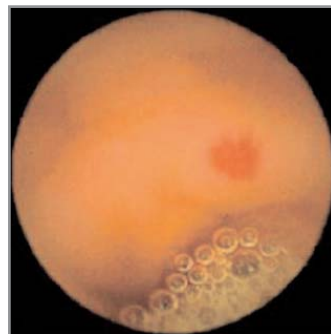

Figure A2.3: Example image with PillCam SB (angiodysplasia of the small bowel from Hartmann 2007)



EndoCapsule (Olympus Corporation)

Olympus Medical Systems has recently (2007) developed a capsule endoscope (EndoCapsule, EC type 1) that uses a different image sensor with electronic enhancement of image quality. The capsule is the same size as the PillCam SB (11 × 26 mm) and produces the same number of images per hour (Figure A2.4) (Olympus website).

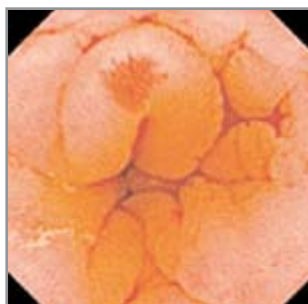In particular, the Olympus WCE system differs from the Given Imaging Ltd. capsule previously described for a high-resolution CCD sensor (Figure A2.5).

The Olympus EndoCapsule software provides a complex antenna consisting of eight antennas combined into one. The antenna receiving the strongest signal is highlighted and serves for the localization of capsule's position in the gastrointestinal tract. The technology is considered imprecise, and locating the position of the capsule in the abdomen is judged considering also checking directly the capsule images during the procedure using the Olympus External Viewer (the mucosal patterns of the jejunum and ileum) (Hartmann 2007).

Figure A2.4: EndoCapsule (Olympus Corp.)



Figure A2.5: Example image with EndoCapsule EC type 1 (angiodysplasia of the small bowel from Hartmann 2007)



The Future

Given have recently presented two new video-capsules, equipped with two imaging device and light source (one at both ends): PillCam ESO and PillCam COLON (Figure A2.6).

The PillCam ESO takes up to 14 images per second, as it passes down the esophagus during the 20-minute procedure. PillCam ESO was developed for patients suffering from esophageal disorders, such as esophageal varices, which can result in fatal bleeding, and Barrett's esophagus, which is an early indication for esophageal cancer. The improved version, PillCam ESO2, was cleared for marketing by U.S. FDA in May 2007. It is the same size as the PillCam ESO video capsule but has a wider angle of view and captures 18 frames per second. The indications for this video capsule are similar to PillCam ESO however, the Company believes that screening for gastroesophageal reflux disease could be possible in the near future.

The PillCam COLON 11 mm × 31 mm (slightly longer than other PillCams) captures 4 images per second during the 10-hour procedure. PillCam COLON was cleared for marketing in the European Union in October 2006 and Israel in February 2008. The video capsule was initially developed to help physician's visualise the colon and is currently being used for patient's that have had an incomplete colonoscopy, for those contraindicated for a colonoscopy or for those who prefer not to have a colonoscopy. Multi-centre clinical trials are underway in Europe (Given website).

Figure A2.6: Given imaging Ltd. products (PillCam ESO, PillCam SB2 and PillCam COLON)



A new-concept device could be available in the next few years. RF System Lab. has declared that their capsule for endoscopy (Sayaka Capsule Camera) will be on the market in 2010. The innovations carried by this device consisting in the ability to change the camera position and enable the camera to rotate. While conventional capsules typically have cameras at one end of the device, Sayaka's camera has been positioned on the side, where it has a lateral view of the intestinal walls. In addition, a tiny stepper motor rotates the camera as the capsule passes through the digestive tract.

Sayaka's power is supplied wirelessly from an external source (and it contains no battery). Photos acquired are sent to a receiver located near the body. Image "mosaicking" technology is then used to combine multiple images taken from various angles into a flat, high-resolution rectangular map of the intestines, which can be magnified up to 75 times. Sayaka is characterised by a double-structured capsule made up of an outer and an inner shell. Whereas the outer capsule traverses through the gastrointestinal tract, the inner capsule alone spins. This spinning is derived by an electromagnet and a small permanent magnet and which causes the "stepping rotation".

Over an 8-hour period procedure, Sayaka will generate approximately 870.000 images of the whole digestive tract at a rate of 30 frames per second. (RFSystem website).

Bibliography

Litwiller D. CCD vs. CMOS: Facts and Fiction; PHOTONICS SPECTRA, January 2001.

<http://www.marketwatch.com> (accessed in July 2008)

Hara AK, Capsule endoscopy: the end of the barium small bowel examination? *Abdom Imaging* 2005;30:179–83.

Shelat V, Shelat G. "Wireless Capsule Endoscopy"; *Journal of Postgraduate Medical Education, Training & Research* Vol. I, No. I & II (2006).

<http://www.givenimaging.com>

http://www.olympusamerica.com/msg_section/endocapsule/index.asp

Hartmann D, Eickhoff A, Damian U, Riemann JF. "Diagnosis of small?bowel pathology using paired capsule endoscopy with two different devices: a randomized study"; *Endoscopy* 2007; 39: 1041-1045.

<http://www.rfamerica.com/sayaka/index.html>

Appendix 2b

Standard technology for diagnosis of bowel diseases

One of the most common symptom imputable to a bowel disease is the obscure gastro-intestinal bleeding (OGIB) defined as “bleeding from the GI tract that persists or recurs without an obvious aetiology after esophagogastroduodenoscopy, colonoscopy, and radiologic evaluation of the small bowel such as small bowel follow-through or enteroclysis” (AGA).

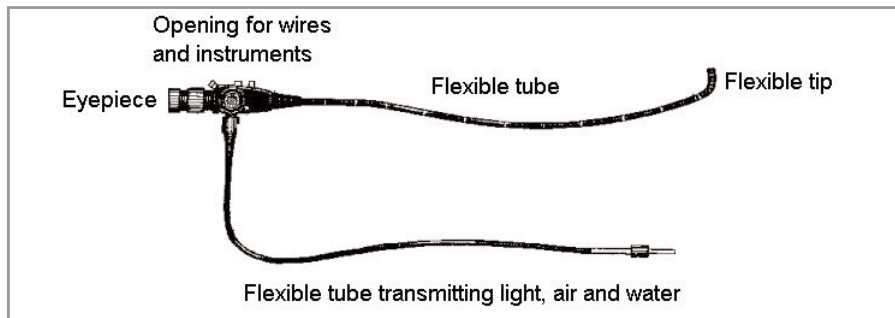
As showed in Table 1, the diagnosis for such conditions is very difficult since a lot of diseases present OGIB.

Table 1: Differential diagnosis of occult gastrointestinal bleeding (OGIB)

Mass lesions	Infectious diseases
Carcinoma (any site)†	Hookworm
Large (>1.5 cm) adenoma (any site)	Whipworm
Inflammation	Strongyloidiasis
Erosive esophagitis†	Ascariasis
Ulcer (any site)†	Tuberculous enterocolitis
Cameron lesions‡	Amebiasis
Erosive gastritis	Surreptitious bleeding
Celiac disease	Hemoptysis
Ulcerative colitis	Oropharyngeal bleeding (including epistaxis)
Crohn’s disease	Other causes
Colitis (nonspecific)	Hemosuccus pancreaticus
Idiopathic cecal ulcer	Hemobilia
Vascular disorders	Long-distance running
Vascular ectasia (any site)†	Factitious cause
Portal hypertensive gastropathy or colopathy	
Watermelon stomach	
Varices (any site)	
Hemangioma	
Dieulafoy’s vascular malformation§	

Notes: †These abnormalities are the most common; ‡These are linear erosions within a hiatus hernia; §This is a large superficial artery underlying a small mucosal defect (Zuckerman 2000).

Figure A2.7: A typical endoscope



Endoscopy is the examination and inspection of the interior of body organs, joints or cavities through flexible tubes called endoscopes. An endoscope uses optical fibres and powerful lens systems to provide lighting and visualisation of the interior of the body. The latest developed devices have an image sensor at the tip instead of the lens system.

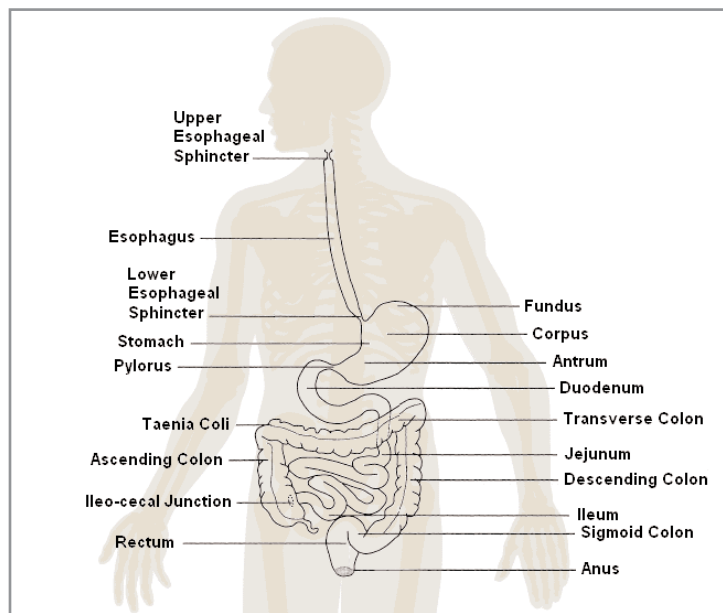
An endoscope can consist of

- a rigid or flexible tube;
- a light delivery system to illuminate the organ or object under inspection (the light source is normally outside the body and the light is typically directed via an optical fibre system);
- a lens system transmitting the image to the viewer from the tip;
- an additional channel to allow entry of medical instruments or manipulators.

Endoscopy is classified as mini-invasive procedure but is not generally well accepted by the patients since it causes pain and discomfort and for this reason different ways to look inside the body have been developed.

Unlike imaging technologies, endoscopy allows the real-time intervention on the tissues being examined by means of distending the tissues, taking samples for biopsy, cleaning, cauterising, etc.

Figure A2.8: Gastro-intestinal apparatus



Push Enteroscopy (PE)

One of the standard procedures for looking inside the bowel is Push Enteroscopy (PE). This practice requires per oral insertion of a long endoscope (usually a dedicated enteroscope or paediatric colonoscope), and allows examination of the distal duodenum and proximal jejunum.


PE has been considered a useful diagnostic procedure for identifying small bowel lesions. However, this procedure is poorly tolerated, technically difficult (often requires deep sedation or anaesthesia, skilled operators and is time-consuming) and it is not free of complications.

Despite substantial improvements to PE in the last 10 years with manufacturers producing longer instruments (240 cm) with high quality video systems and overtubes, these instruments can only examine the upper gastrointestinal tract up to the proximal jejunum.

The procedure is usually done under anaesthesia (general anaesthesia or conscious sedation). The enteroscope is inserted through the mouth, with or without an overtube embedding an inflatable silicone balloon, and thanks to extraction-insertion manoeuvres or using the friction at the interface of the balloon and intestinal wall, it passed into the small bowel.

Due to the anatomical features of gastrointestinal tract, this kind of devices cannot reach all the points of the small bowel and then some "dark areas" cannot be observed (Gómez Rodríguez 2006).

Figure A2.9: Single-balloon enteroscope.



a) endoscope; b) disposable sliding tube; c) assembled device
From Olympus website

Double-balloon enteroscopy (DBE)

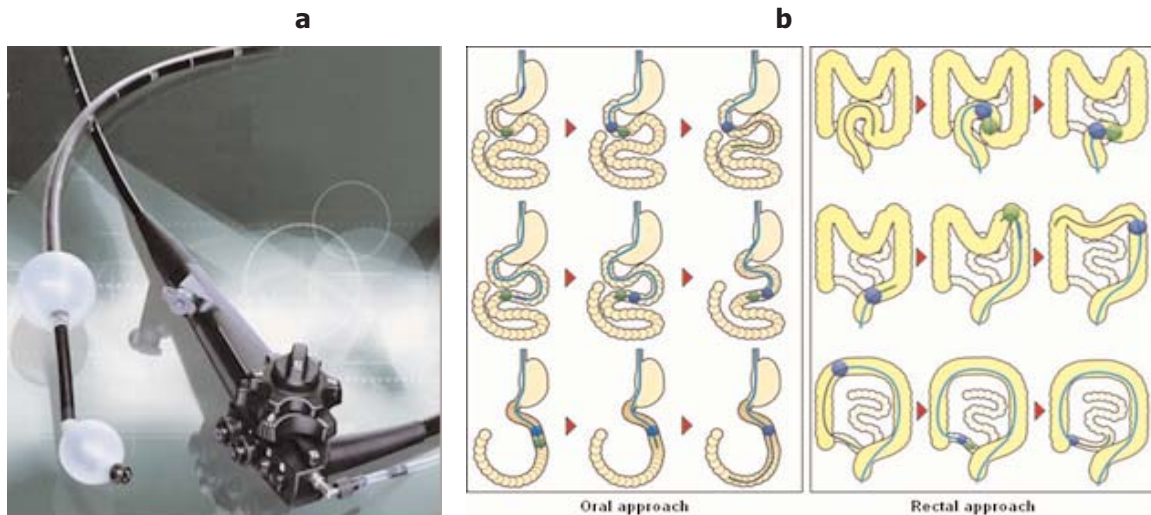
Endoscopic examination of the entire small bowel is technically very difficult. Push enteroscopy is often possible only to the proximal jejunum. In 2001, Yamamoto and Kito developed the double balloon method as an insertion technique for the diagnosis and treatment of small bowel disorders (Yamamoto 2005).

The technique, called Double-Balloon Enteroscopy (DBE) or Push-and-Pull Enteroscopy, involves the use of a special enteroscope and a overtube (a tube that fits over the endoscope). Silicone inflatable balloons are embedded one on the enteroscope and one on the overtube.

The procedure is usually done under anaesthesia (general anaesthesia or conscious sedation). The enteroscope is inserted through the mouth (oral approach) and passed in conventional fashion into the small bowel. Subsequently, the enteroscope is inserted through the rectum (rectal approach) and arrives at the portion of small bowel that is unreachable through the oral route. The examination is performed by advancing the endoscope for small distances in front of the overtube and inflating the balloon at the end. Using the assistance of friction at the interface of the enteroscope and intestinal wall, the small bowel is accorded back to the overtube. The overtube balloon is then deployed, and the enteroscope balloon is deflated. The process is continued until the entire small bowel is visualised.

The main advantage of DBE is the possibility of visualise the entire small bowel to the terminal ileum. The disadvantage of this procedure is patient discomfort and the laborious and time consuming nature of the modality. Further, the procedure should be approached with caution in patients with prior small bowel resections (Mackalski 2006).

Figure A2.10:



a) Double-balloon enteroscope; b) Phases of DBE. **Oral approach:** endoscope and overtube are inserted through the mouth; the balloon on overtube is inflated; the scope is inserted further and the balloon on the scope is inflated; the overtube is advanced along the endoscope; the balloon on overtube is inflated; the balloon on the endoscope is deflated; the scope is inserted further the procedures are repeated and the scope can reach deeper and deeper locations. **Rectal approach:** the same procedure is performed inserting the endoscope through the rectum.

Adapted from www.doubleballoonenteroscopy.com/procedure.html and Fujinon website.

Computer Tomography (CT)

Computer Tomography scanning (CT or CAT, Computer Assisted Tomography) is a non-invasive, painless imaging technique. CT uses special x-ray equipment to produce multiple images of the inside of the body and a computer to join them together in cross-sectional views of the area being studied. CT scans of internal organs, bone, soft tissue and blood vessels provide greater clarity than conventional x-ray exams.

This technology offer better quality images than standard radiography: completely eliminates the superimposition of images of structures outside the area of interest; discriminates between

tissues differing slightly in physical density and processing data from a single CT procedure, axial, coronal, or sagittal planes images can be obtained.

In small bowel examination CT can depict segmental thickening, extraluminal lesions, and complications such as sinus tracts, fistulas, and abscesses. Like magnetic resonance imaging (MRI), CT provides cross sectional imaging of extraintestinal organs, but its radiation (greater than that of small bowel x ray) present a significant disadvantage.

Conventional CT is limited in its assessment of the small bowel because artefacts are produced by collapsed bowel loops and there is no distension of the small bowel.

A relatively new diagnostic tool is CT enteroclysis which combines conventional small bowel enteroclysis with helical CT. The advantage offered by enteroclysis is distension of the small bowel and therefore intraluminal visualisation. The advantage of conventional CT is speed, resolution of volumetric data set, and optimal utilisation of the contrast media.

The disadvantage of CT scan compared with conventional barium studies is the lack of dynamic information (differentiation between peristalsis and skip lesions may be difficult). Compared with MRI, CT has greater availability, is less expensive, and is less time consuming. MRI, however, offers static and dynamic imaging capabilities (MacKalski).

CT is regarded as a moderate to high radiation diagnostic technique. While technical advances have improved radiation efficiency, there has been simultaneous pressure to obtain higher-resolution imaging and use more complex scan techniques, both of which require higher doses of radiation. The radiation dose for a particular study depends on multiple factors: volume scanned, patient build, number and type of scan sequences, and desired resolution and image quality. CT scans of children have been estimated to produce non-negligible increases in the probability of lifetime cancer mortality leading to calls for the use of reduced current settings for CT scans of children.

Magnetic Resonance Imaging (MRI)

Unlike conventional x-ray examinations and CT scans, MRI does not depend on radiation. Instead, radio waves are directed at hydrogen atoms, in a strong magnetic field.

As the patient lies inside the MRI unit, radio waves are directed at the hydrogen atoms in the area of his body being studied. In the magnetic field, these atoms, produce signals that are detected by the coils. A computer processes the signals and generates a series of images each of which shows a thin slice of the body. The computer provides three-dimensional representation of the body, which can be studied from many different angles on a computer monitor.

Since radio waves have effects on the hydrogen atoms, MR images can show differences in water content between various body tissues. As a result, MRI is especially suited to detecting disorders that increase fluid in diseased areas of the body, for example, areas affected by tumours, infection and inflammation. Overall, the differentiation of abnormal (diseased) tissue from normal tissues is significantly easier with MRI than with other imaging modalities such as x-ray, CT and ultrasound.

Although the strong magnetic field is not harmful in itself, medical devices that contain metal may malfunction or cause problems during an MRI exam.

Historically, intestinal assessment with MRI was suboptimal as slow sequences caused respiratory and peristaltic artefacts. Faster pulse sequences are now routinely used and allow both breath-held and breathing independent images with no physiological artefacts. Luminal distension with oral contrast material provides assessment of the bowel wall and its thickness and regularity.

MRI is a potentially ideal imaging modality for patients with Crohn's disease who require repeated cross sectional imaging. Lack of ionising radiation, particularly in patients of reproductive age, is appealing. It is safe in pregnancy and in patients with renal failure, it is helpful in patients with equivocal findings by other imaging modalities. The greatest advantage is the ability to identify active inflammation and distinguish whether obstructions are from fibrotic strictures, adhesions, or active inflammation. Patients with small bowel obstruction can be examined with a minimally invasive approach (no intravenous contrast required) (MacKalski 2006).

Small Bowel Series (SBS) or Small Bowel follow-Through (SBTS)

STS or SBTS is an x-ray exam of the small intestine. This procedure requires that the patient swallows a radio-opaque contrast medium, usually barium sulphate, in various positions on the x-ray table while the radiologist uses a fluoroscope connected to a monitor for acquire x-ray images usually every 20 to 30 minutes (this exam often takes 2 hours or more to complete). Because fluoroscopy involves the use of x-rays all fluoroscopic procedures pose a potential health risk to the patient. Radiation doses to the patient depend greatly on the size of the patient as well as length of the procedure. More modern improvements in technology have allowed for increased image quality while minimizing the radiation dose to the patient (Hara 2005).

Enteroclysis

Enteroclysis is a minimally invasive radiographic procedure of the small intestine, which requires the introduction of a catheter into the small intestine followed by the injection of barium and methylcellulose. The catheter is passed from the nose or mouth through the stomach and into part of the small bowel and injects the barium which coats the intestine and the methylcellulose which distends the lumen allowing real-time fluoroscopic visualization of the entire small bowel. There are several different types of enteroclysis catheters available, and the choice is usually determined by radiologists' preference, but cost can also be a factor in the decision. There are several advantages to having an enteroclysis in comparison to the traditional SBS: this examination is much quicker than a routine SBS and there is an increase in the distension of the lumen, which is very important for tissue characterisation (tissue properties are related to pathological condition).

Nevertheless this procedure presents two main drawbacks: the first and greatest disadvantage is the placement of the catheter, it can be uncomfortable for the patient, even with the use of anaesthetic spray and jelly; The second is that the patient will receive higher doses of radiation in comparison to the traditional SBS exam.

As stated for CT, for what concerns diagnosis of bowel diseases, suboptimal bowel distension and overlapping bowel loops could negatively affect all the radiographic imaging techniques.

Intraoperative Enteroscopy (IE)

IE is usually applied in cases of bleeding that is not localised in spite of extensive diagnostic evaluation and in which the risks of continued bleeding are judged to outweigh the risks of laparotomy. IE can be performed per-orally, trans-nasally, per-rectum, or through single or multiple intestinal incisions. The choice of enteroscope type and entry site will necessarily depend on instrument availability, familiarity with the diagnostic approaches, and the experience and technical expertise of the surgeon and endoscopist.

Esophago-Gastro Duodenoscopy (EGD)

EGD (or upper endoscopy) enables the physician to take inside the oesophagus, stomach, and duodenum (first part of the small intestine).

After an anaesthetic has suppressed the gag reflex, an endoscope is advanced through the oesophagus to the stomach and duodenum. Air is introduced slowly through the endoscope to expand the folds of tissue enhancing view. The internal mucosal surface (lining of the intestines) can be examined and, if the need arises, biopsy samples can be obtained through the endoscope itself. The procedure takes about 30 minutes.

Angiography

Angiography is the x-ray study of the blood vessels. An angiogram uses a radio opaque medium to highlight the blood vessels in a fluoroscopy suite. This examination is usually performed at a hospital, in an x-ray or fluoroscopy suite, by a radiologist and assisting technician or nurse. Angiography requires the injection of a contrast medium that makes the blood vessels visible to x-rays. The patient's vascular system is displayed on a monitor in real-time.

Angiograms can vary depending on the vascular system being studied. For examination of the small bowel, the procedure is called mesenteric angiography and involves x-ray exploration of the celiac and mesenteric arteries, the arterial branches that supply blood to the abdomen and digestive system.

The test is commonly used to detect aneurysm, thrombosis, and signs of ischemia in the celiac and mesenteric arteries, and to locate the source of gastrointestinal bleeding. The procedure can take up to 3 hours, depending on the number of blood vessels studied (Gale Encyclopaedia).

Mesenteric angiography can detect active bleeding but is often considered unsatisfactory and infeasible for the investigation of OGIB because of its highly variable diagnostic yield and risk of complications (Saperas 2007).

Patients with kidney disease or injury may suffer further kidney damage from the contrast mediums used for angiography. Pregnant women are advised to avoid this procedure because x rays carry risks of ionizing radiation exposure to the foetus.

Bibliography

AGA - American Gastroenterological Association, Institute Technical Review on Obscure Gastrointestinal Bleeding. *Gastroenterology* 2007;133:1697–1717

Zuckerman GR, Prakash C, Askin MP, Lewis BS. AGA technical review on the evaluation and management of occult and obscure gastrointestinal bleeding. *Gastroenterology* 2000;118:201-21.

Gómez Rodríguez BJ, Ortiz Moyano C, Romero Castro R, Caunedo Alvarez A, Hernández Durán MD, Hergueta Delgado P, Pellicer Bautista F, Herrerías Gutiérrez J. Diagnostic yield of 335 push videoenteroscopies *Rev Esp Enferm Dig.* 2006;98(2):82-92.

<http://www.olympusamerica.com>

Yamamoto H, Kito H. Double-balloon endoscopy. *Curr Opin Gastroenterol* 2005;21:573–7.

Mackalski BA, Bernstein CN. New diagnostic imaging tools for inflammatory bowel disease. *Gut.* 2006;55(5):733-41.

www.doubleballoonenteroscopy.com/procedure.html

<http://www.fujinonendoscopy.com/default.aspx?pageid=1>

Hara AK, Leighton JA, Sharma VK, et al. Imaging of Small Bowel Disease: Comparison of Capsule Endoscopy, Standard Endoscopy, Barium Examination, and CT RadioGraphics 2005; 25: 697-711.

Gale Encyclopedia of Medicine, Published December, 2002 by the Gale Group.

Saperas E, Dot J, Videla S et al. Capsule endoscopy versus computed tomographic or standard angiography for the diagnosis of obscure gastrointestinal bleeding. *Am J Gastroenterol.* 2007;102(4):731-7.

APPENDIX 3

Search Strategy

EMBASE:

#1. 'capsule endoscopy'/syn OR 'video *1 capsule' OR 'wireless *1 capsule' AND
([cochrane
review]/lim OR [controlled clinical trial]/lim OR [meta analysis]/lim OR [randomized con-
trolled
trial]/lim OR [systematic review]/lim) AND [humans]/lim AND [embase]/lim

PUB MED:

#9 Search "Capsule Endoscopy"[Mesh] OR Video capsule*[Title/Abstract] OR "wireless
capsule"[Title/Abstract]

CL:

video next capsule* in All Text; WCE in Title, Abstract or Keywords; "Capsule
Endoscopy" in Title,

Abstract or Keywords; wireless next capsule* in All Text

Appendix 4

Table A: OGIB_WCE versus PE

Study	Aim	Design	Time range and/or follow up	Participants	OUTCOMES				Comments
					Diagnostic accuracy	Safety*	Acceptability	Conclusions	
Mylonaki M. et al. 2003, UK (London)	To compare efficacy and clinical impact of WCE vs PE in patients with OGIB and negative gastroscopy and colonoscopy. The limitations, technical failures and practical issues of using WCE were explored.	A prospective blinded study. Fifty two patients were enrolled. Two were lost (reasons reported). They all had had colonoscopy and gastroscopy, and most of them had undergone multiple procedures. They had WCE within two weeks before undergoing PE. All gastric abnormalities detected by WCE can be confirmed by PE. The colonic abnormalities were treated with subsequent colonoscopy. WCE was performed and reported by different examiners unaware of the findings of the other examination. Two endoscopists carried out PE and a physician administered WCE and read images. Two reviewers examined all WCE images, and a third endoscopist arbitrated on any discrepancies in the interpretation of findings. A further group of 40 volunteers was also enrolled before the beginning of the study to acquire information on the normal appearance of the small bowel with WCE and PE.	Time range: WCE within 2 weeks before PE. Follow up: two weeks or more (not specified)	Fifty patients (21 male, 29 female), Average age 50.3 (range 17-80). They all had had colonoscopy and gastroscopy, and most of them had undergone multiple procedures. Forty seven were transfused, 15 of them had more than 100 units of blood, 15 more than 400 units.	WCE diagnostic yield in small intestine was 68% (34/50) (angiodyplasia (16), fresh faecal bleeding (8), apt-hous ulceration suggestive of Crohn's disease (3), tumour (2)). The WCE total diagnostic yield was 76% (38/50). The yield of PE in dis-covering the source of obscure bleeding was 32% (16/50). The total diagnostic yield of PE was 38% (19/50).	WCE - TP: in 16 patients the battery expired before caecum (28%); In 3 patients there was a loss of images due to temporary electrical disconnection; In 1 patient the battery expired after 2 hours; - AE: in 1 patient the WCE remained in the oesophagus for 7 hours and was pushed into the stomach by an endoscope. In seven the WCE passed into the pylorus and returned to the stomach before passing in the intestine at least once. In one patient this occurred 7 times. PE - No complications	Method: not clearly reported. At follow up all patients were interviewed and asked to compare WCE and PE painfulness and which was they preferred. Results: WCE was preferred to PE: 49/50; WCE was uncomfortable for swallowing 2/50; PE is painful (34/50; p<0.05).	The authors claim that this study shows that the WCE can provide small intestinal imaging comparable with PE and can diagnose sites of intestinal bleeding beyond the reach of PE. WCE was safe, painless and well tolerated.	This is not a randomised trial, and patients served as their own control. PE is defined as an unfair comparator since it does not reach the lower small intestine.

<p>Mata et al. 2004 Spain (Barcelona)</p>	<p>To examine the diagnostic precision and the clinical efficacy of WCE compared with OGIB and to analyse the impact of WCE findings on the therapeutic approach of OGIB patients.</p>	<p>A prospective study. Forty two consecutive patients with OGIB and normal oesophagogastrroduodenoscopy and colonoscopy were analysed. After WCE all patients underwent PE within the next 7 days. Both techniques were performed "blindly" by separate examiners. The diagnostic yield for each technique was defined as the frequency of detection of clinically relevant intestinal lesions having potential for bleeding.</p>	<p>Time range: PE within a week after WCE. Follow up: not reported</p>	<p>Forty two consecutive patients with OGIB (over bleeding in 26 patients and occult in 16), normal EGD and colonoscopy with ileoscopy. 22 men, 20 women. Mean age 55 years, range 16-84. Data recorded at the moment of inclusion are reported (e.g. haemoglobin, haematocrit, number of blood transfusions). Exclusion criteria reported (pregnancy, pacemaker etc.)</p>	<p>WCE diagnostic yield: (74%) 31/42, (angiodysplasia > fresh blood without lesions) PE diagnostic yield: (19%) 8/42. Successful change in therapeutic approach in 7 patients. Most of the findings detected by WCE were located at distal jejunum and ileum, probably out of reach of the enteroscope.</p>	<p>WCE is non invasive and painless, with a good diagnostic yield in OGIB. It is superior to PE in diagnosing small bowel lesions. If compared with PE, WCE increases the diagnosis yield in patients with OGIB and allows modification on therapy strategy in a high proportion of patients. It led to a change in treatment strategy in 7/31 patients (22%) (with no recurrence at follow up) with positive findings. All patients could be assigned to a specific therapy: 2 with medical treatment (Crohn), 2 with endoscopic therapy (jejunal angiodysplasia), 3 surgery (1 Crohn and 2 tumours in ileum). Only two of the 12 diagnosis of angiodysplasia were effectively treated. The authors suggest that WCE should be used first choice after a negative upper and lower conventional endoscopy and PE should be used in cases with positive WCE findings located at the proximal small bowel within the reach of enteroscopy. Finally enteroscopy could also be considered in patients with negative CE findings.</p>	<p>Method: not reported. Results: well tolerated by all patients.</p>	<p>This is not a randomised trial, and patients serve as their own controls. The main aim of this study, given that PE is not a fair comparator should have been how WCE changed treatment strategy.</p>
---	--	--	--	--	--	--	---	--

<p>Adler DG, et al. 2004 USA (Rochester- Minnesota)</p>	<p>To compare WCE and PE in the investigation of the small bowel in patients with OGIB.</p>	<p>A prospective "blinded" study enrolling 20 patients with GI haemorrhage. All patients underwent WCE followed by PE. The physician performing the enteroscopy (senior endoscopist) interpreted the WCE results in an unblinded manner, while a second blinded reviewer (endoscopy assistant) interpreted them to establish the reliability of the interpretation.</p>	<p>Time range: not reported. Follow up: 11-24 months, but only for patients who received care at the centre subsequent to the procedure.</p>	<p>Twenty patients with OGIB, negative EGD and colonoscopy in last 2 months. All had documented iron deficiency anaemia. 8 men, 12 women. Mean age 65.5 years, range 38-80. Exclusion criteria reported (age less than 18 years, pregnancy, cardiopulmonary disease etc., GI tract obstruction).</p>	<p>Diagnostic yield of WCE. Definitive sources of bleeding in the small bowel were identified by WCE in 6 out of 20 patients (30%) and only two of them were found to have small bowel angioectasias at PE. 5 of them underwent targeted endoscopic or surgical therapy based on WCE and PE findings. The WCE did not affect the management of patients found to have indeterminate lesions.</p>	<p>WCE - No complication PE - No complication</p>	<p>Not reported</p>	<p>WCE has an impact on long term management of patients with clearly defined lesions (angioectasia, focal ulcer), but doesn't affect the management of patients with less defined lesions. WCE allows the detection of small or trivial lesions that are not evidenced during a standard PE and do not necessarily cause bleeding. The study used the first software version for WCE's which did not provide localisation. A large trial with a control arm with normal asymptomatic individuals should be undertaken. The interpreters' reliability was high.</p>	<p>This is not a randomised trial. And presents several factors to be considered a) PE may not be a proper comparator, since it doesn't reach the part of small bowel reached by WCE. B) That a basic requirement of all the studies should be the definition of the kind of lesions (definitive or not) found with WCE vs those found by PE C) Each study should highlight the changes in the management of patients brought about with or without WCE.</p>
---	---	---	--	--	--	---	---------------------	---	--

<p>Saurin et al., 2005 FRANCE (Lyon and Paris)</p>	<p>To evaluate the long term outcome in WCE patients and to understand the clinical relevance of lesions detected with WCE. To compare WCE and PE specificity and sensitivity, using previous results in terms of clinical outcome, as a gold standard.</p>	<p>A "follow up study", it involves 58 patients already enrolled in a previous prospective study comparing WCE and PE. Patients were contacted after 1 year, and each case was classified into true/false positive or true/false negative findings at PE and WCE. The results were compared with the initial classification of lesions observed at WCE: highly relevant (P2), and less relevant (P0, P1) lesions.</p>	<p>Time range: PE within 3 days after WCE Follow up: not reported</p>	<p>Sixty patients, mean age 58 (± 18 years, range 21-79); 27 men and 33 women. 28 patients (47%) presented recurrent overt GI bleeding. Fifty eight patients were eligible.</p>	<p>Diagnostic yield (small bowel lesions with potential for bleeding) CE: 40/60 (67%), 19 patients with lesions both on CE and PE; PE: 22/60 (37%), including 3 patients missed with CE. Sensitivity (95% CI) of WCE 0.92 (0.82-1.00) and PE 0.69 (0.53-0.87) - Specificity (95% CI) of WCE 0.48 (0.32-0.68) and PE 0.80 (0.54-0.94). PPV of WCE 0.62, and of PE 0.75 - NPV of WCE 0.87 and NPV 0.74.</p>	<p>WCE - Not reported PE - Not reported</p>	<p>Not reported</p>	<p>WCE is a sensitive examination for the detection of lesions in patients with OGB; its specificity is lower than that of PE when the clinical outcome is used as the gold standard. Taking into account the relevance of all lesions identified in the small bowel by WCE initial, 15 of 18 were highly relevant lesions (83.3%) were ultimately classified as true positive cases compared with seven of 22 less relevant lesions (31% p=0.0003). The non invasive nature of WCE and its high negative predictive value suggest that it should be used before any therapeutic PE, which might subsequently be required.</p>	<p>This is not a randomised study. It tries to identify a way to determine sensitivity and specificity of WCE vs PE, finding a proper gold standard and avoiding a too strict definition of true positive and false positive cases of others (Pennazio, 2003). It seems that most of the lesions identified by WCE are small, and the study underlines the problem of lesions not detected because they are out of the area examined by PE. It is unclear whether they calculated specificity and sensitivity referring only to the part of the small bowel that both procedures can reach.</p>
--	---	---	---	---	---	---	---------------------	--	---

<p>Neu et al., 2005 GERMANY (Hamburg, Munich, Mainz, Altona, Wiesbaden)</p>	<p>To evaluate the influence of WCE findings in the further management of patients (major changes in management), particularly with OGIB. Analysis of outcome changes such as a significant reduction of further bleeding.</p>	<p>A multicenter prospective study carried out in five different tertiary referral centres. The diagnostic yield of WCE was compared to three other tests, PE and Small Bowel Double contrast radiography (SBE) and Selective Abdominal Angiography, but in different sequence according to the centres facilities. An endoscopist with similar experience reviewed WCE videos. WCE results only were unblinded for PE. Patients were followed up for at least 6 months. Parameters that led to major management changes were analysed (e.g. surgical or endoscopy interventions, specific medical therapies) as well as their correlation to further bleeding.</p>	<p>Time range: not reported Follow up: 6 months</p>	<p>Fifty six patients 17 women and 30 men, mean age 63 years (range 18-82), OGIB (OBD) was an inclusion criteria, being this overt in 37 patients, and occult in 19 patients.</p>	<p>Diagnostic yield of WCE compared to the diagnostic yield of three other comparator tests (OT). WCE detected 42% of lesions with low probability of bleeding, and 58% of lesions with a high probability, PE detected 27% of minor lesions and a 73% of major lesions (tables show results for each single technology and also aggregated results).</p>	<p>WCE - Not reported PE - Not reported</p>	<p>Not reported</p>	<p>WCE helps with management decisions and can replace other more complex and risky standard tests. Nevertheless, clinical parameters are equally important for predicting further bleeding and should also be used to decide on further management.</p>	<p>It is not a randomised study. The text states that since visualisation of the small bowel by PE is partial, its DY may have been underestimated. In addition the authors state that WCE often identifies many lesions which are not the cause of bleeding. The study's conclusions are difficult to interpret as the authors discuss aggregate data while presenting data in a disaggregate form. K11</p>
---	--	---	---	---	---	---	---------------------	--	--

<p>De Leusse et al., 2007 FRANCE (Paris)</p>	<p>To assess diagnostic yield of WCE vs PE as first line exploration in OGIB; Assess clinical relevance of WCE and PE and accuracy of the exploration.</p>	<p>Prospective randomised trial. All consecutive patients referred for obscure gastrointestinal bleeding were randomised to either WCE or PE as the first-line exploration. The alternative method was only used if the first line method revealed no definite bleeding source, or if required for clinical reasons during follow-up.</p>	<p>Follow up: 12 months</p>	<p>Seventy eight patients, 30 women and 48 men, average age of 54±16 years (range 22-85 years). All patients had undergone other procedures before.</p>	<p>The diagnostic yield of WCE and PE for definite sources of bleeding were 17/40 patients (43%; 95% CI: 13-40) and 4/38 patients (11%; 95% CI: 4-25), respectively for small bowel lesions (P=.02), 3/40 patients (8%; 95% CI: 3-20) and 4/38 patients (11%; 95% CI: 4-25) for gastric lesions and 0/40 patients (0%; 95% CI: 0-7) and 1/38 patients (3%; 95% CI: 1-14) for colonic lesions.</p> <p>Performances of WCE for all lesions: sensitivity° 79 (60-86); specificity° 87(67-90); PPV 88 (75-90) and NPV 77 (50-85). For small bowel lesions: sensitivity° 100 (61-100); specificity° 90 (77-92); PPV 85 (69-88) and NPV 100 (71-100). Performances of PE for all lesions: sensitivity 41(30-53)*; specificity 100 (91-100); PPV 100 (89-100) and NPV 56 (35-72). For small bowel lesions: sensitivity 33 (21-43)*; specificity 100 (93-100); PPV 100 (83-100) and NPV 62 (41-75). *P=.025 vs WCE. °Corrected for non verified cases.</p>	<p>WCE - 1 patient (1%) refused to swallow the capsule and had it introduced endoscopically; - In 6 patients (9%) the capsule did not reach the caecum. PE - No significant complications</p>	<p>Not reported</p>	<p>This randomised study confirms that WCE has a higher diagnostic yield (DY) than PE in patients with OGIB. The two strategies tested (WCE or PE first one then the other, if negative) were not statistically different in terms of DY, clinical remission rate, therapeutic impact, need alternative exploration during first year. However CE first strategy is simpler and better tolerated as first strategy.</p>	<p>The only proper randomised study of the whole systematic review. It is a very good study. Shortcomings related to the generalisability of the results due to the number of patients enrolled (78) and to the clinical characteristics of patients, which seem to be very specific to French context (see very high haemoglobin levels). Reasons for patients lost to follow up are not reported.</p>
--	--	---	-----------------------------	---	--	---	---------------------	---	---

Van Gossum et al. 2003 BELGIUM (Bruxelles)	To compare VCE and PE diagnostic yield, safety and tolerance in patients with OGIB. Global diagnostic yield included all lesions detected in the upper GI tract and the visualised gut. Specific diagnostic yield: lesions located beyond reach of EGD. Complication recorder and tolerance assessed by patient's questionnaire.	Prospective pilot study. Patients underwent VCE first and within 1 week PE. Both procedure were performed blindly.	Time range: VCE first and PE within 7 days.	Twenty one patients with OGIB and negative EGD and colonoscopy (overt bleeding in 5, occult bleeding in 16) 7 men, 14 women Mean age 60 years, range 18-81. The patients enrolled had unexplained chronic iron-deficient anaemia or digestive blood loss after routine investigations.	Global diagnostic yield: VCE 52% PE 61% Specific diagnostic yield: 20% for both methods	1 patient has the capsule blocked in an appendiceal stump and retrieved by a snare through colonoscopy. Battery failure (BF) in 5/21 patients.	Subjective tolerance of both procedures was good, but slightly better for WCE.	Authors state that this study showed that the main advantage of WCE is that it detects distal lesions which are beyond the reach of the enteroscope. Furthermore many lesions are detected in the upper GI tract of OGIB patients and which are usually underestimated. According to the authors this suggest that WCE should be used after PE or at least after repeating a careful EGDS and not as a first line procedure.	Not a RCT
---	--	--	---	---	--	--	--	--	-----------

*Data from those studies which assess WCE for mixed indications or different diagnostic modalities were included only if they fulfilled our inclusion criteria.

***SAFETY:** Adverse events (AE): none, self resolving symptoms (SR: e.g. not swallowing capsule), therapy (T: e.g. Retention of capsule), surgery (S: e.g. Retention of capsule), mortality (M). Technical Problem (TP): failure of battery (BF), battery expired (BE)

Table B: OGIB_WCE versus DBE

Study	Aim	Design	Time range and/or follow up	Participants	OUTCOMES			Comments
					Diagnostic accuracy	Safety*	Acceptability	
Matsumoto et al. 2005 Japan (Fukuoka)	To compare diagnostic accuracy of WCE vs DBE for small-intestinal pathologies.	Prospective study. A total of 22 patients were enrolled. Thirteen patients with "Overt GIB" and 9 patients with known OGIB and gastrointestinal polyposis were examined using ante grade or retrograde DBE, and the most distal or proximal site in the explored small intestine was marked by a submucosal tattoo, to assess if WCE is able to identify it, this allows comparison of its findings with initial DBE. The patients were then evaluated by WCE within 7 days, and if positive to WCE they underwent a second DBE examination with the other approach. The endoscopic findings with DBE and WCE within the reach of the initial DBE were compared. Video images were reviewed by an observer who was blinded to the DBE findings.	Time range: DBE and within 7 days WCE.	Twenty two patients (11 women and 11 men) average age 63 years (range 21-72). Seventeen patients examined by ante grade DBE; 5 patients by retrograde DBE; 22 patients examined by WCE. Eleven patients had overt GI bleeding and severe anaemia with haemoglobin values ranging from 6.0 to 8.3 g/dl (4 patients required 4-12 units of blood transfusion);	WCE - No complications DBE - No complications	NOT REPORTED	The value for diagnosing OGIB is similar in the two procedures for the area reached by DBE. DBE appears to be superior to WCE in the diagnosis of small-intestinal polyps.	The study is also about OGIB and FAP. This is not an RCT and the same group of patients underwent both procedures. The number of patients is very small and they seem to have different clinical characteristics (see overt GIB and haemoglobin levels), although there are no tables reporting clear clinical data of all patients. It is worth highlighting that this study is the only one with a positive conclusion on DBE compared with WCE. Conflict of interest is not declared but, DBE is a procedure proposed and commercialised by a Japanese physician (Yamamoto); it is not a very widespread technology, but was already used in this department.

<p>Hadithi et al, 2006 Netherlands (Amsterdam)</p>	<p>To compare the detection and diagnostic rate of WCE and DBE in patients with OGIB.</p>	<p>Prospective study. Thirty five consecutive patients with OGIB were offered WCE followed by DBE.</p>	<p>Time range: WCE 7-14 days before DBE Follow up: median 5 months,; range 2-12 months.</p>	<p>Thirty five patients (13 women and 22 men) average age of 63.2 years (range 19-86). All patients had OGIB and had undergone gastroscopy and endoscopy. Clinical characteristics of patients are reported.</p>	<p>Diagnostic detection rate of WCE: 80% (28/35 - not declared), DBE 60% (21/35 - P=0.03)</p>	<p>WCE - AE (SR): 2 patients had difficulty in swallowing the capsule (6%); DBE - AE: (SR) 10 patients reported abdominal pain (29%); - (SR) In 2 patients the procedure was interrupted (3%); no reasons given</p>	<p>Method: questionnaire concerning tolerability during follow up and questions about sore throat or abdominal discomfort, with recording of procedure related problems. Results: DBE was less tolerated than WCE (40% vs 94%, p<0.001). No table synthesising data and number of respondents.</p>	<p>Higher detection rates by WCE, but limits are related to its inability to perform conventional endoscopic procedures, while DBE has therapeutic potential. WCE detects all lesions, this may explain the high number of false positives. WCE and DBE are complementary: WCE is a good candidate to be the first diagnostic step in approaching selected patients with OGIB, DBE may verify WCE findings and provides therapeutic options.</p>	<p>This is not an RCT, and the same group of patients undergo both procedures. The number of patients in small and with heterogeneous clinical characteristics.</p>
--	---	--	---	--	---	---	---	--	---

<p>Nakamura et al, 2006 Japan (Nagoya)</p>	<p>To assess the diagnostic and access ability (entire small bowel) rates of WCE and DBE in patients with suspected small bowel bleeding. To consider the roles and indications of WCE and DBE in small bowel bleeding.</p>	<p>Prospective and blinded study. Thirty two patients with obscure or overt GI not localised by previous examinations. Patients were underwent WCE and then DBE (possibly with dual approach. DBE) the endoscopist was blinded to the results of WCE. Bleeding sources were categorised as either A1 lesions (immediate haemostatic procedures required) or A2 lesions (close observation required). WCE and DBE were evaluated with regard to whether or not they were capable of accessing the entire small bowel and the ability to provide a diagnosis. The access and diagnostic rates were calculated.</p>	<p>Time range: WCE 2 days before DBE.</p>	<p>Thirty-two patients (11 women and 21 men) average age of 58.5 years, range 25-85. Clinical characteristics similar. Mean haemoglobin 7.3 g/dl with 22 patients requiring transfusion and some receiving treatment. Exclusion criteria declared.</p>	<p>Access rate to entire small intestine: WCE 90.6% (29/32) DBE 62% (10/16 p<0.05). Diagnostic rate: WCE 59.4% (19/32), DBE 42.9% (12/28 p=0.30).</p>	<p>WCE - No complications DBE - 1 patients declined DBE (3%)</p>	<p>NOT REPORTED</p>	<p>In many cases of suspected small bowel bleeding WCE should be selected for the initial diagnosis and DBE for treatment or histopathologic diagnosis after detection of the bleeding site by WCE. However if it is suspected that the bleeding site is located in the distal ileum, DBE may be chosen initially, as WCE is unable to achieve this due to food residues or battery failure</p>	<p>This is not an RCT and the same group of patients underwent both procedures; the number of patients is small; Not clear why DBE should be used for distal ileum suspected lesions: the indication seems to be that DBE identified a Meckel's diverticulum in the distal ileum, and a colon cancer.</p>
--	---	--	---	--	--	--	---------------------	---	---

<p>Xiao-bo et al, 2007 CHINA (Shanghai)</p>	<p>To evaluate the detection rate and diagnostic accuracy of WCE and DBE alone and combined, for patients with suspected small bowel disease.</p>	<p>Prospective "categorised" study. A total of 218 patients in whom it had not been possible to determine causes of OGIB, abdominal pain or diarrhoea using conventional diagnostic procedures, were categorised into 2 groups undergoing both WCE and DBE. Patients with negative or equivocal findings on WCE undergo DBE and vice versa.</p>	<p>Time range DBE/WCE (if negative, then the alternative); mean interval time between CE and DBE was 12.9 days (2-50 days). Follow up: not reported (just 3 patients negative to DBE were followed for 6 months)</p>	<p>Two hundred and eighteen patients were categorised into two groups undergoing either CE or DB. Among the 165 patients (94 male, 71 female; average age 50.5, range 16-87 years) undergoing CE first, 101 cases had obscure gastrointestinal bleeding and 64 cases had obscure abdominal pain or diarrhoea. Fifty-three patients (32 male, 21 female; average age 46.8 years, range 18-75 years) underwent DBE first, including 15 cases with obscure gastrointestinal bleeding and 38 with obscure abdominal pain or diarrhoea.</p>	<p>Detection rate - overall: WCE 72% (118/164), DBE 41.2% (21/51); Diagnostic accuracy overall: WCE 51.8% (85/164) DBE 39.2% (20/51). Detection rate - OGIB: WCE 88% (88/100) DBE 60% (9/15); P=0.0054). Diagnostic accuracy - OGIB: WCE 65% (65/100) DBE 39% (20/51).</p>	<p>WCE - 2 patients retained the capsule at lower oesophagus and one of them renounced continuing the examination - 5 patients retained capsule (T) - 2 of them underwent surgical removal (S) - Capsule had not reached the caecum by the end of the recording time in 44 patients (BE) DBE - 39 patients reported discomfort after DBE (SR) - 2 patients failed to complete the DBE (due to partial gastrectomy);(SR)</p>	<p>NOT REPORTED</p>	<p>The detection rate of small bowel diseases with DBE is relatively lower than that with WCE. The two procedures are complementary: WCE as initial diagnostic approach for suspected small bowel diseases especially for OGIB. With regard to the relatively high indefinite diagnostic rate (28%) of small bowel disease and the inability to provide diagnostic sampling, DBE still appears to be a viable instrument to complete and/or confirm the negative and indefinite diagnosis made by WCE.</p>	<p>This study analyses OGIB and other cases with obscure abdominal pain and chronic diarrhoea. It appears to be a comparative study, but it is not "randomised". Randomisation (if any) is not clearly explained. The text does not explain why of the initial group of 216 patients, 165 underwent WCE first, while 53 underwent DBE. Clinical characteristics of the patients are not reported.</p>
---	---	---	--	--	--	---	---------------------	--	---

<p>Gay 2006, FRANCE (Nancy)</p>	<p>To assess if the combined use of WCE followed by DBE can be effective in selecting patients in whom DBE was indicated. The secondary aim was to assess if DBE reaches lesions identified by WCE, safety and tolerability of the combined approach.</p>	<p>This is a prospective study. Patients with a suspected intestinal disease and a validated indication for WCE were included. All patients investigated with WCE, showing a lesion which recalled more investigation, underwent DBE. Due to the high negative predictive value of WCE, patients with a negative WCE did not undergo further investigation.</p>	<p>Time range: all DBE procedures were performed between 48 and 120 hours (2-4 days) after the WCE. Follow up: 3/12 months</p>	<p>A group of 160 consecutive patients. Half of them underwent only WCE, while 42 had DBE (4 underwent DBE only). The group was composed of 87 OGIB cases, 17 suspected tumour, 13 Crohn's disease, Celiac disease 12, FAP 10, others 21. Average age 54±18.</p>	<p>Diagnostic yield of WCE 75%</p>	<p>WCE - No "major" complications due to the procedure. DBE - No "major" complications due to the procedure or anaesthesia.</p>	<p>Method: not reported Results: Mild, transient abdominal discomfort in 2 patients who complained of bloating.</p>	<p>The use of WCE as a filler for DBE results in effective management of patients with various intestinal diseases.</p>	<p>The study involved patients with various indications for small bowel investigation, such as OGIB (the majority also had suspected Crohn's Disease, Coeliac Disease, neoplasms). The objective is not to compare the WCE's diagnostic accuracy versus DBE. The superiority of WCE is assumed on the basis of the evidence provided by previous studies (see, p. 50 of the article), which show also that its limitation is related to its purely visual diagnostic nature. It appears that the visualisation offered by WCE, in many cases, is sufficient to allow a diagnosis. It is not clear how the diagnostic accuracy of WCE was calculated.</p>
---------------------------------	---	---	--	--	------------------------------------	---	---	---	--

Table C: OGIB_WCE versus Others

							OUTCOMES			
Study	Aim	Comparator	Design	Time range and/or follow up	Participants	Diagnostic accuracy	Safety	Acceptability	Conclusions	Comments
Costamagna et al. 2002 ITALY (Rome)	To compare the clinical outcomes of small bowel radiographs - SBFT - with WCE	SB radiographs (Barium Follow Through)	This is a prospective study. Consecutive patients with suspected small bowel disease were enrolled and underwent barium follow-through and WCE, to compare their findings. The endoscopist was blinded to radiograph's results.	Time range: Barium follow-through then after 4 days endoscopy Follow up: not reported	Twenty two patients with small bowel diseases (13 men, 8 women). Two were excluded due to ileal stenosis. Average age 52.5 years, range 29-78. Thirteen had OGIB, 3 suspected Crohn's disease/recurrence, 1 suspected sarcoma recurrence, 1 unexplained chronic diarrhoea, 1 had FAP, 1 had small bowel polyposis. All patients had undergone other diagnostic procedures. Contraindications reported	Findings were classified as: - diagnostic - if the findings could explain symptoms or were later confirmed by other methods; - suspicious - if further investigation is required to confirm clinical relevance; - failed - if no abnormality was detected despite a definite indication of an existing lesion. Barium follow-through was normal in 17 patients and showed ileal nodularity in 3 patients. WCE was normal in 3 patients and showed positive findings in the remaining 17 patients. The barium study was considered: - diagnostic in 4 (20%) patients, - suspicious in 0 and failed in 15 (73%). Capsule endoscopy was considered: - diagnostic in 9 (45%) patients, - suspicious in 8 (40%) patients, - failed in 3 (15%) patients. For OGIB, the diagnostic potential of barium follow-through was much worse compared with WCE (5% vs 31%, P<0.05).	WCE: battery failure in 1 patient. SBFT: no problems reported	NOT REPORTED	WCE found to be superior to small bowel radiograph for evaluation of small bowel disease.	The study is about OGIB, suspected Crohn's disease and Familial Adenomatous Polyposis. (Considering Crohn's disease and FAP the number of patients was less than 10) It is not clearly stated which other diagnostic procedure was used for OGIB patients. Data in the text did not correspond with data in tables.

<p>Hara et al. 2003 Location not reported</p>	<p>To compare WCE findings with barium studies or computed tomography (CT) in patients with no evidence of small bowel stricture at barium examination.</p>	<p>CT and barium studies</p>	<p>This is a retrospective study. Fifty two patients underwent WCE, subsequently 36 underwent SBFT, 4 enteroclysis, and 19 CT of abdomen and pelvis. Imaging results were retrospectively reviewed and compared with WCE, standard endoscopy, and surgical results. A radiologist, who was not blinded to the WCE results, retrospectively reviewed discrepancies between WCE and imaging examinations. Proportion of positive findings at WCE was compared with proportion of positive findings at barium studies and CT in the same patients. Statistical significance was calculated with McNemar statistic.</p>	<p>Time range: Barium studies and/or CT within 6 months (either before or after) of CE.</p>	<p>Fifty two patients, 31 men, average age 64 years, range 21-92 and 21 women, average age 63 years, range 28-82 years. Forty three patients underwent WCE for OGIB</p>	<p>Barium examination findings were positive in one (3%) of 40 patients; WCE findings were positive in 22 (55%) (P<0.001). CT demonstrated small-bowel findings in four (21%) of 19 patients, but WCE demonstrated findings in 12 (63%) of 19 patients (P=0.02). The most common CE findings, angiectasia (11 cases), was not detected at any imaging study. More ulcers (8) were detected with WCE than with barium study (one of eight) and CT (three of six). At WCE, three of five surgically confirmed masses (carcinoid, intussusceptions, lymphangioma) were identified, but two jejunal tumours were not detected in a patient with poor bowel preparation. At barium study, no masses (zero of five) were detected; at CT, one of four masses was detected.</p>	<p>NOT REPORTED</p>	<p>NOT REPORTED</p>	<p>In patients without a small-bowel stricture at barium study, more small-bowel diseases were found with WCE when findings were retrospectively compared with barium examination and CT findings. Nevertheless lesion localisation and evaluation can be difficult with WCE that cannot measure abnormality or control the camera when the abnormality when identified. It is difficult to localise precisely the abnormality detected after WCE.</p>	<p>The time range between one diagnostic examination and another is not clear.</p>
---	---	------------------------------	---	---	---	---	---------------------	---------------------	--	--

Golder et al. 2006 Germany (Regensburg)	To assess the diagnostic yield of WCE with MR enteroclysis in the detection of small bowel pathologies.	MR enteroclysis	This is a prospective study. A total of 36 patients were included in the study. Indications for imaging of the small bowel were: proven or suspected small bowel Crohn's disease, obscure gastrointestinal bleeding and tumour surveillance. There were 14 patients with OGIC, 16 with CD, and 2 suspected CD. The remaining patients had FAP and tumours. Differences in the detection of pathological findings in the small bowel were calculated using the McNemar test. A p value of <0.05 was considered significant.	Time range: not reported	Thirty six patients (19 women and 17 men) average age 47 years, range 18-84.	Á yield: Upper small bowel 77.1 WCE (27/35) MR 72.2 (26/36); Middle small bowel WCE 62.9 (22/35) MR 77.8 (28.36) Lower small bowel WCE 37.1 (13/35) MR 77.8 (28/36).	Malfunctioning of WCE in 1 patient	NOT REPORTED	The results demonstrate that WCE is superior to MR for Crohn's disease when considering the first and second section of the small bowel, but not for third section	The study is also about Crohn's disease
Saperas et al., 2007 Spain (Barcelona)	Comparison of the diagnostic yields WCE vs Computed Tomography (CT) or Standard Angiography (ANGIO) in patients with OGIB.	Computed Tomography (CT) or standard mesenteric angiography (ANGIO)	This is a prospective study. Consecutive patients admitted for OGIB underwent both CT and ANGIO, followed by WCE performed blindly by independent examiners within the following 7 days.	Time range: WCE within 7 days	Twenty eight patients (12 women and 16 men) average age 74 years, range 36-85.	Á yield: Upper small bowel 77.1 WCE (27/35) MR 72.2 (26/36); Middle small bowel WCE 62.9 (22/35) MR 77.8 (28.36) Lower small bowel WCE 37.1 (13/35) MR 77.8 (28/36).	NOT REPORTED	NOT REPORTED	WCE detected more lesions than CTA or ANGIO in patients with OGIB.	
Hartmann et al. 2005 Germany (Berlin)	To compare diagnostic yield of WCE vs Intraoperative Enteroscopy (IE)	Intraoperative Enteroscopy (IE)	This is a prospective study. Forty seven consecutive patients with obscure GI bleeding from two gastroenterology centres were included. The standard evaluation of these patients included upper endoscopy, colonoscopy with a retrograde examination of the distal ileum, and push enteroscopy.	Time range: WCE and after 6 days IE.	Forty seven patients (17 women and 30 men) average age of 61±17 years, range 18-88.	Á yield: WCE overt ongoing bleeding 100% (11/11) overt previous bleeding 67.0% (16/24) occult bleeding 67.0% (8/12), IE overt ongoing bleeding 100% (11/11) overt previous bleeding 70.8% (17/24) occult bleeding 50.0% (6/12);	WCE: IE: AE (M) 1 patient died of peritonitis after laparotomy.	NOT REPORTED	WCE Diagnostic yield varies according to the type of bleeding. Authors suggest the use of WCE for patients with OGIB, iron deficiencies, and for those negative to bidirectional endoscopy.	Not an RCT. NPP and PPV were calculated. But the IE was used as the reference standard.

*Data from those studies which assess WCE for mixed indications or different diagnostic modalities were included only if they fulfilled our inclusion criteria.

***SAFETY:** Adverse events (AE): none, self resolving symptoms (SR: e.g. not swallowing capsule), therapy (T: e.g. Retention of capsule), surgery (S: e.g. Retention of capsule), mortality (M). Technical Problem (TP): failure of battery (BF), battery expired (BE)

Table D: Crohn's disease_WCE versus Others

Study	Aim	Comparator	Design	Time range and/or follow up	Participants	OUTCOMES				Comments
						Diagnostic accuracy	Safety	Acceptability	Conclusions	
Buchman et al. 2004, USA (Chicago)	To compare the diagnostic yield of the WCE with SBFT and Enteroclysis in CD patients.	SBFT	This is a prospective blinded study. The gastroenterologist was not aware of the SBFT results. Consecutive patients with suspected recurrence of CD on the basis of abdominal pain, diarrhoea, anaemia, and/or arthralgias. SBFT was performed and those patients with strictures and proximal bowel dilatation were excluded. For SBFT, results were graded normal (0), 1 (<5 cm), 2 (<10 cm), 3 (>10 cm). For WCE were graded normal (0), 1 (erythema, isolated villi loss) 2 (erosion, no ulcer) 3 (ulcers, spontaneous bleeding, and/or stricture).	Time range: SBFT and WCE after 1 week. Follow up: NOT REPORTED	Thirty consecutive patients with clinically suspected CD recurrence 22 female, 8 male. Mean age 36.9 years, range 21-80.	Active CD was visualised in 21 of 30 patients with WCE and in 20 of 30 with SBFT. Complete agreement occurred in 13 of 30 patients. In 13 of 17 scores differed by 1 grade.	SR: In 2 (7%) patients WCE was retained for respectively, 9 months and 3 weeks.	Method: a multiple choice patient's satisfaction questionnaire administered to all once WCE was completed. All questions and answers are reported in text. Results: WCE is the preferred procedure compared to SBFT.	Results suggest that WCE and SBFT have similar sensitivity and accuracy for the diagnosis of CD. The time range between the two procedures is quite short and pathology is not supposed to change. Authors state that WCE has been shown to be a safe and effective tool for the diagnosis of CD involving the small intestine. Capsule retention is grater in patients with CD. According to the authors this, in some cases, rather than a complication, should be viewed as diagnostic tool.	The study is not a randomised trial, it is a study with many shortcomings. Patient acceptability: among the reported questions there is one which addresses this issue. The authors report that WCE is the preferred method, and that is less invasive and time consuming. Those two last sentences are not supported by evidence from the questionnaire survey and seem to be author's assumptions. No results tables are reported for any dimension. The abstract states that "twelve patients were excluded for small bowel obstruction", but text and data are not consistent with this. Some of the author's conclusions are not supported by data.

Eliakim et al. 2004, ISRAEL (Haifa)	To compare WCE with barium follow-through (SBFT) and entero-computer tomography (CT) in patients with suspected Crohn's disease.	SBFT Entero-CT	This is a prospective blinded study. Radiologist blinded to WCE results and vice versa. Thirty-five patients with suspected Crohn's Disease (chronic diarrhoea, weight loss, abdominal pain) underwent the three examinations. The radiologist and gastroenterologist were blinded to each other's results. In cases of discrepancy, colonoscopy and ileoscopy were performed.	Time range: all procedures were completed within 3 months. Follow up: NOT REPORTED	Thirty-five consecutive patients with suspected CD 13 female, 22 male. Mean age 28.4 years, range 19-57.	Diagnostic yield WCE: 27/35 (77%), WCE confirmed radiological findings in 9 patients, extended involvement in 6 and ruled out the radiological suspicion of CD in 10 (all confirmed by ileoscopy) SBFT: 23% Entero-CT: 20%	No harms were observed both during and after the procedure.	NOT REPORTED	WCE superior and more sensitive diagnostic tool than SBFT and entero-CT in suspected Crohn's disease.	Not a randomised trial.
Voderholzer et al., 2005 GERMANY (Berlin)	Prospective study to assess WCE vs CT enterocolitis	CT Enterocolitis	Fifty six consecutive patients with Crohn's disease, stenoses <10 mm were excluded, underwent computed tomography (CT) enterocolitis and WCE.	NOT REPORTED	Fifty six consecutive Crohn's Disease patients. Fifteen were excluded for strictures.	Diagnostic yield Jejunal or ileal Crohn's Disease Jejunal or ileal Crohn's disease lesion WCE: 25/41 (61%), 5/41 with large lesion, 3 missed CT enterocolitis: 12/41, 8/41 with large lesion, 0 missed terminal / neo terminal ileum Crohn's Disease lesions. WCE: 24/41 (43%), CT enterocolitis: 20/41	CT enterocolitis - No complication WCE - 2 patients retained the WCE (5%). 1 of them had abdominal pain for 3 days and underwent anti-inflammatory treatment, before the capsule was passed. 1 of them had jejunal stenosis not detected with CT and had no pain. Capsule was removed with PE. - 1 more patient (2%) had to repeat the WCE since the capsule's battery expired while it was still in the stomach.	NOT REPORTED	WCE improves the diagnosis of small bowel Crohn's disease. WCE changed therapeutic path.	Not a randomised trial.

Albert 2005, GERMANY (Halle, Saale)	To assess diagnostic yield of WCE in Crohn's disease. Blind operators	Fluoroscopy, MRI, Enterocolysis	Fifty two consecutive patients were investigated by MRI, fluoroscopy and if there was no bowel obstruction, with WCE.	Time range: MRI and Enterocolysis followed by WCE within 10 days (in 1 patient: 6 weeks. Follow up: NOT REPORTED	Eighty one with suspected Crohn's disease 52 eligible aged 18 to 72.	Diagnostic yield: CE 13/14 92.9%, MRI 11/14 78.6%. BUT enterocolysis vs MRI and enterocoli vs CE (0.01 and 0.002); Pt comfort, safety	MRI - 2 patients (8%) had claustrophobia and 1 patient (4%) refused to undergo MRI. FE - 2 patients (8%) did not tolerate the transnasal tube. WCE - 1 patient (4%) retained capsule in a small bowel stricture undetectable on abdominal ultrasound and Enterocolysis.	NOT REPORTED	WCE and MRI complimentary techniques.	Not a randomised trial.
HoChong et al., 2005 AUSTRALIA (Melbourne)	To compare diagnostic yield of WCE vs PE and Enterocolysis in two groups. Group 1 history of Crohn's disease; Group 2 no history of Crohn's disease.	PE, Enterocolysis	Patients who were suspected to have small-bowel Crohn's disease were prospectively evaluated with push enteroscopy, enterocolysis, and capsule endoscopy. Each examiner was blinded to results of other investigations. Referring doctors were required to complete a questionnaire before and after the investigation.	Time range: WCE 2 weeks after PE and enterocolysis if no stricture detected.	Group 1: 22 patients (17 women and 5 men) average age of 39.8 years (range 17-78). Group 2: 21 patients (11 women and 10 men) average age of 35 years (range 20-80).	In group 1: WCE detected more erosions than the other two examinations (p<0.001) In group 2: a new diagnosis of Crohn disease there was no significant difference yield compared with PE and Enterocolysis	WCE - 1 patient (5%) was unable to swallow the capsule and endoscopic placement in the duodenum was required. PE - No complication Enterocolysis - Failed in 6 patients (29%)	NOT REPORTED	WCE has a higher yield than PE and Enterocolysis in patient with Crohn's disease when small-bowel mucosal disease is suspected	?

<p>Golder et al. 2006, Hartmann et al. 2005, GERMANY (Berlin)</p>	<p>To assess the diagnostic yield of WCE with MR enteroclysis in the detection of small bowel pathologies.</p>	<p>This is a prospective study. A total of 36 patients were included in the study. Indication for imaging of the small bowel were proven or suspected small bowel Crohn's disease, obscure gastrointestinal bleeding and tumour surveillance. Patients were 14 with OGIC, 16 with CD, and 2 suspected CD, remaining patients had FAP and tumours. Differences in the detection of pathological findings in the small bowel were calculated using the McNemar test. A p value of <0.05 was considered significant.</p>	<p>Time range: not reported</p>	<p>Thirty six patients (19 women and 17 men) average age of 47 years (range 18-84)</p>	<p>A yield: Upper small bowel 77.1 WCE (27/35) MR 72.2 (26/36); Middle small bowel WCE 62.9 (22/35) MR 77.8 (28.36) Lower small bowel WCE 37.1 (13/35) MR 77.8 (28/36).</p>	<p>WCE: TP in 1 patient there was a malfunctioning of WCE.</p>	<p>NOT REPORTED</p>	<p>The authors report that the results demonstrate that WCE is superior to MR for Crohn's disease (first and second section of the small bowel, not for third section.)</p>	<p>The study also regards OGIB.</p>
---	--	--	---------------------------------	--	---	--	---------------------	---	-------------------------------------

*Data from those studies which assess WCE for mixed indications or different diagnostic modalities were included only if they fulfilled our inclusion criteria.

***SAFETY:** Adverse events (AE): none, self resolving symptoms (SR: e.g. not swallowing capsule), therapy (T: e.g. Retention of capsule), surgery (S: e.g. Retention of capsule), mortality (M). Technical Problem (TP): failure of battery (BF), battery expired (BE)

Table E: FAP_WCE versus Others

Study	Aim	Comparator	Design	Time range and/or follow up	Participants	OUTCOMES				Comments
						Diagnostic accuracy	Safety	Acceptability	Conclusions	
Caspari et al 2004, GERMANY (Bonn)	To compare Magnetic Resonance Imaging (MRI) and WCE for the detection of small-bowel polyps in patients with inherited polyposis syndrome.	MRI	Prospective blinded study. Twenty consecutive patients were enrolled. An upper GI endoscopy was performed in all. First was given MRI to see if any stricture was present in order to withdraw patients from study. The number, size, and location of polyps were analysed and data compared. Blinded evaluators for MRI and WCE.	Time range: MRI and the day after WCE Follow up: NOT REPORTED	20 consecutive patients, 14 male, 6 female, 4 with Peutz-Jeghers' syndrome (PJS) and 16 with familial adenomatous polyposis (FAP).	Polyps divided by size into 4 groups: 0-5mm; >5-10 mm, >10-15 mm, and >15 mm. WCE: 448 polyps identified in 8 patients; MRI: 24 polyps identified in 4 PJS patients. group 1 only detected using WCE; 2nd group: more often detected using WCE; third group: equally well detected. For very large polyps WCE provided only a partial view. MRI identified 2 desmoid tumours in FAP patients CE identified active bleeding areas in PJS patients. Relevance of the many small polyps identified in PJS was not clear. Both MRI and CE may be adequate for small-bowel screening in PJS patients.	NOT REPORTED	NOT REPORTED	NOT REPORTED	Polyps larger than 15 mm were detected both by MRI and WCE, whereas ONLY WCE detected those smaller than 5 mm. However, location of the detected polyps and determination of their exact sizes was more accurate by MRI and WCE can give more false positive and false negative results. FN are due to impaired visualisation or excessively rapid propulsion of capsule and FP due to retro propulsion of capsule causing the same polyp to be recorded twice or more. WCE cannot give the exact size and location of the polyp. Duodenal polyp clustering around papilla of Vater could not be seen by WCE, since this is often obscured by bile.

Schulman et al. 2005 GERMANY (Bochum)	To determine the efficacy and safety of WCE and PE in patients with FAP. The aim was the same for patients with Peutz Jegers Syndrome but the comparators were not only PE, but also EGDS, MR enteroclysis and surgical specimen.	PE	Prospective study. Forty consecutive patients with hereditary polyposis syndromes were prospectively examined. Results were compared with push-enteroscopy (PE) results in FAP and with esophago-gastroduodenoscopy, PE, (MR) -enteroclysis, and surgical specimen in PJS patients.	Time range: PE initially and within 3 weeks WCE.	Forty consecutive patients with FAP (17 men, 12 women; median age 42 years; range 15-56) and 11 with Peutz-Jeghers Syndrome (2 men, 9 women; median age 34 years; range 23-58).	Twenty one out of 29 (76%) FAP patients had duodenal polyps on EGD and duodenoscopy, WCE missed 2; 16 of the 21 patients also had polyps in jejunum both detected by PE and WCE; 5 of the 21 also had polyps in distal jejunum and ileum detected only by WCE; 1 of the patients had polyps located only in the distal jejunal or ileal area, and detected by WCE. WCE detected polyps in 10/11 patients with Peutz-Jeghers Syndrome, a rate superior to all other reference procedures employed.	WCE - 2 patients retained the capsule and had it removed endoscopically (6%); - 1 patient (3%) was disconnected after 3 hours; PE - No complications;	NOT REPORTED	Results suggest that WCE may be of clinical value in selected patients with FAP, whereas in PJS WCE could be used as a first line surveillance procedure.	NO RCT.
Wong et al., 2006 USA (Utah)	To assess WCE vs PE in the surveillance of FAP, for the diagnosis of small bowel polyps in individuals with FAP.	PE	Prospective study, BUT the design is not clear (see comments). Participants with FAP selected on the basis of the high number of proximal small bowel polyps and prior endoscopic tattoo placement in the proximal small bowel. Patients returned for follow-up (upper endoscopy) approximately 1 year later, and eligible patients were enrolled in the study. Exclusion criteria included the inability to provide informed consent, contraindications to endoscopy, known or suspected bowel obstruction, stricture, cardiac pacemaker, pregnancy, or incarceration.	Time range: NOT DECLARED (only 1 patient had PE, and WCE after 30 days) - Follow up: NOT REPORTED	Thirty two patients (19 men and 13 women) average age of 45 years (range 26-73).	Two WCE readers detected a median of 9 (interquartile range (IQR), 5.0-19.0) and 10 polyps respectively.	WCE - 6 patients (19%) retained the capsule which was removed endoscopically the day whilst performing the comparative procedure. Almost half of the batteries expired (TP) PE - No complications;	NOT REPORTED	WCE underestimates the number of small-bowel polyps in patients with FAP and is not consistent in detecting large polyps.	Not a RCT. But they state that "Participants were randomized either to placebo or the study drug". In the first place the comparator is not a drug and secondly the participants underwent PE and subsequently WCE. The PE was provided by Pentax Precision Instruments.

*Data from those studies which assess WCE for mixed indications or different diagnostic modalities were included only if they fulfilled our inclusion criteria.

***SAFETY:** Adverse events (AE): none, self resolving symptoms (SR: e.g. not swallowing capsule), therapy (T: e.g. Retention of capsule), surgery (S: e.g. Retention of capsule), mortality (M). Technical Problem (TP): failure of battery (BF), battery expired (BE)

Table F: Systematic review/Meta analysis

Study	Aim	Design	Indication	Comparator	Participants	Results	Conclusion
Marmo et al. 2005	Systematic review - To determine the diagnostic yield and safety of capsule endoscopy vs. alternative diagnostic modalities	A search for the prospective studies comparing capsule endoscopy vs. other diagnostic tests in adults was performed between 1966 and 2005. Selected studies were included in a meta-analysis. Three analyses were run separately, the studies had occult gastrointestinal bleeding or Crohn's disease as main outcome.	OGIB, Chron's disease	VCE vs PE in 8 studies, SBFT in 6 studies , CT enteroclysis	526 patients were evaluated (289 submitted to CE for OGIB, 237 submitted to CE for Known or suspected Crohn's Disease)	Seventeen studies met inclusion criteria. The rate difference between capsule endoscopy and alternative modalities for small bowel disease was 41% (95% CI 35.6-45.9); 37% (95% CI 29.6-44.1) for occult gastrointestinal bleeding; and 45% (95% CI 30.9-58) for Crohn's Disease. Failure to visualise the caecum occurred in 13% significantly more often in occult bleeders (17%) than in patients with Crohn's Disease (8%) (P<0.006). Adverse events were recorded in 29 patients (6%). Capsule retention was more frequent in patients with Crohn's Disease (3% vs. 1% OR 4.37).	VCE proved significantly superior to push bowel radiology in the diagnosis of ileal disease.
Triester et al. 2006	Meta analysis Evaluate diagnostic yield of CE vs SBFT (small balloon follow through); CTE (CT enterography); C+I (colonoscopy with ileoscopy); PE; EC enteroclysis; Small bowel MRI for chron disease diagnosis.	To perform a recursive literature search of prospective studies comparing the yield of CE to other modalities in patients with suspected or established Crohn's Disease. Data on Yield among various modalities were extracted, pooled, and analysed. Incremental yield (yield of CE-yield of comparative modality) and 95% confidence interval (95% CI) of CE over comparative modalities were calculated. Sub analyses of patients with a suspected initial presentation of Crohn's Disease and those with suspected recurrent disease were also performed.	Chron's disease	SBFT (small balloon follow through); CTE (CT enterography); C+I (colonoscopy with ileoscopy); PE; EC enteroclysis; Small bowel MRI for chron disease diagnosis.	Eliakim 2004; 35 patients; Hara 2005: 17; Bloom 2003: 19; Buchman 2004: 30; Costamagna 2002: 3; Dubcenco 2004: 31; Toth 2004: 47; Chong 2005: 37; Marmo 2005: 31; Golder 2005: 18; Voderholzer 2005: 41.	9 studies (N=250): yield for VCE vs BR (40%, p<0.01); 4 trials (N=114): yield for VCE vs C+I (61% e 46%, IY 15%;p=0.02); three studies (n=93) VCE vs CT enterography (69% e 30%, IY -38%, p=0.001. Two trials VCE vs PE (IY 38%, p<0.001); one trial VCE vs MRI (IY-22%, p=0.16)	VCE superior to all modalities for diagnosing of non stricturing small bowel CD, with a number needed to test (NNT) of 3 to yield one additional diagnosis of CD over small bowel barium radiography and NNT= 7 over colonoscopy with ileoscopy.

Appendix 5

Tables on WCE Safety

		Technical problems		Adverse events		
Study on OGIB/WCE_PE	TOT Patients	Battery Failure	Battery Expired	Capsule retained for long time (2 or more days)	Capsule blocked_intervention required	Not swallowed_problems passing stomach
Mylonaki et al. 2003,	50	4	16	0	0	8
Mata et al. 2004	42	0	3	1	1	1
Adler et al. 2004	20	0	0	0	0	0
Saurin et al., 2005	60	ND	ND	ND	ND	ND
Neu et al., 2005	56	ND	ND	ND	ND	ND
De Leusse et al., 2007	78	0	6	0	0	1
Van Gossum et al.	21	5	0	0	1	0
Total	211	9	25	1	2	10

		Technical problems		Adverse events		
Study on OGIB/WCE_PE	TOT Patients	Battery Failure	Battery Expired	Capsule retained for long time (2 or more days)	Capsule blocked_intervention required	Not swallowed_problems passing stomach
Mylonaki et al. 2003,	50	4	16	0	0	8
Mata et al. 2004	42	0	3	1	1	1
Adler et al. 2004	20	0	0	0	0	0
Saurin et al., 2005	60	ND	ND	ND	ND	ND
Neu et al., 2005	56	ND	ND	ND	ND	ND
De Leusse et al., 2007	78	0	6	0	0	1
Van Gossum et al.	21	5	0	0	1	0
Total	211	9	25	1	2	10

		Technical problems		Adverse events		
Study on OGIB/WCE_others	TOT Patients	Battery Failure	Battery expiry	Capsule retained for 2 or more days	Capsule blocked intervention required	Not swallowed problems passing stomach
Costamagna et al. 2002	22	1	0	0	0	0
Hara et al. 2003	52	ND	ND	ND	ND	ND
Golder et al. 2006	36	1	0	0	0	0
Saperas et al., 2007	28	ND	ND	ND	ND	ND
Hartmann et al. 2005	47	0	0	0	1	0
Total	185	2	0	0	1	0

		Technical problems		Adverse events		
Study CD patients	TOT Patients	Battery failure (technical)	Battery expiry (related to physical problem)	Capsule retained for 2 or more days	Capsule blocked intervention required	Not swallowed problems passing stomach
Buchman et al. 2004	30	0	0	2	0	0
Eliakim et al. 2004	35	0	0	0	0	0
Voderholzer et al., 2005	56	1	0	0	2	0
Albert 2005	81	0	0	0	1	0
HoChong et al., 2005	43	0	0	0	0	1
Golder et al. 2006, Hartmann et al. 2005	36	1	0	0	0	0
Total	281	2	0	2	3	1

		Technical problems		Adverse events		
Study on FAP patients_WCE	TOT Patients	Battery failure (technical)	Battery expiry (related to physical problem)	Capsule retained for 2 or more days	Capsule blocked intervention required	Not swallowed problems passing stomach
Caspari et al 2004	20	ND	ND	ND	ND	ND
Schulman et al., 2005	40	1	0	0	2	0
Wong et al., 2006	32	0	0	0	6	0
Total	92	1	0	0	8	0

Appendix 6

List of excluded studies with reasons for exclusion

Studies excluded if not a systematic review, editorial, letter, news article, clinical guidelines, conference paper, comment, interview, survey or opinion piece, no author.

Adler, S. N. The probiotic agent *Escherichia coli* M-17 has a healing effect in patients with IBS with proximal inflammation of the small bowel, eng. *Dig Liver Dis.* 2006 Sep; 38(9):713; ISSN: 1590-8658

Ahuja, V. Small bowel diagnostics: the taming of the shrew, eng. *Trop Gastroenterol.* 2006 Apr-2006 Jun 30; 27(2):61-2; ISSN: 0250-636X.

Arsura, E. L. and Bobba, R. K. Small bowel exploration by wireless capsule endoscopy, eng. *Am J Med.* 2007 Jul; 120(7):e15; ISSN: 1555-7162 (Electronic).

Anonymous. Metachronous small bowel adenocarcinomas detected by capsule endoscopy in a patient with hereditary nonpolyposis colorectal cancer, eng. *Dig Dis Sci.* 2007 Apr; 52(4):1134-6; ISSN: 0163-2116

Anonymous. What we have learned from 5 cases of permanent capsule retention, eng. *Gastrointest Endosc.* 2006 Aug; 64(2):283-7; ISSN: 0016-5107

Banerjee, R. and Reddy, D. N. Endoscopy-assisted wireless intragastric pH monitoring, eng. *Gastrointest Endosc.* 2007 Jan; 65(1):182; ISSN: 0016-5107

Cao, X. C.; Wang, B. M., and Han, Z. C. Wireless capsule endoscopic finding in Cronkhite-Canada syndrome, eng. *Gut.* 2006 Jun; 55(6):899-900; ISSN: 0017-5749

Cass, O. W. Is half-knowledge worse than ignorance?, eng. *Gastrointest Endosc.* 2006 Oct; 64(4):542-3; ISSN: 0016-5107

Caunedo Alvarez, A.; Garcia-Montes, J. M., and Herrerias, J. M. Capsule endoscopy reviewed by a nurse: is it here to stay?, eng. *Dig Liver Dis.* 2006 Aug; 38(8):603-4; ISSN: 1590-8658

De Franchis, R. and Dell'Era, A. Diagnosis and therapy of esophageal vascular disorders. *Curr. Opin. Gastroenterol.* 2007; 23(4):422-427; ISSN: 0267-1379.

Anonymous. Using capsule endoscopy to diagnose graft-versus-host disease: seeing is believing?, eng. *Gastrointest Endosc.* 2007 Mar; 65(3):410-1; ISSN: 0016-5107

Eliakim, R. The impact of capsule endoscopy on Crohn's disease, eng. *Dig Liver Dis.* 2007 Feb; 39(2):154-5; ISSN: 1590-8658

Anonymous. The impact of wireless capsule endoscopy on gastrointestinal diseases, eng. *South Med J.* 2007 Mar; 100(3):235-6; ISSN: 0038-4348

Anonymous Who would I consider for capsule endoscopy?—Part I, eng. *Can J Gastroenterol.* 2006 Aug; 20(8):517-8; ISSN: 0835-7900

Erber, W. F. and Erber, J. A. Meta-analysis of the yield of capsule endoscopy in patients with Crohn's disease, eng. *Am J Gastroenterol.* 2006 Nov; 101(11):2669; ISSN: 0002-9270

Anonymous. Nonsteroidal antiinflammatory drugs and the small intestine. *Curr. Opin. Gastroenterol.* 2007; 23(2):134-141; ISSN: 0267-1379.

Frieling, T. The clinical impact of capsule endoscopy: to believe or not to believe, eng. *Eur J Gastroenterol Hepatol.* 2006 Aug; 18(8):873-4; ISSN: 0954-691X

Anonymous. Clinical application of wireless capsule endoscopy in pediatric patients for suspected small bowel diseases, eng. *Eur J Pediatr.* 2007 Aug; 166(8):825-9; ISSN: 0340-6199

Gurudu, S. R. and Fleischer, D. E. From small-bowel bleeding to anemia: a wider range of indications for the capsule endoscope?, eng. *Endoscopy.* 2006 Nov; 38(11):1144-5; ISSN: 0013-726X

Hirano, I. and Richter, J. E. ACG practice guidelines: esophageal reflux testing, eng. *Am J Gastroenterol.* 2007 Mar; 102(3):668-85; ISSN: 0002-9270

Hur, C. Esophageal capsule endoscopy for Barrett's esophagus screening: a hard pill to swallow?, eng. *Clin Gastroenterol Hepatol.* 2007 Mar; 5(3):307-9; ISSN: 1542-7714

Lacy, B. E.; O'Shana, T.; Hynes, M.; Kelley, M. L. Jr; Weiss, J. E.; Paquette, L., and Rothstein, R. I. Safety and tolerability of transoral Bravo capsule placement after transnasal manometry using a validated conversion factor, eng. *Am J Gastroenterol.* 2007 Jan; 102(1):24-32; ISSN: 0002-9270

Lashner, B. A. Sensitivity-specificity trade-off for capsule endoscopy in IBD: is it worth it?, eng. *Am J Gastroenterol.* 2006 May; 101(5):965-6; ISSN: 0002-9270

Leong, R. W. L. and Chan, F. K. L. Drug-induced side effects affecting the gastrointestinal tract. *Expert Opin. Drug Saf.* 2006; 5(4):585-592; ISSN: 1474-0338.

Lorenzo-Zuniga, V.; Moreno de Vega, V.; Manosa, M.; Domenech, E., and Boix, J. The utility of wireless capsule endoscopy, as compared with barium contrast study, in a case of Peutz-Jeghers syndrome, eng. *Acta Gastroenterol Belg.* 2006 Oct-2006 Dec 31; 69(4):423; ISSN: 0001-5644

Mishkin, D. S.; Chuttani, R.; Croffie, J.; Disario, J.; Liu, J.; Shah, R.; Somogyi, L.; Tierney, W.; Song, L. M., and Petersen, B. T. ASGE Technology Status Evaluation Report: wireless capsule endoscopy, eng. *Gastrointest Endosc.* 2006 Apr; 63(4):539-45; ISSN: 0016-5107

Anonymous. Enteroscopy and capsule endoscopy, eng. *Endoscopy.* 2006 Nov; 38(11):1079-86; ISSN: 0013-726X

Rey, J. F.; Ladas, S.; Alhassani, A., and Kuznetsov, K. European Society of Gastrointestinal Endoscopy (ESGE). Video capsule endoscopy: update to guidelines (May 2006), eng. *Endoscopy.* 2006 Oct; 38(10):1047-53; ISSN: 0013-726X

Rondonotti, E. and de Franchis, R. Diagnosing coeliac disease: is the videocapsule a suitable tool?, eng. *Dig Liver Dis.* 2007 Feb; 39(2):145-7; ISSN: 1590-8658

Rufo, P. A. and Bousvaros, A. Challenges and progress in pediatric inflammatory bowel disease. *Curr. Opin. Gastroenterol.* 2007; 23(4):406-412; ISSN: 0267-1379.

Shin, J. I. and Lee, J. S. Indications of capsule endoscopy in Henoch-Schonlein syndrome with gastrointestinal symptoms, eng. *Am J Med.* 2007 Jun; 120(6):e13; ISSN: 1555-7162

Sidhu, R.; Sanders, D. S.; McAlindon, M. E., and Kapur, K. Capsule endoscopy for the evaluation of nonsteroidal anti-inflammatory drug-induced enteropathy: United Kingdom pilot data, eng. *Gastrointest Endosc.* 2006 Dec; 64(6):1035; ISSN: 0016-5107

Sidhu, R.; Sanders, D. S.; Sakellariou, V. P., and McAlindon, M. E. Capsule endoscopy and obscure gastrointestinal bleeding: are transfusion dependence and comorbidity further risk factors to predict a diagnosis?, eng. *Am J Gastroenterol.* 2007 Jun; 102(6):1329-30; ISSN: 0002-9270

Spada, C.; Riccioni, M. E., and Costamagna, G. Patients with known small bowel stricture or with symptoms of small bowel obstruction secondary to Crohn's disease should not perform video capsule endoscopy without being previously tested for small bowel patency, eng. *Am J Gastroenterol.* 2007 Jul; 102(7):1542-3; author reply 1543-4; ISSN: 0002-9270

Anonymous. Rapid((R)) Access Real-Time device and Rapid Access software: new tools in the armamentarium of capsule endoscopy, ENG. *Expert Rev Med Devices.* 2007 Jul; 4(4):431-435; ISSN: 1743-4440

Tanaka, S.; Mitsui, K.; Shirakawa, K.; Tatsuguchi, A.; Nakamura, T.; Hayashi, Y.; Sakamoto, C., and Terano, A. Successful retrieval of video capsule endoscopy retained at ileal stenosis of Crohn's disease using double-balloon endoscopy, eng. *J Gastroenterol Hepatol.* 2006 May; 21(5):922-3; ISSN: 0815-9319

Vanderveldt, H. S. and Barkin, J. S. Can findings on wireless capsule endoscopy predict further bleeding?, eng. *Nat Clin Pract Gastroenterol Hepatol.* 2007 Mar; 4(3):132-3; ISSN: 1743-4386 (Electronic).

Viazis, N. and Karamanolis, D. G. Indeterminate colitis—the role of wireless capsule endoscopy, eng. *Aliment Pharmacol Ther.* 2007 Apr 1; 25(7):859; author reply 860; ISSN: 0269-2813

Anonymous. Wireless esophageal pH monitoring is better tolerated than the catheter-based technique: Results from a randomized cross-over trial. *Am. J. Gastroenterol.* 2007; 102(2):239-245; ISSN: 0002-9270.

Balzola, F.; Barbon, V.; Repici, A.; Rizzetto, M.; Clauser, D.; Gandione, M., and Sapino, A. Panenteric IBD-like disease in a patient with regressive autism shown for the first time by the wireless capsule enteroscopy: another piece in the jigsaw of this gut-brain syndrome?, eng. *Am J Gastroenterol.* 2005 Apr; 100(4):979-81; ISSN: 0002-9270

Bizzarri, B.; Fornaroli, F.; Cannizzaro, R.; de' Angelis, N.; Vincenzi, F.; Maffini, V., and de' Angelis, G. L. Endoscopic placement of video capsule in a pediatric population, eng. *Gastrointest Endosc.* 2005 Dec; 62(6):991; ISSN: 0016-5107

Dalla Valle, R.; Fornaroli, F.; de'Angelis, N.; Bizzarri, B., and de'Angelis, G. L. Clinical usefulness of the endoscopic video capsule in patients with obscure gastrointestinal bleeding, eng. *Endoscopy.* 2005 Aug; 37(8):780; author reply 781; ISSN: 0013-726X (Print).

Dubner, S.; Goldin, E., and Dubner, Y. Re: Interference between pacemaker and video capsule endoscopy, eng. *Pacing Clin Electrophysiol.* 2005 Mar; 28(3):261; ISSN: 0147-8389

Ford, R. M.; Affronti, J.; Cohen, R.; Baumgarten, D. A., and Cai, Q. Zenker's diverticulum: a contraindication for wireless capsule endoscopy?, eng. *J Clin Gastroenterol.* 2005 Mar; 39(3):257; ISSN: 0192-0790

Marrero, R. J. and Barkin, J. S. Wireless capsule endoscopy and portal hypertensive intestinal vasculopathy, eng. *Gastrointest Endosc.* 2005 Oct; 62(4):535-7; ISSN: 0016-5107

Nakamura, T. When is the optimal timing for performing video capsule endoscopy for obscure gastrointestinal bleeding?, eng. *J Gastroenterol.* 2005 Mar; 40(3):322-3; ISSN: 0944-1174

Anonymous. Wireless capsule endoscopy and Crohn's disease, eng. *Gut.* 2005 Mar; 54(3):323-6; ISSN: 0017-5749

Studies excluded if not-human

No study identified

Studies excluded if not on WCE

Adebayo, D. and Bjarnason, I. Is non-steroidal anti-inflammatory drug (NSAID) enteropathy clinically more important than NSAID gastropathy?, eng. *Postgrad Med J.* 2006 Mar; 82(965):186-91; ISSN: 1469-0756

Adebayo, D.; Popat, R.; Thjodleifsson, B., and Bjarnason, I. Granulomatous ileitis in a patient with ankylosing spondylitis, eng. *Nat Clin Pract Gastroenterol Hepatol.* 2007 Jun; 4(6):347-51; ISSN: 1743-4386

Ang, D.; Luman, W., and Ooi, C. J. Early experience with double balloon enteroscopy: a leap forward for the gastroenterologist, eng. *Singapore Med J.* 2007 Jan; 48(1):50-60; ISSN: 0037-5675

Averbach, M.; Marques, O. W. Jr; Correa, P. A.; Cappellanes, C. A., and Hashiba, K. Small-bowel angiodysplasia and intestinal bleeding: a diagnostic challenge, eng. *Gastrointest Endosc.* 2006 Dec; 64(6):1008; discussion 1009; ISSN: 0016-5107

Bauditz, J.; Lochs, H., and Voderholzer, W. Macroscopic appearance of intestinal angiodysplasias under antiangiogenic treatment with thalidomide, eng. *Endoscopy.* 2006 Oct; 38(10):1036-9; ISSN: 0013-726X

Bretagne, J. F.; Manfredi, S., and Heresbach, D. [Colorectal cancer screening: present and future.] [Depistage de masse du cancer colorectal: present et avenir.], FRE. *Presse Med.* 2007 Jul-2007 Aug 31; 36(7-8):1054-1063;

Bruining, D. H. and Loftus, E. V. Evolving diagnostic strategies for inflammatory bowel disease, eng. *Curr Gastroenterol Rep.* 2006 Dec; 8(6):478-85; ISSN: 1522-8037 (Print).

Bulfony, A. [Primary adenocarcinoma of jejunum with obscure gastrointestinal bleeding] [Adenocarcinoma primitivo del digiuno ad esteriorizzazione con enterorragia.], ita. *Clin Ter.* 2006 Sep-2006 Oct 31; 157(5):431-4; ISSN: 0009-9074

Chiarugi, M.; Galatioto, C.; Lippolis, P.; Zocco, G., and Seccia, M. Gastrointestinal stromal tumour of the duodenum in childhood: a rare case report, eng. *BMC Cancer.* 2007; 779; ISSN: 1471-2407

Concha, R.; Amaro, R., and Barkin, J. S. Obscure gastrointestinal bleeding: diagnostic and therapeutic approach, eng. *J Clin Gastroenterol.* 2007 Mar; 41(3):242-51; ISSN: 0192-0790

Corona, E.; Hatlebakk, J. G., and Galmiche, J.-P. Novel developments in non-erosive and erosive gastroesophageal reflux disease. *Curr. Opin. Gastroenterol.* 2006; 22(4):399-405; ISSN: 0267-1379.

Croese, J. and Speare, R. Intestinal allergy expels hookworms: seeing is believing, *eng. Trends Parasitol.* 2006 Dec; 22(12):547-50; ISSN: 1471-4922

Das, A. and Leighton, J. A. Is double balloon enteroscopy the best initial imaging method for obscure gastrointestinal bleeding?, *eng. Nat Clin Pract Gastroenterol Hepatol.* 2007 Mar; 4(3):120-1; ISSN: 1743-4386

De Palma, G. D.; Aprea, G.; Rega, M.; Masone, S.; Simeoli, I.; Cutolo, P., and Persico, G. Polypoid vascular malformation of the small intestine, *eng. Gastrointest Endosc.* 2007 Feb; 65(2):328-9; discussion 329; ISSN: 0016-5107

Eisen, G. M. and Schreiner, M. Small-bowel endoscopy. *Endoscopy.* 2007; 39(2):113-117; ISSN: 0013-726X.

Fernandez-Urien, I.; Carretero, C.; Sola, J. J.; Munoz-Navas, M.; Betes, M.; Subtil, J. C., and Armendariz, R. Refractory Whipple's disease, *eng. Gastrointest Endosc.* 2007 Mar; 65(3):521-2, discussion 522; ISSN: 0016-5107

Fortun, P. and Hawkey, C. J. Drug-induced gastrointestinal disorders. *Medicine (GBR).* 2007; 35(4):210-215; ISSN: 1357-3039.

Giovannini, I.; Chiarla, C.; Murazio, M.; Clemente, G.; Giuliani, F., and Nuzzo, G. An extreme case of Heyde syndrome, *eng. Dig Surg.* 2006; 23(5-6):387-8; ISSN: 0253-4886

Gomez, B. J.; Caunedo Alvarez, A.; Redondo, L.; Esteban, J.; Saenz-Dana, M.; Blasco, M.; Hergueta, P.; Rodriguez-Tellez, M.; Romero, R.; Pellicer, F. J., and Herreras, J. M. Modification of pepsinogen I levels and their correlation with gastrointestinal injury after administration of dexibuprofen, ibuprofen or diclofenac: A randomized, open-label, controlled clinical trial. *Int. J. Clin. Pharmacol. Ther.* 2006; 44(4):154-162; ISSN: 0946-1965.

Gralnek, I. M. Endoscopic research: funding opportunities and mechanisms from the ASGE and beyond., *eng. Gastrointest Endosc.* 2006 Dec; 64(6 Suppl):S16-8; ISSN: 0016-5107

Heidt, J.; Langers, A. M.; van der Meer, F. J., and Brouwer, R. E. Thalidomide as treatment for digestive tract angiodysplasias, *eng. Neth J Med.* 2006 Dec; 64(11):425-8; ISSN: 0300-2977

Heine, G. D.; Al-Toma, A.; Mulder, C. J., and Jacobs, M. A. Milestone in gastrointestinal endoscopy: double-balloon enteroscopy of the small bowel, *eng. Scand J Gastroenterol Suppl.* 2006 May; (243):32-8; ISSN: 0085-5928

Hohl, C.; Muhlenbruch, G.; Schmidt, T.; Haage, P., and Gunther, R. W. [Bowel Imaging - A Reevaluation, Part 1.] [Bildgebende Diagnostik des Darms - eine Neubewertung, Teil 1.], *GER. Rofo.* 2007 Jul; 179(7):683-692; ISSN: 1438-9029

Jakobs, R.; Hartmann, D.; Benz, C.; Schilling, D.; Weickert, U.; Eickhoff, A.; Schoenleben, K., and Riemann, J. F. Diagnosis of obscure gastrointestinal bleeding by intra-operative enteroscopy in 81 consecutive patients, *eng. World J Gastroenterol.* 2006 Jan 14; 12(2):313-6; ISSN: 1007-9327

Jewell, D. P. Crohn's disease. *Medicine (GBR).* 2007; 35(5):283-289; ISSN: 1357-3039.

Karagiannis, S.; Kosmadakis, G.; Goulas, S.; Boletis, J., and Mavrogiannis, C. Education and

Imaging. Gastrointestinal: cytomegalovirus enterocolitis, eng. *J Gastroenterol Hepatol.* 2007 Apr; 22(4):594; ISSN: 0815-9319

Krauss, N. and Schuppan, D. Monitoring Nonresponsive Patients Who Have Celiac Disease. *Gastrointest. Endosc. Clin. North Am.* 2006; 16(2):317-327; ISSN: 1052-5157.

Leighton, J. A. and Wallace, M. B. Update on small bowel imaging, eng. *Gastroenterology.* 2007 May; 132(5):1651-4; ISSN: 0016-5085

Manabe, N.; Tanaka, S.; Fukumoto, A.; Nakao, M.; Kamino, D., and Chayama, K. Double-balloon enteroscopy in patients with GI bleeding of obscure origin, eng. *Gastrointest Endosc.* 2006 Jul; 64(1):135-40; ISSN: 0016-5107

Martins, N. B. and Wassef, W. Upper gastrointestinal bleeding, eng. *Curr Opin Gastroenterol.* 2006 Nov; 22(6):612-9; ISSN: 0267-1379

May, A. and Ell, C. Push-and-pull enteroscopy using the double-balloon technique/double-balloon enteroscopy, eng. *Dig Liver Dis.* 2006 Dec; 38(12):932-8; ISSN: 1590-8658

Modlin, I. M.; Latich, I.; Zikusoka, M.; Kidd, M.; Eick, G., and Chan, A. K. Gastrointestinal carcinoids: the evolution of diagnostic strategies, eng. *J Clin Gastroenterol.* 2006 Aug; 40(7):572-82; ISSN: 0192-0790.

Mrevlje, Z. and Stabuc, B. Pitfalls in diagnosing small bowel carcinoid tumors, eng. *J BUON.* 2006 Jan-2006 Mar 31; 11(1):83-6; ISSN: 1107-0625.

Oshitani, N.; Yukawa, T.; Yamagami, H.; Inagawa, M.; Kamata, N.; Watanabe, K.; Jinno, Y.; Fujiwara, Y.; Higuchi, K., and Arakawa, T. Evaluation of deep small bowel involvement by double-balloon enteroscopy in Crohn's disease, eng. *Am J Gastroenterol.* 2006 Jul; 101(7):1484-9; ISSN: 0002-9270.

Perez-Cuadrado, E.; Mas, P.; Hallal, H.; Shanabo, J.; Munoz, E.; Ortega, I.; Lopez Martin, A.; Torrella, E.; Lopez Higuera, A.; Martin, A., and Carballo, F. Double-balloon enteroscopy: A descriptive study of 50 explorations: ENTEROSCOPIA DE DOBLE BALON: ESTUDIO DESCRIPTIVO DE 50 EXPLORACIONES. *Rev. Esp. Enferm. Dig.* 2006; 98(2):73-81; ISSN: 1130-0108.

Rao, R. and Shashidhar, H. Intestinal lymphangiectasia presenting as abdominal mass, eng. *Gastrointest Endosc.* 2007 Mar; 65(3):522-3, discussion 523; ISSN: 0016-5107

Rex, D. K.; Talley, N. J.; Katz, P. O.; Hanauer, S. B., and Sandborn, W. J. Report from the ACG: Highlights of the 71st Annual Scientific Meeting of the American College of Gastroenterology, October 20-25, Las Vegas, NV. *Rev. Gastroenterol. Disord.* 2006; 6(4):227-242; ISSN: 1533-001X.

Riemann, J. F.; Hartmann, D.; Schilling, D.; Damian, U.; Eickhoff, A., and Weickert, U. Frequency of small bowel polyps in patients with duodenal adenoma but without familial adenomatous polyposis, eng. *Z Gastroenterol.* 2006 Mar; 44(3):235-8; ISSN: 0044-2771.

Satsangi, J.; Silverberg, M. S.; Vermeire, S., and Colombel, J.-F. The Montreal classification of inflammatory bowel disease: Controversies, consensus, and implications. *Gut.* 2006; 55(6):749-753; ISSN: 0017-5749.

Spyridonos, P.; Vilarino, F.; Vitria, J.; Azpiroz, F., and Radeva, P. Anisotropic feature extraction from endoluminal images for detection of intestinal contractions, eng. *Med Image*

Comput Assist Interv Int Conf Med Image Comput Assist Interv. 2006; 9(Pt 2):161-8.

Stange, E. F.; Travis, S. P. L.; Vermeire, S.; Beglinger, C.; Kupcinkas, L.; Geboes, K.; Barakauskiene, A.; Villanacci, V.; Von Herbay, A.; Warren, B. F.; Gasche, C.; Tilg, H.; Schreiber, S. W.; Scholmerich, J., and Reinisch, W. European evidence based consensus on the diagnosis and management of Crohn's disease: Definitions and diagnosis. *Gut*. 2006; 55(SUPPL. 1):i1-i15; ISSN: 0017-5749.

Suzuki, T.; Matsushima, M.; Okita, I.; Ito, H.; Gocho, S.; Tajima, H.; Tokiwa, K.; Teraoka, H.; Watanabe, K.; Shirai, T., and Mine, T. Clinical utility of double-balloon enteroscopy for small intestinal bleeding, eng. *Dig Dis Sci*. 2007 Aug; 52(8):1914-9; ISSN: 0163-2116

Van Tuyl, S. A.; Letteboer, T. G.; Rogge-Wolf, C.; Kuipers, E. J.; Snijder, R. J.; Westermann, C. J., and Stolk, M. F. Assessment of intestinal vascular malformations in patients with hereditary hemorrhagic teleangiectasia and anemia, eng. *Eur J Gastroenterol Hepatol*. 2007 Feb; 19(2):153-8; ISSN: 0954-691X

Verschuur, E. M. L.; Kuipers, E. J., and Siersema, P. D. Nurses working in GI and endoscopic practice: a review. *Gastrointest. Endosc*. 2007; 65(3):469-479; ISSN: 0016-5107.

Villa, F.; Signorelli, C.; Rondonotti, E., and de Franchis, R. Preparations and Prokinetics. *Gastrointest. Endosc. Clin. North Am*. 2006; 16(2):211-220; ISSN: 1052-5157.

Wardi, J.; Shahmurov, M.; Czerniak, A., and Avni, Y. Clinical challenges and images in GI. Capillary hemangioma of small intestine, eng. *Gastroenterology*. 2007 May; 132(5):1656, 2084; ISSN: 0016-5085.

Weersma, R. K.; Limburg, A. J.; Karrenbeld, A., and Koornstra, J. J. Editor's quiz: iron deficiency anaemia 10 years after small bowel resection in infancy, eng. *Gut*. 2007 Apr; 56(4):463, 488; ISSN: 0017-5749

Arena, A.; Boulougoura, M.; Chowdrey, H. S.; Dario, P.; Harendt, C.; Irion, K. M.; Kodogiannis, V.; Lenaerts, B.; Menciassi, A.; Puers, R.; Scherjon, C., and Turgis, D. Intracorporeal Videoprobe (IVP), eng. *Stud Health Technol Inform*. 2005; 114167-74; ISSN: 0926-9630.

Biering, H.; Bauditz, J.; Brenner, N.; Stein, H.; Lochs, H., and Strasburger, C. J. Primary neuroendocrine carcinoma of inguinal lymph node, eng. *Horm Res*. 2005; 64(1):16-9; ISSN: 0301-0163.

De Palma GD, Rega M Masone S Persico F Siciliano S Patrone F Matantuono L Persico G. Mucosal abnormalities of the small bowel in patients with cirrhosis and portal hypertension: a capsule endoscopy study. *Gastrointestinal Endoscopy*. 2005; 62(4):529-34; ISSN: CN-00530599.

Fortun, P. J. and Hawkey, C. J. Nonsteroidal antiinflammatory drugs and the small intestine. *Curr. Opin. Gastroenterol*. 2005; 21(2):169-175; ISSN: 0267-1379.

Graham, D. Y.; Opekun, A. R.; Willingham, F. F., and Qureshi, W. A. Visible small-intestinal mucosal injury in chronic NSAID users, eng. *Clin Gastroenterol Hepatol*. 2005 Jan; 3(1):55-9; ISSN: 1542-3565.

Grosbois, B.; Decaux, O.; Cador, B.; Cazalets, C., and Jegou, P. [Human iron deficiency] [Les carences en fer chez l'homme.], fre. *Bull Acad Natl Med*. 2005 Nov; 189(8):1649-63; discussion 1663-4; ISSN: 0001-4079.

Hatoum, O. A.; Binion, D. G.; Phillips, S. A.; O'Loughlin, C.; Komorowski, R. A.; Gutterman, D. D., and Otterson, M. F. Radiation induced small bowel "web" formation is associated with acquired microvascular dysfunction, *eng. Gut.* 2005 Dec; 54(12):1797-800; ISSN: 0017-5749.

Ikeda, K. and Swain, P. Future innovations and techniques: Endoscopic hemostasis for UGI, non-variceal bleeding. *Tech. Gastrointest. Endosc.* 2005; 7(3 SPEC. ISS.):164-170; ISSN: 1096-2883.

Imbesi, J. J. and Kurtz, R. C. A multidisciplinary approach to gastrointestinal bleeding in cancer patients. *J. Supportive Oncol.* 2005; 3(2):101-110; ISSN: 1544-6794.

Kelly, M. E.; McMahon, L. E.; Jaroszewski, D. E.; Yousfi, M. M.; De Petris, G., and Swain, J. M. Small-bowel diaphragm disease: seven surgical cases, *eng. Arch Surg.* 2005 Dec; 140(12):1162-6; ISSN: 0004-0010

Keuchel, M. and Hagenmuller, F. Small bowel endoscopy, *eng. Endoscopy.* 2005 Feb; 37(2):122-32; ISSN: 0013-726X

Kornbluth, A.; Colombel, J. F.; Leighton, J. A., and Loftus, E. ICCE consensus for inflammatory bowel disease. *Endoscopy.* 2005; 37(10):1051-1054; ISSN: 0013-726X.

Kovacs, T. O. G. Small bowel bleeding. *Curr. Treat. Options Gastroenterol.* 2005; 8(1):31-38; ISSN: 1092-8472.

Kruger, S.; Noack, F.; Blochle, C., and Feller, A. C. Primary malignant melanoma of the small bowel: a case report and review of the literature, *eng. Tumori.* 2005 Jan-2005 Feb 28; 91(1):73-6; ISSN: 0300-8916.

Lee, S. K. and Green, P. H. Endoscopy in celiac disease, *eng. Curr Opin Gastroenterol.* 2005 Sep; 21(5):589-94; ISSN: 0267-1379.

Leighton, J. A. and Loftus Jr., E. V. Evolving diagnostic modalities in inflammatory bowel disease. *Curr. Gastroenterol. Rep.* 2005; 7(6):467-474; ISSN: 1522-8037.

Marek, T. A. Gastrointestinal bleeding. *Endoscopy.* 2005; 37(11):1098-1104; ISSN: 0013-726X.

Modlin, I. M.; Kidd, M.; Latich, I.; Zikusoka, M. N., and Shapiro, M. D. Current status of gastrointestinal carcinoids. *Gastroenterology.* 2005; 128(6):1717-1751; ISSN: 0016-5085.

Mussi, C.; Caprotti, R.; Scaini, A.; Angelini, C.; Crippa, S.; Uggeri, F.; Uggeri, F., and Sartori, P. Management of small bowel tumors: personal experience and new diagnostic tools, *eng. Int Surg.* 2005 Sep-2005 Oct 31;

Pei, K.; Zemon, H.; Venbrux, A., and Brody, F. Laparoendoscopic techniques for occult gastrointestinal bleeding, *eng. J Laparoendosc Adv Surg Tech A.* 2005 Dec; 15(6):615-9; ISSN: 1092-6429.

Strate, L. L. Lower GI bleeding: Epidemiology and diagnosis. *Gastroenterol. Clin. North Am.* 2005; 34(4):643-664; ISSN: 0889-8553.

Taal, B. G. and Smits, M. Developments in diagnosis and treatment of metastatic midgut carcinoid tumours: A review. *Minerva Gastroenterol. Dietol.* 2005; 51(4):335-344; ISSN: 0026-4776.

Veltzke-Schlieker, W. and Rosch, T. UEGW report, Prague 2004: Endoscopic highlights. *Endoscopy*. 2005; 37(4):367-377; ISSN: 0013-726X.

Yamamoto, H. and Kita, H. Enteroscopy, *eng. J Gastroenterol*. 2005 Jun; 40(6):555-62; ISSN: 0944-1174.

Studies excluded if the topic was not Obscure Gastrointestinal Bleeding (OGIB), Crohn's disease, familial polyposis and celiac disease

Agrawal, G. A.; Johnson, P. T., and Fishman, E. K. Intermittent small bowel obstruction with retained endoscopic capsule: MDCT and plain radiographic appearance, *eng. Emerg Radiol*. 2007 Mar; 13(6):319-21; ISSN: 1070-3004.

Antao, B.; Bishop, J.; Shawis, R., and Thomson, M. Clinical application and diagnostic yield of wireless capsule endoscopy in children, *eng. J Laparoendosc Adv Surg Tech A*. 2007 Jun; 17(3):364-70; ISSN: 1092-6429.

Antonietti, M.; Savoye, G.; Leclaire, S.; Hecketsweiler, P., and Ben-Soussan, E. A video capsule attached to a probe can be used for prolonged stationary endoscopic monitoring, *eng. Endoscopy*. 2006 Mar; 38(3):289; ISSN: 0013-726X .

Badran, A. M.; Vahedi, K.; Berrebi, D.; Catana, D.; De Lagausie, P.; Drouet, L.; Ferkadji, F., and Mougnot, J. F. Pediatric ampullar and small bowel blue rubber bleb nevus syndrome diagnosed by wireless capsule endoscopy, *eng. J Pediatr Gastroenterol Nutr*. 2007 Feb; 44(2):283-6; ISSN: 1536-4801.

Balachandran, P. and Prasad, V. G. Intestinal parasites seen on capsule endoscopy, *eng. Gastrointest Endosc*. 2006 Oct; 64(4):651; ISSN: 0016-5107.

Bayraktar, Y.; Ersoy, O., and Sokmensuer, C. The findings of capsule endoscopy in patients with common variable immunodeficiency syndrome, *eng. Hepatogastroenterology*. 2007 Jun; 54(76):1034-7; ISSN: 0172-6390.

Brown, G.; Fraser, C.; Schofield, G.; Taylor, S.; Bartram, C.; Phillips, R., and Saunders, B. Video capsule endoscopy in peutz-jeghers syndrome: a blinded comparison with barium follow-through for detection of small-bowel polyps, *eng. Endoscopy*. 2006 Apr; 38(4):385-90; ISSN: 0013-726X .

Caddy, G. R.; Moran, L.; Chong, A. K.; Miller, A. M.; Taylor, A. C., and Desmond, P. V. The effect of erythromycin on video capsule endoscopy intestinal-transit time, *eng. Gastrointest Endosc*. 2006 Feb; 63(2):262-6; ISSN: 0016-5107.

Calabrese, C.; Fabbri, A.; Gionchetti, P.; Rizzello, F.; Morselli, C.; Liguori, G.; Poggioli, G.; Campieri, M., and Di Febo, G. Controlled study using wireless capsule endoscopy for the evaluation of the small intestine in chronic refractory pouchitis, *eng. Aliment Pharmacol Ther*. 2007 Jun 1; 25(11):1311-6; ISSN: 0269-2813 .

Carpi, F.; Galbiati, S., and Carpi, A. Magnetic shells for gastrointestinal endoscopic capsules as a means to control their motion, *eng. Biomed Pharmacother*. 2006 Sep; 60(8):370-4; ISSN: 0753-3322.

Chamberlain, S. M.; Patel, J.; Carter Balart, J.; Gossage, J. R. Jr, and Sridhar, S. Evaluation of patients with hereditary hemorrhagic telangiectasia with video capsule endoscopy: a single-center prospective study, *eng. Endoscopy*. 2007 Jun; 39(6):516-20; ISSN: 1438-8812.

Chamouard, P.; Nehme-Schuster, H.; Simler, J. M.; Finck, G.; Baumann, R., and Pasquali, J. L. Videocapsule endoscopy is useful for the diagnosis of intestinal lymphangiectasia, *eng. Dig Liver Dis.* 2006 Sep; 38(9):699-703.

Chao, C. C. and Ray, M. L. Education and imaging. Gastrointestinal: Hookworm diagnosed by capsule endoscopy, *eng. J Gastroenterol Hepatol.* 2006 Nov; 21(11):1754; ISSN: 0815-9319.

Chen, G. C.; Lee-Henderson, M.; Mehdizadeh, S.; Goltzer, O.; Shen, J.; Sul, J., and Jutabha, R. Novel external sensor array for capsule endoscopy, *eng. Endoscopy.* 2006 Jul; 38(7):752-4; ISSN: 0013-726X .

Chen, T. H.; Chen, T. Y.; Shyu, L. Y.; Lin, C. K., and Lin, C. C. Hookworm infestation diagnosed by capsule endoscopy (with video), *eng. Gastrointest Endosc.* 2006 Aug; 64(2):277-8; ISSN: 0016-5107.

De Francesco, V.; Stoppino, G.; Tonti, P.; D'Agnessa, M. R.; Castriota, M.; Panella, C., and Ierardi, E. Ileal metastasis from thoracic melanoma disclosed by video capsule endoscopy: an unusual but not extraordinary source of obscure bleeding, *ENG. Endoscopy.* 2007 Apr 18; ISSN: 1438-8812.

Dominguez, E. P.; Choi, Y.; Raijman, I. L., and Sweeney, J. F. Laparoscopic approach for the retrieval of retained video capsule endoscopy, *eng. JSLS.* 2006 Oct-2006 Dec 31; 10(4):496-8; ISSN: 1086-8089.

Drastich, P. [Capsule endoscopy—the past, presence, and future] [Kapslova endoskopie—minulost, pritomnost a budoucnost.], *cze. Cas Lek Cesk.* 2006; 145(6):432-6; ISSN: 0008-7335.

Dubner, S.; Dubner, Y.; Rubio, H., and Goldin, E. Electromagnetic interference from wireless video-capsule endoscopy on implantable cardioverter-defibrillators, *eng. Pacing Clin Electrophysiol.* 2007 Apr; 30(4):472-5; ISSN: 0147-8389.

Eisen, G. M.; Eliakim, R.; Zaman, A.; Schwartz, J.; Faigel, D.; Rondonotti, E.; Villa, F.; Weizman, E.; Yassin, K., and deFranchis, R. The accuracy of PillCam ESO capsule endoscopy versus conventional upper endoscopy for the diagnosis of esophageal varices: A prospective three-center pilot study. *Endoscopy.* 2006; 38(1):31-35; ISSN: 0013-726X.

Eliakim, R.; Fireman, Z.; Gralnek, I. M.; Yassin, K.; Waterman, M.; Kopelman, Y.; Lachter, J.; Koslowsky, B., and Adler, S. N. Evaluation of the PillCam Colon capsule in the detection of colonic pathology: results of the first multicenter, prospective, comparative study, *eng. Endoscopy.* 2006 Oct; 38(10):963-70; ISSN: 0013-726X.

Enns, R. Capsule endoscopy: specifics for enhanced performance—Part II, *eng. Can J Gastroenterol.* 2006 Sep; 20(9):575-7; ISSN: 0835-7900.

Ewertsen, C.; Svendsen, C. B.; Svendsen, L. B.; Hansen, C. P.; Gustafsen, J. H., and Jendresen, M. B. [Is screening of wireless capsule endoscopies by non-physicians feasible?] [Er screening af kapselendoskopiske undersøgelser udført af ikkelaegeligt personale anvendelig?], *dan. Ugeskr Laeger.* 2006 Oct 9; 168(41):3530-3; ISSN: 1603-6824.

Fenkel, J. M.; Grasso, M. A.; Goldberg, E. M., and Feller, E. D. Capsule endoscopy is safe in patients with pulsatile Novacor PC left ventricular assist device, *eng. Gastrointest Endosc.* 2007 Mar; 65(3):559-60; author reply 560; ISSN: 0016-5107.

Floro, L.; Pak, G.; Sreter, L., and Tulassay, Z. Wireless capsule endoscopy in the diagnosis of helminthiasis, eng. *Gastrointest Endosc.* 2007 Jun; 65(7):1078; discussion 1079; ISSN: 0016-5107.

Gardner, T. B.; Bensen, S. P.; Toor, A., and Anderson, P. B. Video capsule endoscopy to diagnose metastatic melanoma, eng. *Dig Dis Sci.* 2007 Apr; 52(4):1036-7; ISSN: 0163-2116.

Garza, A.; Patel, T., and Brady, P. Diagnosis of malignant hemangioendothelioma of the small intestine with capsule endoscopy, eng. *Dig Dis Sci.* 2007 Mar; 52(3):852-5; ISSN: 0163-2116.

Ge, Z. Z.; Chen, H. Y.; Gao, Y. J.; Gu, J. L.; Hu, Y. B., and Xiao, S. D. [Clinical application of wireless capsule endoscopy in pediatric and adolescent patients], chi. *Zhonghua Er Ke Za Zhi.* 2006 Sep; 44(9):676-9; ISSN: 0578-1310.

Ge, Z.-Z.; Chen, H.-Y.; Goa, Y.-J.; Hu, Y.-B., and Xiao, S.-D. The role of simeticone in small-bowel preparation for capsule endoscopy. *Endoscopy.* 2006; 38(8):836-840; ISSN: 0013-726X.

Gerson, L. and Lin, O. S. Cost-benefit analysis of capsule endoscopy compared with standard upper endoscopy for the detection of Barrett's esophagus, eng. *Clin Gastroenterol Hepatol.* 2007 Mar; 5(3):319-25; ISSN: 1542-7714.

Goldstein, J. L.; Eisen, G. M.; Lewis, B.; Gralnek, I. M.; Aisenberg, J.; Bhadra, P., and Berger, M. F. Small bowel mucosal injury is reduced in healthy subjects treated with celecoxib compared with ibuprofen plus omeprazole, as assessed by video capsule endoscopy, eng. *Aliment Pharmacol Ther.* 2007 May 15; 25(10):1211-22; ISSN: 0269-2813.

Gonzalez-Suarez, B.; Galter, S., and Balanzo, J. [Wireless capsule endoscopy: basic principles and clinical utility.] [Capsula endoscopica: fundamentos y utilidad clinica.], spa. *Cir Esp.* 2007 Jun; 81(6):299-306; ISSN: 0009-739X .

Gralnek, I. M.; Rabinovitz, R.; Afik, D., and Eliakim, R. A simplified ingestion procedure for esophageal capsule endoscopy: initial evaluation in healthy volunteers, eng. *Endoscopy.* 2006 Sep; 38(9):913-8; ISSN: 0013-726X .

Ho, K. K. and Joyce, A. M. Complications of capsule endoscopy, eng. *Gastrointest Endosc Clin N Am.* 2007 Jan; 17(1):169-78, viii-ix; ISSN: 1052-5157.

Hogan, R. B.; Ahmad, N.; Hogan, R. B. 3rd; Hensley, S. D.; Phillips, P.; Doolittle, P., and Reimund, E. Video capsule endoscopy detection of jejunal carcinoid in life-threatening hemorrhage, first trimester pregnancy, eng. *Gastrointest Endosc.* 2007 Jul; 66(1):205-7; ISSN: 0016-5107 .

Holden, J. P.; Dureja, P.; Pfau, P. R.; Schwartz, D. C.; Reichelderfer, M.; Judd, R. H.; Danko, I.; Iyer, L. V., and Gopal, D. V. Endoscopic placement of the small-bowel video capsule by using a capsule endoscope delivery device, eng. *Gastrointest Endosc.* 2007 May; 65(6):842-7; ISSN: 0016-5107.

Hosono, S.; Ohira, M.; Maeda, K.; Muguruma, K.; Nishihara, T.; Inoue, T.; Yashiro, M., and Hirakawa, K. Synchronous adenocarcinomas of the ileum and transverse colon detected by capsule endoscopy: report of a case, eng. *Surg Today.* 2006; 36(7):663-5; ISSN: 0941-1291.

Kong, H.; Kim, Y. S.; Hyun, J. J.; Cho, Y. J.; Keum, B.; Jeon, Y. T.; Lee, H. S.; Chun, H. J.; Um, S. H.; Lee, S. W.; Choi, J. H.; Kim, C. D.; Ryu, H. S., and Hyun, J. H. Limited ability of capsule endoscopy to detect normally positioned duodenal papilla, eng. *Gastrointest Endosc.* 2006 Oct; 64(4):538-41; ISSN: 0016-5107.

Lapalus, M.-G.; Dumortier, J.; Fumex, F.; Roman, S.; Lot, M.; Prost, B.; Mion, F., and Ponchon, T. Esophageal capsule endoscopy versus esophagogastroduodenoscopy for evaluating portal hypertension: A prospective comparative study of performance and tolerance. *Endoscopy.* 2006; 38(1):36-41; ISSN: 0013-726X.

Leighton, J. A. Recent advances in endoscopic capsule imaging: See what we have been missing. *Rev. Gastroenterol. Disord.* 2006; 6(SUPPL. 1):S19-S27; ISSN: 1533-001X.

Lenaerts, B. and Puers, R. An inductive power link for a wireless endoscope, eng. *Biosens Bioelectron.* 2007 Feb 15; 22(7):1390-5; ISSN: 0956-5663.

Lin, M. C.; Dung, L. R., and Weng, P. K. An ultra-low-power image compressor for capsule endoscope, eng. *Biomed Eng Online.* 2006; 514; ISSN: 1475-925X .

Lin, O. S.; Schembre, D. B.; Mergener, K.; Spaulding, W.; Lomah, N.; Ayub, K.; Brandabur, J. J.; Bredfeldt, J.; Drennan, F.; Gluck, M.; Jiranek, G. C.; McCormick, S. E.; Patterson, D., and Kozarek, R. A. Blinded comparison of esophageal capsule endoscopy versus conventional endoscopy for a diagnosis of Barrett's esophagus in patients with chronic gastroesophageal reflux. *Gastrointest. Endosc.* 2007; 65(4):577-583; ISSN: 0016-5107.

Lykke, J.; Hansen, M. B.; Ovesen, H., and Meisner, S. [Capsule endoscopy detection of metastasis of a malignant melanoma in the small intestine] [Kapselendoskopisk pavisning af malignt melanom-metastase i tyndtarmen.], dan. *Ugeskr Laeger.* 2006 Oct 9; 168(41):3533-4; ISSN: 1603-6824 .

Magdeburg, R.; Riester, T.; Hummel, F.; Lohr, M.; Post, S., and Sturm, J. Ileus secondary to wireless capsule enteroscopy, eng. *Int J Colorectal Dis.* 2006 Sep; 21(6):610-3; ISSN: 0179-1958.

Marchese, M.; Spada, C.; Iacopini, F.; Familiari, P.; Shah, S. G.; Tringali, A., and Costamagna, G. Nonendoscopic transnasal placement of a wireless capsule for esophageal pH monitoring: feasibility, safety, and efficacy of a manometry-guided procedure, eng. *Endoscopy.* 2006 Aug; 38(8):813-8; ISSN: 0013-726X .

Martines, H.; Fanciulli, E., and Menardo, G. Incidental video-capsule diagnosis of small-bowel *Taenia saginata* in a patient with recurrent hemorrhage due to angiodysplasias, eng. *Endoscopy.* 2006; 38 Suppl 2E35; ISSN: 1438-8812.

Matas, J. L.; Asteinza, M.; Loscos, J. M.; Fernandez, S.; Ramirez-Armengol, J. A., and Diaz-Rubio, M. Diagnostic yield and safety of capsule endoscopy, eng. spa. *Rev Esp Enferm Dig.* 2006 Sep; 98(9):666-73; ISSN: 1130-0108.

Maunoury, V.; Savoye, G.; Bourreille, A.; Bouhnik, Y.; Jarry, M.; Sacher-Huvelin, S.; Soussan, E. B.; Lerebours, E.; Galmiche, J. P., and Colombel, J. F. Value of wireless capsule endoscopy in patients with indeterminate colitis (inflammatory bowel disease type unclassified), eng. *Inflamm Bowel Dis.* 2007 Feb; 13(2):152-5; ISSN: 1078-0998.

Moglia, A.; Menciassi, A.; Schurr, M. O., and Dario, P. Wireless capsule endoscopy: from diagnostic devices to multipurpose robotic systems, eng. *Biomed Microdevices.* 2007 Apr; 9(2):235-43; ISSN: 1387-2176.

Moy, L. and Levine, J. Wireless capsule endoscopy in the pediatric age group: experience and complications, eng. *J Pediatr Gastroenterol Nutr.* 2007 Apr; 44(4):516-20; ISSN: 1536-4801.

Nagri, S.; Duddempudi, S.; Anand, S., and Arya, Y. Video capsule endoscopy in the diagnosis of gastrointestinal Kaposi's sarcoma, ENG. *Endoscopy.* 2007 Mar 13; ISSN: 0013-726X .

Nakamura, M.; Niwa, Y.; Ohmiya, N.; Arakawa, D.; Honda, W.; Miyahara, R.; Matsuura, T.; Ando, T.; Maeda, O.; Itoh, A.; Hirooka, Y., and Goto, H. Small bowel tuberculosis diagnosed by the combination of video capsule endoscopy and double balloon enteroscopy, eng. *Eur J Gastroenterol Hepatol.* 2007 Jul; 19(7):595-8; ISSN: 0954-691X .

Neumann, S.; Schoppmeyer, K.; Lange, T.; Wiedmann, M.; Golsong, J.; Tannapfel, A.; Mossner, J.; Niederwieser, D., and Caca, K. Wireless capsule endoscopy for diagnosis of acute intestinal graft-versus-host disease, eng. *Gastrointest Endosc.* 2007 Mar; 65(3):403-9; ISSN: 0016-5107.

Patel, V. G.; Babalola, O. A.; Martin, D. M.; Fortson, J. K., and Weaver, W. L. Video capsule endoscopy: clinical relevance of capsule endoscopy findings, eng. *Am Surg.* 2006 Jun; 72(6):546-51; ISSN: 0003-1348.

Pelargonio, G.; Dello Russo, A.; Pace, M.; Casella, M.; Lecca, G.; Riccioni, M. E., and Bellocci, F. Use of video capsule endoscopy in a patient with an implantable cardiac defibrillator, eng. *Europace.* 2006 Dec; 8(12):1062-3; ISSN: 1099-5129.

Pennazio, M. Capsule endoscopy: where are we after 6 years of clinical use?, eng. *Dig Liver Dis.* 2006 Dec; 38(12):867-78; ISSN: 1590-8658.

Prakoso, E. and Selby, W. S. Capsule endoscopy in patients with malignant melanoma, eng. *Am J Gastroenterol.* 2007 Jun; 102(6):1204-8; ISSN: 0002-9270.

Preud'Homme, D. L.; Michail, S.; Hodges, C.; Milliken, T., and Mezzoff, A. G. Use of wireless capsule endoscopy in the management of severe Henoch-Schonlein purpura, eng. *Pediatrics.* 2006 Sep; 118(3):e904-6; ISSN: 1098-4275.

Quentin, V.; Lermite, E.; Lebigot, J.; Marannes, M. Z.; Arnaud, J. P., and Boyer, J. Small bowel cavernous hemangioma: wireless capsule endoscopy diagnosis of a surgical case, eng. *Gastrointest Endosc.* 2007 Mar; 65(3):550-2; ISSN: 0016-5107.

Racz, I.; Janoki, M., and Kovacs, V. Measurement of small-bowel polyp size in patients with Peutz-Jeghers syndrome by using reference granules during video capsule endoscopy, ENG. *Endoscopy.* 2007 Feb 7; ISSN.

Riegler, G.; Esposito, I.; Esposito, P.; Bennato, R.; Bassi, M.; Ursillo, A., and Balzano, A. Wireless capsule enteroscopy (Given) in a case of Cowden syndrome, eng. *Dig Liver Dis.* 2006 Feb; 38(2):151-2; ISSN: 1590-8658.

Riemann, J. F. and Rosenbaum, A. [Bowel imaging—capsule endoscopy] [Darmdiagnostik—Kapselendoskopie.], ger. *Schweiz Rundsch Med Prax.* 2006 Dec 13; 95(50):1979-82; ISSN: 1013-2058.

Rivet, C.; Lapalus, M. G.; Dumortier, J.; Le Gall, C.; Budin, C.; Bouvier, R.; Ponchon, T., and Lachaux, A. Use of capsule endoscopy in children with primary intestinal lymphangiectasia, eng. *Gastrointest Endosc.* 2006 Oct; 64(4):649-50; ISSN: 0016-5107.

Rubenstein, J. H.; Inadomi, J. M.; Brill, J. V., and Eisen, G. M. Cost utility of screening for Barrett's esophagus with esophageal capsule endoscopy versus conventional upper endoscopy, eng. *Clin Gastroenterol Hepatol.* 2007 Mar; 5(3):312-8; ISSN: 1542-7714.

Sanchez-Yague, A.; Caunedo-Alvarez, A.; Romero-Castro, R.; Romero-Vazquez, J.; Antunez-Infante, A.; Pellicer-Bautista, F., and Herrerias-Gutierrez, J. M. Esophageal tumor diagnosed by capsule endoscopy, eng. *Endoscopy.* 2006 Jul; 38(7):765; ISSN: 0013-726X .

Sapoznikov, B.; Morgenstern, S.; Raanani, P.; Aviram, A.; Rabizadeh, E.; Prokocimer, M., and Niv, Y. Follicular lymphoma with extensive gastrointestinal tract involvement: follow-up by capsule endoscopy, eng. *Dig Dis Sci.* 2007 Apr; 52(4):1031-5; ISSN: 0163-2116.

Schoofs, N.; Deviere, J., and Van Gossum, A. PillCam colon capsule endoscopy compared with colonoscopy for colorectal tumor diagnosis: a prospective pilot study, eng. *Endoscopy.* 2006 Oct; 38(10):971-7; ISSN: 0013-726X.

Schwartz, G. D. and Barkin, J. S. Small-bowel tumors detected by wireless capsule endoscopy, eng. *Dig Dis Sci.* 2007 Apr; 52(4):1026-30; ISSN: 0163-2116.

Seidman, E. G. and Dirks, M. H. Capsule Endoscopy in the Pediatric Patient, ENG. *Curr Treat Options Gastroenterol.* 2006 Sep; 9(5):416-422; ISSN: 1092-8472.

Selvasekar, C. R.; Hochman, D. J., and Larson, D. W. Capsule endoscopy: a note of caution, eng. *Surgery.* 2007 Jan; 141(1):123-4; ISSN: 0039-6060.

Shamir, R.; Hino, B.; Hartman, C.; Berkowitz, D.; Eshach-Adiv, O., and Eliakim, R. Wireless video capsule in pediatric patients with functional abdominal pain, eng. *J Pediatr Gastroenterol Nutr.* 2007 Jan; 44(1):45-50; ISSN: 1536-4801.

Shim, K. N.; Kim, Y. S.; Kim, K. J.; Kim, Y. H.; Kim, T. I.; Do, J. H.; Ryu, J. K.; Moon, J. S.; Park, S. H.; Hee Park, C.; Lee, K. M.; Lee, I. S.; Chun, H. J.; Jung, I. S., and Choi, M. G. Abdominal pain accompanied by weight loss may increase the diagnostic yield of capsule endoscopy: a Korean multicenter study, eng. *Scand J Gastroenterol.* 2006 Aug; 41(8):983-8; ISSN: 0036-5521.

Shiotani, A.; Opekun, A. R., and Graham, D. Y. Visualization of the small intestine using capsule endoscopy in healthy subjects, eng. *Dig Dis Sci.* 2007 Apr; 52(4):1019-25; ISSN: 0163-2116.

Sidhu, R.; Sanders, D. S.; Kapur, K.; Hurlstone, D. P., and McAlindon, M. E. Capsule endoscopy changes patient management in routine clinical practice, eng. *Dig Dis Sci.* 2007 May; 52(5):1382-6; ISSN: 0163-2116.

Sidhu, R.; Sanders, D. S.; Kapur, K.; Marshall, L.; Hurlstone, D. P., and McAlindon, M. E. Capsule endoscopy: is there a role for nurses as physician extenders?, eng. *Gastroenterol Nurs.* 2007 Jan-2007 Feb 28; 30(1):45-8; ISSN: 1042-895X .

Spada, C.; Pirozzi, G. A.; Riccioni, M. E.; Iacopini, F.; Marchese, M., and Costamagna, G. Capsule endoscopy in patients with chronic abdominal pain, eng. *Dig Liver Dis.* 2006 Sep; 38(9):696-8; ISSN: 1590-8658.

Spada, C.; Shah, S. K.; Riccioni, M. E.; Spera, G.; Marchese, M.; Iacopini, F.; Familiari, P., and Costamagna, G. Video capsule endoscopy in patients with known or suspected small bowel stricture previously tested with the dissolving patency capsule, eng. *J Clin Gastroenterol.* 2007 Jul; 41(6):576-82; ISSN: 0192-0790.

Stancanelli, B.; Vita, A.; Vinci, M.; Magnano, A., and Purrello, F. Bleeding of small bowel in Henoch-Schonlein syndrome: the successful diagnostic role of video capsule endoscopy, eng. *Am J Med.* 2006 Jan; 119(1):82-4; ISSN: 1555-7162.

Stenschke, F.; Nemetz, A., and Dancygier, H. Chronic abdominal pain aggravated by eating: diagnosis by video capsule endoscopy, eng. *Gut.* 2006 Apr; 55(4):443, 497; ISSN: 0017-5749.

Strosberg, J. R.; Shibata, D., and Kvols, L. K. Intermittent bowel obstruction due to a retained wireless capsule endoscope in a patient with a small bowel carcinoid tumour, eng. *Can J Gastroenterol.* 2007 Feb; 21(2):113-5; ISSN: 0835-7900.

Sturniolo, G. C.; Di Leo, V.; Vettorato, M. G.; De Boni, M.; Lamboglia, F.; De Bona, M.; Bellumat, A.; Martines, D., and D'Inca, R. Small bowel exploration by wireless capsule endoscopy: results from 314 procedures, eng. *Am J Med.* 2006 Apr; 119(4):341-7; ISSN: 1555-7162.

Tabbers, M. M.; Bruin, K. F.; Taminiau, J. A.; Norbruis, O. F., and Benninga, M. A. An unexpected finding in a child with rectal blood loss using video capsule endoscopy, eng. *J Pediatr.* 2006 Apr; 165(4):270-2; ISSN: 0340-6199.

Thomson, M.; Fritscher-Ravens, A.; Mylonaki, M.; Swain, P.; Eltumi, M.; Heuschkel, R.; Murch, S.; McAlindon, M., and Furman, M. Wireless capsule endoscopy in children: a study to assess diagnostic yield in small bowel disease in paediatric patients, eng. *J Pediatr Gastroenterol Nutr.* 2007 Feb; 44(2):192-7; ISSN: 1536-4801.

Torroni, F.; De Angelis, P.; Caldaro, T.; Federici, G.; Pane, A.; Romano, C., and Dall'oglio, L. Video capsule diagnosis of intestinal duplication in a 15-year-old patient, eng. *Endoscopy.* 2006; 38 Suppl 2E10; ISSN: 1438-8812.

Tremaine, W. Indeterminate colitis - The role of wireless capsule endoscopy: author's reply, eng. *Aliment Pharmacol Ther.* 2007 Apr 1; 25(7):860; ISSN: 0269-2813.

Triantafyllou, K.; Kalantzis, C.; Papadopoulos, A. A.; Apostolopoulos, P.; Rokkas, T.; Kalantzis, N., and Ladas, S. D. Video-capsule endoscopy gastric and small bowel transit time and completeness of the examination in patients with diabetes mellitus, eng. *Dig Liver Dis.* 2007 Jun; 39(6):575-80; ISSN: 1590-8658.

Trindade, A. J. and Pitchumoni, C. S. Incidental detection of *Ascaris lumbricoides* by wireless capsule endoscopy, eng. *J Clin Gastroenterol.* 2006 Mar; 40(3):226; ISSN: 0192-0790.

Urbain, D.; De Looze, D.; Demedts, I.; Louis, E.; Dewit, O.; Macken, E., and Van Gossum, A. Video capsule endoscopy in small-bowel malignancy: a multicenter Belgian study, eng. *Endoscopy.* 2006 Apr; 38(4):408-11; ISSN: 0013-726X .

Van Tuyl, S. A.; van Noorden, J. T.; Timmer, R.; Stolk, M. F.; Kuipers, E. J., and Taal, B. G. Detection of small-bowel neuroendocrine tumors by video capsule endoscopy, eng. *Gastrointest Endosc.* 2006 Jul; 64(1):66-72; ISSN: 0016-5107.

Varela-Lema, L. and Ruano-Ravina, A. Development and use of a quality scale for assessing studies that analyze the diagnostic capacity of capsule endoscopy, eng. *Endoscopy.* 2006 Dec; 38(12):1261-7; ISSN: 0013-726X .

Vignes, S. and Bellanger, J. [Videocapsule endoscopy as a useful tool to diagnose primary intestinal lymphangiectasia] [Interet de l'enteroscopie par videocapsule dans le diagnostic

des lymphangiectasies intestinales primitives.], *fre. Rev Med Interne*. 2007 Mar; 28(3):173-5; ISSN: 0248-8663.

Wartel, F.; Maunoury, V.; Bulois, P.; Papadopoulos, S.; Filoche, B., and Colombel, J. F. Small-bowel ulcerations at wireless capsule endoscopy: go the whole way, *ENG. Gut*. 2007 Aug; 56(8):1132; ISSN: 0017-5749.

Wenner, J.; Johnsson, F.; Johansson, J., and Oberg, S. Acid reflux immediately above the squamocolumnar junction and in the distal esophagus: simultaneous pH monitoring using the wireless capsule pH system, *eng. Am J Gastroenterol*. 2006 Aug; 101(8):1734-41; ISSN: 0002-9270.

Wong, G. L.; Lai, L. H.; Lau, J. Y.; Sung, J. J., and Leung, W. K. Prolonged esophageal transit during wireless capsule endoscopy: a series of five cases and analysis of risk factors, *eng. J Clin Gastroenterol*. 2006 Feb; 40(2):176; ISSN: 0192-0790.

Yagi, Y.; Vu, H.; Echigo, T.; Sagawa, R.; Yagi, K.; Shiba, M.; Higuchi, K., and Arakawa, T. A diagnosis support system for capsule endoscopy, *eng. Inflammopharmacology*. 2007 Apr; 15(2):78-83; ISSN: 0925-4692.

Yu, W. K. and Yang, R. D. M2A video capsule lodged in the Meckel's diverticulum, *eng. Gastrointest Endosc*. 2006 Jun; 63(7):1071-2; discussion 1072; ISSN: 0016-5107.

Wireless capsule endoscopy for the diagnosis of obscure small-bowel disorders in children, *ENG. Nat Clin Pract Gastroenterol Hepatol*. 2005 May 12; 2(5):204-205; ISSN: 1743-4378.

Belafsky, P. C.; Godin, D. A.; Garcia, J. C., and Rahim, N. Comparison of data obtained from sedated versus unsedated wireless telemetry capsule placement: does sedation affect the results of ambulatory 48-hour pH testing?, *eng. Laryngoscope*. 2005 Jun; 115(6):1109-13; ISSN: 0023-852X .

Ben-Soussan, E.; Savoye, G.; Antonietti, M.; Ramirez, S.; Lerebours, E., and Ducrotte, P. Factors that affect gastric passage of video capsule, *eng. Gastrointest Endosc*. 2005 Nov; 62(5):785-90; ISSN: 0016-5107.

Bhuket, T.; Takami, M., and Fisher, L. The use of wireless capsule endoscopy in clinical diagnostic gastroenterology, *eng. Expert Rev Med Devices*. 2005 May; 2(3):259-66; ISSN: 1743-4440 .

Brummer, U.; Cappelli, P.; Laterza, F.; Di Liberato, L.; Sirolli, V.; Milano, A.; Mastrippolito, S.; D'Arezzo, M.; Muscianese, P.; Amoroso, L.; Neri, M., and Bonomini, M. Wireless capsule endoscopy in the diagnostic of small intestine angiodysplasia in chronic uremic patient, *eng. ita. Minerva Urol Nefrol*. 2005 Mar; 57(1):61-9; ISSN: 0393-2249.

Cave, D.; Legnani, P.; de Franchis, R., and Lewis, B. S. ICCE consensus for capsule retention. *Endoscopy*. 2005; 37(10):1065-1067; ISSN: 0013-726X.

Chang, P. K.; Holt, E. G.; De Villiers, W. J., and Boulanger, B. R. A new complication from a new technology: what a general surgeon should know about wireless capsule endoscopy, *eng. Am Surg*. 2005 May; 71(5):455-8; ISSN: 0003-1348.

Delvaux, M.; Ben Soussan, E.; Laurent, V.; Lerebours, E., and Gay, G. Clinical evaluation of the use of the M2A patency capsule system before a capsule endoscopy procedure, in patients with known or suspected intestinal stenosis, *eng. Endoscopy*. 2005 Sep; 37(9):801-7; ISSN: 0013-726X.

Dubner, S.; Dubner, Y.; Gallino, S.; Spallone, L.; Zagalsky, D.; Rubio, H.; Zimmerman, J., and Goldin, E. Electromagnetic interference with implantable cardiac pacemakers by video capsule, eng. *Gastrointest Endosc.* 2005 Feb; 61(2):250-4; ISSN: 0016-5107.

Eisen, G. M. Capsule endoscopy: New applications. *J. Fam. Pract.* 2005; 54(12 SUPPL.):9-14; ISSN: 0094-3509.

Flieger, D.; Keller, R.; May, A.; Ell, C., and Fischbach, W. Capsule endoscopy in gastrointestinal lymphomas. *Endoscopy.* 2005; 37(12):1174-1180; ISSN: 0013-726X.

Fry, L. C.; De Petris, G.; Swain, J. M., and Fleischer, D. E. Impaction and fracture of a video capsule in the small bowel requiring laparotomy for removal of the capsule fragments, eng. *Endoscopy.* 2005 Jul; 37(7):674-6; ISSN: 0013-726X .

Gaba, R. C.; Schlesinger, P. K., and Wilbur, A. C. Endoscopic video capsules: radiologic findings of spontaneous entrapment in small intestinal diverticula, eng. *AJR Am J Roentgenol.* 2005 Oct; 185(4):1048-50; ISSN: 0361-803X .

Golder, S.; Schmidt, J.; Kolmsee, P.; Rosner, K.; Strik, M.; Mohren, W., and Weigert, N. Identification of a Meckel's diverticulum by wireless capsule endoscopy, eng. *Endoscopy.* 2005 Jun; 37(6):608; ISSN: 0013-726X .

Goldstein, J. L.; Eisen, G. M.; Lewis, B.; Gralnek, I. M.; Zlotnick, S., and Fort, J. G. Video capsule endoscopy to prospectively assess small bowel injury with celecoxib, naproxen plus omeprazole, and placebo, eng. *Clin Gastroenterol Hepatol.* 2005 Feb; 3(2):133-41; ISSN: 1542-3565.

Gonzalez Carro, P.; Picazo Yuste, J.; Fernandez Diez, S.; Perez Roldan, F., and Roncero Garcia-Escribano, O. Intestinal perforation due to retained wireless capsule endoscope, eng. *Endoscopy.* 2005 Jul; 37(7):684; ISSN: 0013-726X .

Guilhon de Araujo Sant'Anna, A. M.; Dubois, J.; Miron, M. C., and Seidman, E. G. Wireless capsule endoscopy for obscure small-bowel disorders: final results of the first pediatric controlled trial, eng. *Clin Gastroenterol Hepatol.* 2005 Mar; 3(3):264-70; ISSN: 1542-3565.

Hammond, P. A.; Ali, D., and Cumming, D. R. A system-on-chip digital pH meter for use in a wireless diagnostic capsule, eng. *IEEE Trans Biomed Eng.* 2005 Apr; 52(4):687-94; ISSN: 0018-9294.

Heuss, L. T. [About the value of video capsule endoscopy] [Another magic bullet? Zum Stellenwert der Kapselendoskopie.], ger. *Schweiz Rundsch Med Prax.* 2005 Nov 2; 94(44):1731-4; ISSN: 1013-2058.

Hochman, J. A. and Favaloro-Sabatier, J. Tolerance and reliability of wireless pH monitoring in children, eng. *J Pediatr Gastroenterol Nutr.* 2005 Oct; 41(4):411-5; ISSN: 0277-2116.

Jonnalagadda, S. and Prakash, C. Intestinal strictures can impede wireless capsule enteroscopy, eng.

Kubota, K.; Nakamura, T., and Terano, A. [Capsule endoscopy], jpn. *Nippon Geka Gakkai Zasshi.* 2005 Nov; 106(11):685-8; ISSN: 0301-4894.

Lapalus, M. G.; Hervieu, V.; Crombe-Ternamian, A.; Scoazec, J. Y.; Valette, P. J.; Stremsdoerfer, N., and Poncet, G. [Small bowel stromal tumor: a multitechnique diagnostic approach by video-capsule and CT scan] [Tumeur stromale de l'intestin grele: une approche diagnostique multitechnique par video-capsule et enteroscanner.], fre. *Gastroenterol Clin Biol.* 2005 Nov; 29(11):1183-5; ISSN: 0399-8320.

Leighton, J. A.; Srivathsan, K.; Carey, E. J.; Sharma, V. K.; Heigh, R. I.; Post, J. K.; Erickson, P. J.; Robinson, S. R.; Bazzell, J. L., and Fleischer, D. E. Safety of wireless capsule endoscopy in patients with implantable cardiac defibrillators, eng. *Am J Gastroenterol.* 2005 Aug; 100(8):1728-31; ISSN: 0002-9270.

Maiden, L.; Thjodleifsson, B.; Theodors, A.; Gonzalez, J., and Bjarnason, I. A quantitative analysis of NSAID-induced small bowel pathology by capsule enteroscopy, eng. *Gastroenterology.* 2005 May; 128(5):1172-8; ISSN: 0016-5085.

Melmed, G. Y. and Lo, S. K. Capsule endoscopy: practical applications, eng. *Clin Gastroenterol Hepatol.* 2005 May; 3(5):411-22; ISSN: 1542-3565.

Mohl, W.; Schneider, A., and Lutz, M. P. Endoscopic insertion of an M2A video capsule through an overtube, eng. *Endoscopy.* 2005 Jun; 37(6):605; ISSN: 0013-726X .

Napierkowski, J. J.; Maydonovitch, C. L.; Belle, L. S.; Brand, W. T. Jr, and Holtzmuller, K. C. Wireless capsule endoscopy in a community gastroenterology practice, eng. *J Clin Gastroenterol.* 2005 Jan; 39(1):36-41; ISSN: 0192-0790.

Niv, Y.; Niv, G.; Wisner, K., and Demarco, D. C. Capsule endoscopy - Comparison of two strategies of bowel preparation. *Aliment. Pharmacol. Ther.* 2005; 22(10):957-962; ISSN: 0269-2813.

Payeras, G.; Piqueras, J.; Moreno, V. J.; Cabrera, A.; Menendez, D., and Jimenez, R. Effects of capsule endoscopy on cardiac pacemakers, eng. *Endoscopy.* 2005 Dec; 37(12):1181-5; ISSN: 0013-726X .

Prakash, C. and Clouse, R. E. Value of extended recording time with wireless pH monitoring in evaluating gastroesophageal reflux disease, eng. *Clin Gastroenterol Hepatol.* 2005 Apr; 3(4):329-34; ISSN: 1542-3565.

Quan, C.; Chen, G.; Lee-Henderson, M.; Kalpakian, M.; Chan, S.; Tran, T.; Enayati, P.; Dulai, G.; Kitahara, F.; Arnott, I.; Sul, J., and Jutabha, R. Overtube-assisted placement of wireless capsule endoscopy device, eng. *Gastrointest Endosc.* 2005 Jun; 61(7):914-6; ISSN: 0016-5107.

Raju, G. S. and Nath, S. K. Capsule endoscopy, eng. *Curr Gastroenterol Rep.* 2005 Oct; 7(5):358-64; ISSN: 1522-8037.

Ramirez, F. C.; Hakim, S.; Tharalson, E. M.; Shaukat, M. S., and Akins, R. Feasibility and safety of string wireless capsule endoscopy in the diagnosis of esophageal varices, eng. *Am J Gastroenterol.* 2005 May; 100(5):1065-71; ISSN: 0002-9270

Redondo-Cerezo, E.; Perez-Sola, A.; Gomez, C.; Perez-Vigara, G.; Perez-Garcia, J. I.; Morillas, J., and Gonzalez-Martin, J. A. Oesophageal entrapment of wireless capsule endoscopy in valvular patients, eng. *Gut.* 2005 Feb; 54(2):309-10; ISSN: 0017-5749

Remedios, M. L. and Appleyard, M. Capsule endoscopy: current indications and future prospects, eng. *Intern Med J.* 2005 Apr; 35(4):234-9; ISSN: 1444-0903.

Rivera, M.; Lucero, J.; Guerrero, A.; Marquez, J. L.; Montes, R.; Suner, M.; Ruiz, A.; Valdivia, M. A., and Mateos, J. [Octreotide in the treatment of angiodysplasia in patients with advanced chronic renal failure] [Tratamiento con octreotide en pacientes con angiodisplasia e insuficiencia renal cronica avanzada.], spa. *Nefrologia.* 2005; 25(3):332-5; ISSN: 0211-6995.

Saddler, D. Wireless capsule endoscopy: two research methods, one outcome, eng. *Gastroenterol Nurs.* 2005 Nov-2005 Dec 31; 28(6):516-7; ISSN: 1042-895X.

Schwacha, H. [Capsule endoscopy] [Kapselendoskopie.], ger. *Schweiz Rundsch Med Prax.* 2005 Sep 14; 94(37):1440-2; ISSN: 1013-2058.

Schwarzberg, M. N. Pro-kinetic medications as aids in imaging the small bowel by video-capsule, eng. *Med Hypotheses.* 2005; 64(3):602-7; ISSN: 0306-9877 pada, C.; Spera, G.; Riccioni, M.; Biancone, L.; Petruzzello, L.; Tringali, A.; Familiari, P.; Marchese, M.; Onder, G.; Mutignani, M.; Perri, V.; Petruzzello, C.; Pallone, F., and Costamagna, G. A novel diagnostic tool for detecting functional patency of the small bowel: the Given patency capsule, eng. *Endoscopy.* 2005 Sep; 37(9):793-800; ISSN: 0013-726X .

Sturniolo, G. C.; Di Leo, V.; Vettorato, M. G., and D'Inca, R. Clinical relevance of small-bowel findings detected by wireless capsule endoscopy, eng. *Scand J Gastroenterol.* 2005 Jun; 40(6):725-33; ISSN: 0036-5521.

Tabbers, M. M.; Bruin, K. F.; Taminiau, J. A.; de Ridder, L.; Norbruis, O. F., and Benninga, M. A. [Video-capsule endoscopy in children with unexplained symptoms of the small intestine] [Videocapsule-endoscopie bij kinderen met onbegrepen aandoeningen van de dunne darm.], dut. *Ned Tijdschr Geneesk.* 2005 Sep 17; 149(38):2119-24; ISSN: 0028-2162.

Teramoto Matsubara, O.; Zamarripa Dorsey, F., and Lopez Acosta, M. E. [Capsule endoscopy: The evolution in the diagnosis of small bowel diseases] [La capsula endoscopica: la evolucion en el diagnostico de las enfermedades del intestino delgado.], spa. *Rev Gastroenterol Mex.* 2005 Apr-2005 Jun 30; 70(2):138-42; ISSN: 0375-0906.

Wong, W.-M.; Bautista, J.; Dekel, R.; Malagon, I. B.; Tuchinsky, I.; Green, C.; Dickman, R.; Esquivel, R., and Fass, R. Feasibility and tolerability of transnasal/per-oral placement of the wireless pH capsule vs. traditional 24-h oesophageal pH monitoring - A randomized trial. *Aliment. Pharmacol. Ther.* 2005; 21(2):155-163; ISSN: 0269-2813.

Studies excluded if the comparator was not PE, DBE SBS, SBTS, CT, MRI

Adler, S. N.; Jacob, H.; Lijovetzky, G.; Mulder, C. J., and Zwiers, A. Positive coeliac serology in irritable bowel syndrome patients with normal duodenal biopsies: Video capsule endoscopy findings and HLA-DQ typing may affect clinical management, eng. *J Gastrointestin Liver Dis.* 2006 Sep; 15(3):221-5; ISSN: 1841-8724

Apostolopoulos, P.; Liatsos, C.; Gralnek, I. M.; Giannakouloupoulou, E.; Alexandrakis, G.; Kalantzis, C.; Gabriel, P., and Kalantzis, N. The role of wireless capsule endoscopy in investigating unexplained iron deficiency anemia after negative endoscopic evaluation of the upper and lower gastrointestinal tract, eng. *Endoscopy.* 2006 Nov; 38(11):1127-32; ISSN: 0013-726X .

Baichi, M. M.; Arifuddin, R. M., and Mantry, P. S. Capsule endoscopy for obscure GI bleeding: therapeutic yield of follow-up procedures, eng. *Dig Dis Sci.* 2007 May; 52(5):1370-5; ISSN: 0163-2116.

Bailey, A. A.; Debinski, H. S.; Appleyard, M. N.; Remedios, M. L.; Hooper, J. E.; Walsh, A. J., and Selby, W. S. Diagnosis and outcome of small bowel tumors found by capsule endoscopy: a three-center Australian experience, eng. *Am J Gastroenterol.* 2006 Oct; 101(10):2237-43; ISSN: 0002-9270.

Banerjee, R.; Bhargav, P.; Reddy, P.; Gupta, R.; Lakhtakia, S.; Tandan, M.; Rao, V. G., and Reddy, N. D. Safety and efficacy of the M2A patency capsule for diagnosis of critical intestinal patency: Results of a prospective clinical trial, *ENG. J Gastroenterol Hepatol.* 2007 Jul 5; ISSN: 0815-9319.

Banka, N. H.; Dhavan, P., and Chevale, B. P. Coeliac sprue—new frontiers in diagnosis and role of capsule endoscopy, *eng. J Assoc Physicians India.* 2006 Dec; 54:59-61; ISSN: 0004-5772..

Bar-Meir, S. Review article: capsule endoscopy - are all small intestinal lesions Crohn's disease?, *eng. Aliment Pharmacol Ther.* 2006 Oct; 24 Suppl 319-21; ISSN: 0269-2813.

Biagi, F.; Rondonotti, E.; Campanella, J.; Villa, F.; Bianchi, P. I.; Klersy, C.; De Franchis, R., and Corazza, G. R. Video capsule endoscopy and histology for small-bowel mucosa evaluation: a comparison performed by blinded observers, *eng. Clin Gastroenterol Hepatol.* 2006 Aug; 4(8):998-1003; ISSN: 1542-3565.

Biancone L, Clabrese E et al, Wireless Capsule Endoscopy and Small Intestine Contrast Ultrasonography in Recurrence of Crohn's Disease, *Inflamm Bowel Dis,* 2007;13(10):1256-1265.

Bossa, F.; Cocomazzi, G.; Valvano, M. R.; Andriulli, A., and Annese, V. Detection of abnormal lesions recorded by capsule endoscopy. A prospective study comparing endoscopist's and nurse's accuracy, *eng. Dig Liver Dis.* 2006 Aug; 38(8):599-602; ISSN: 1590-8658.

Bosseckert, H. Importance of capsule endoscopy in small bowel diseases: DIE BEDEUTUNG DER KAPSELENDOSKOPIE BEI DUNNDARM-ERKRANKUNGEN. *Verdauungskrankheiten.* 2007; 25(2):51-74; ISSN: 0174-738X.

Bourreille, A.; Jarry, M.; D'Halluin, P. N.; Ben-Soussan, E.; Maunoury, V.; Bulois, P.; Sacher-Huvelin, S.; Vahedy, K.; Lerebours, E.; Heresbach, D.; Bretagne, J. F.; Colombel, J. F., and Galmiche, J. P. Wireless capsule endoscopy versus ileocolonoscopy for the diagnosis of postoperative recurrence of Crohn's disease: a prospective study, *eng. Gut.* 2006 Jul; 55(7):978-83; ISSN: 0017-5749..

Carey, E. J.; Leighton, J. A.; Heigh, R. I.; Shiff, A. D.; Sharma, V. K.; Post, J. K., and Fleischer, D. E. A single-center experience of 260 consecutive patients undergoing capsule endoscopy for obscure gastrointestinal bleeding, *eng. Am J Gastroenterol.* 2007 Jan; 102(1):89-95; ISSN: 0002-9270 .

Technology Insight: current status of video capsule endoscopy, *eng. Nat Clin Pract Gastroenterol Hepatol.* 2006 Mar; 3(3):158-64; ISSN: 1743-4378.

Cheifetz, A. S.; Kornbluth, A. A.; Legnani, P.; Schmelkin, I.; Brown, A.; Lichtiger, S., and Lewis, B. S. The risk of retention of the capsule endoscope in patients with known or suspected Crohn's disease, *eng. Am J Gastroenterol.* 2006 Oct; 101(10):2218-22; ISSN: 0002-9270 .

Daum, S.; Wahnschaffe, U.; Glasenapp, R.; Borchert, M.; Ullrich, R.; Zeitz, M., and Faiss, S. Capsule endoscopy in refractory celiac disease, *eng. Endoscopy.* 2007 May; 39(5):455-8; ISSN: 1438-8812 .eshpande, A.; Storch, I., and Barkin, J. Diagnosis of lymphoma in overt obscure GI bleeding aided by capsule endoscopy, *eng. Gastrointest Endosc.* 2007 Jan; 65(1):159-60; discussion 160; ISSN: 0016-5107 .

Eliakim, A. R. Video capsule endoscopy of the small bowel (PillCam SB), *eng. Curr Opin Gastroenterol.* 2006 Mar; 22(2):124-7; ISSN: 0267-1379 .

Estevez, E.; Gonzalez-Conde, B.; Vazquez-Iglesias, J. L.; de Los Angeles Vazquez-Millan, M.; Pertega, S.; Alonso, P. A.; Clofent, J.; Santos, E.; Ulla, J. L., and Sanchez, E. Diagnostic yield and clinical outcomes after capsule endoscopy in 100 consecutive patients with obscure gastrointestinal bleeding, eng. *Eur J Gastroenterol Hepatol*. 2006 Aug; 18(8):881-8; ISSN: 0954-691X .

Fidder, H. H.; Nadler, M.; Lahat, A.; Lahav, M.; Bardan, E.; Avidan, B., and Bar-Meir, S. The utility of capsule endoscopy in the diagnosis of Crohn's disease based on patient's symptoms, eng. *J Clin Gastroenterol*. 2007 Apr; 41(4):384-7; ISSN: 0192-0790.

Fix, O. K.; Simon, J. T.; Farraye, F. A.; Oviedo, J. A.; Pratt, D. S.; Chen, W. T., and Cave, D. R. Obscure gastrointestinal hemorrhage from mesenteric varices diagnosed by video capsule endoscopy, eng. *Dig Dis Sci*. 2006 Jul; 51(7):1169-74; ISSN: 0163-2116

Gaj, F.; Trecca, A.; Crispino, P., and Silano, V. [The role of capsule endoscopy in the study of intestinal diseases. Critical analysis and observation of the first 50 cases] [Il ruolo dell'endoscopia capsulare nello studio delle patologie intestinali Analisi critica e riflessioni su 50 casi.], ita. *Chir Ital*. 2007 Jan-2007 Feb 28; 59(1):69-73; ISSN: 0009-4773.

Girelli, C. M.; Porta, P.; Malacrida, V.; Barzaghi, F., and Rocca, F. Clinical outcome of patients examined by capsule endoscopy for suspected small bowel Crohn's disease, eng. *Dig Liver Dis*. 2007 Feb; 39(2):148-54; ISSN: 1590-8658 .

Griffa, B.; Basilico, V.; Feltri, M., and Griffa, A. [Submucosal jejunal lymphangioma: an unusual case with obscure gastrointestinal bleeding in an adult, detected by video-capsule endoscopy and treated by laparoscopy] [Linfangioma sottomucoso del digiuno: un raro caso di sanguinamento digestivo occulto nell'adulto, diagnosticato con video-capsula endoscopia e trattato con tecnica laparoscopica.], ita. *Minerva Chir*. 2006 Dec; 61(6):529-32; ISSN: 0026-4733.

Heinrich, M.; Grgic, A.; Heckmann, M., and Uder, M. [Retention of a videoendoscopy capsule leading to small bowel obstruction in a patient with recurrence of rectum carcinoma] [Dunndarmobstruktion durch Retention einer Videoendoskopie-Kapsel bei einem Patienten mit Rektumkarzinomrezidiv.], ger. *Rontgenpraxis*. 2006; 56(3):113-7; ISSN: 0035-7820.

Hopper, A. D.; Sidhu, R.; Hurlstone, D. P.; McAlindon, M. E., and Sanders, D. S. Capsule endoscopy: an alternative to duodenal biopsy for the recognition of villous atrophy in coeliac disease?, eng. *Dig Liver Dis*. 2007 Feb; 39(2):140-5; ISSN: 1590-8658 .

Karagiannis, S.; Goulas, S.; Kosmadakis, G.; Galanis, P.; Arvanitis, D.; Boletis, J.; Georgiou, E., and Mavrogiannis, C. Wireless capsule endoscopy in the investigation of patients with chronic renal failure and obscure gastrointestinal bleeding (preliminary data), eng. *World J Gastroenterol*. 2006 Aug 28; 12(32):5182-5; ISSN: 1007-9327.

Kavin, H.; Berman, J.; Martin, T. L.; Feldman, A., and Forsey-Koukol, K. Successful wireless capsule endoscopy for a 2.5-year-old child: obscure gastrointestinal bleeding from mixed, juvenile, capillary hemangioma-angiomas of the jejunum, eng. *Pediatrics*. 2006 Feb; 117(2):539-43; ISSN: 1098-4275.

Kim, S. G.; Choi, K. D.; Kim, J. S.; Jung, H. C., and Song, I. S. Ileal inflammatory fibroid polyp: a rare cause of obscure gastrointestinal bleeding diagnosed by wireless capsule endoscopy, eng. *Dig Dis Sci*. 2006 May; 51(5):906-8; ISSN: 0163-2116.

Kimchi, N. A.; Eliakim, R.; Suissa, A., and Scapa, E. [The contribution of capsule endoscopy to the diagnosis of small-bowel tumors in cases of obscure overt gastrointestinal bleeding], heb. *Harefuah*. 2006 Nov; 145(11):811-4, 862, 861; ISSN: 0017-7768.

Kovacs, D. J. and Berk, T. Gastrointestinal bleeding of obscure origin undetected by multiple tests for fecal occult blood and diagnosed only by capsule endoscopy: a case report, eng. *J Am Board Fam Med.* 2006 Nov-2006 Dec 31; 19(6):641-2; ISSN: 1557-2625.

Legnani, P. and Abreu, M. T. Use of Capsule Endoscopy for Established Crohn's Disease. *Gastrointest. Endosc. Clin. North Am.* 2006; 16(2):299-306; ISSN: 1052-5157.

Leighton, J. A.; Legnani, P., and Seidman, E. G. Role of capsule endoscopy in inflammatory bowel disease: where we are and where we are going, eng. *Inflamm Bowel Dis.* 2007 Mar; 13(3):331-7; ISSN: 1078-0998.

Leighton, J. A.; Triester, S. L., and Sharma, V. K. Capsule Endoscopy: A Meta-Analysis for Use with Obscure Gastrointestinal Bleeding and Crohn's Disease. *Gastrointest. Endosc. Clin. North Am.* 2006; 16(2):229-250; ISSN: 1052-5157.

LePane, C. A.; Barkin, J. S.; Parra, J., and Simon, T. Ulcerative jejunoileitis: a complication of celiac sprue simulating Crohn's disease diagnosed with capsule endoscopy (PillCam), eng. *Dig Dis Sci.* 2007 Mar; 52(3):698-701; ISSN: 0163-2116.

Lopes, L.; Ramada, J., and Certo, M. Blue rubber bleb nevus syndrome: capsule endoscopy in a patient with GI bleeding, eng. *Gastrointest Endosc.* 2007 Jan; 65(1):151-2; discussion 152; ISSN: 0016-5107 .

Marmo, R.; Rotondano, G.; Riccio, G.; D'Angella, R.; Rescinito, M.; Rescinito, A.; Bianco, M. A., and Cipolletta, L. Small-bowel adenocarcinoma diagnosed via capsule endoscopy in a patient found to have hereditary nonpolyposis colorectal cancer, eng. *Gastrointest Endosc.* 2007 Mar; 65(3):524-5, discussion 525; ISSN: 0016-5107.

Mazzarolo, S. and Brady, P. Small bowel capsule endoscopy: a systematic review, eng. *South Med J.* 2007 Mar; 100(3):274-80; ISSN: 0038-4348.

Park, C. H.; Kim, J. O.; Choi, M. G.; Kim, K. J.; Kim, Y. H.; Kim, Y. S.; Kim, T. I.; Do, J. H.; Ryu, J. K.; Moon, J. S.; Park, S. H.; Shim, K. N.; Lee, K. M.; Lee, I. S., and Chun, H. J. Utility of capsule endoscopy for the classification of Crohn's disease: a multicenter study in Korea, eng. *Dig Dis Sci.* 2007 Jun; 52(6):1405-9; ISSN: 0163-2116.

Redondo-Cerezo, E.; Perez-Vigara, G.; Perez-Sola, A.; Gomez-Ruiz, C. J.; Chicano, M. V.; Sanchez-Manjavacas, N.; Morillas, J.; Perez-Garcia, J. I., and Garcia-Cano, J. Diagnostic yield and impact of capsule endoscopy on management of patients with gastrointestinal bleeding of obscure origin, eng. *Dig Dis Sci.* 2007 May; 52(5):1376-81; ISSN: 0163-2116.

Rieder, F.; Schneidewind, A.; Bolder, U.; Zorger, N.; Scholmerich, J.; Schaffler, A.; Golder, S.; Kullmann, F., and Herfarth, H. Use of anticoagulation during wireless capsule endoscopy for the investigation of recurrent obscure gastrointestinal bleeding, eng. *Endoscopy.* 2006 May; 38(5):526-8; ISSN: 0013-726X.

Rondonotti, E.; Spada, C.; Cave, D.; Pennazio, M.; Riccioni, M. E.; De Vitis, I.; Schneider, D.; Sprujevnik, T.; Villa, F.; Langelier, J.; Arrigoni, A.; Costamagna, G., and de Franchis, R. Video Capsule Enteroscopy in the Diagnosis of Celiac Disease: A Multicenter Study, ENG. *Am J Gastroenterol.* 2007 Apr 24; ISSN: 0002-9270

Rotondano, G.; Riccio, G., and Marmo, R. Capsule enteroscopy us conventional procedures in diagnosing small bowel diseases: A meta-analysis of controlled trials: ENTEROSCOPIA CON VIDEO CAPSULA VS PROCEDURA CONVENZIONALI NELLA DIAGNOSI DELLE MALAT-

TIE DELL'INTESTINO TENUE: UN META-ANALISI DEGLI STUDI CONTROLLATI. G. Ital. Endosc. Dig. 2006; 29(4):331-337; ISSN: 0394-0225.

Tatar, E. L.; Shen, E. H.; Palance, A. L.; Sun, J. H., and Pitchumoni, C. S. Clinical utility of wireless capsule endoscopy: experience with 200 cases, eng. J Clin Gastroenterol. 2006 Feb; 40(2):140-4; ISSN: 0192-0790 .

Toth, E.; Lillienau, J.; Ekelund, M.; Alumets, J.; Olsson, R., and Thorlaciuss, H. Ulcerated small-intestine duplication cyst: an unusual source of GI bleeding revealed by wireless capsule endoscopy, eng. Gastrointest Endosc. 2006 Jan; 63(1):192-4; ISSN: 0016-5107.

Toth, E.; Ohlsson, B.; Ljungberg, O., and Thorlaciuss, H. Celiac disease diagnosed using video capsule endoscopy in a patient with Crohn's disease, eng. Endoscopy. 2006 May; 38(5):548; ISSN: 0013-726X .

Voderholzer, W. A. The role of PillCam endoscopy in Crohn's disease: the European experience, eng. Gastrointest Endosc Clin N Am. 2006 Apr; 16(2):287-97, ix; ISSN: 1052-5157.

Zhang, B. L.; Li, Y. M., and Chen, C. X. [Clinical value of capsule endoscopy in obscure gastrointestinal bleeding], chi. Zhejiang Da Xue Xue Bao Yi Xue Ban. 2006 Sep; 35(5):547-50; ISSN: 1008-9292 .

Barkay, O.; Moshkowitz, M., and Reif, S. Crohn's disease diagnosed by wireless capsule endoscopy in adolescents with abdominal pain, protein-losing enteropathy, anemia and negative endoscopic and radiologic findings, eng. Isr Med Assoc J. 2005 Apr; 7(4):216-8; ISSN: 1565-1088.

Boivin, M. L.; Lochs, H., and Voderholzer, W. A. Does passage of a patency capsule indicate small-bowel patency? A prospective clinical trial?, eng. Endoscopy. 2005 Sep; 37(9):808-15; ISSN: 0013-726X.

Chao, C. C.; Ng Jao, Y. T., and Mo, L. R. Capsule endoscopy for gastrointestinal bleeding with an obscure etiology, eng. J Formos Med Assoc. 2005 Sep; 104(9):659-65; ISSN: 0929-6646

Culliford, A.; Daly, J.; Diamond, B.; Rubin, M., and Green, P. H. The value of wireless capsule endoscopy in patients with complicated celiac disease, eng. Gastrointest Endosc. 2005 Jul; 62(1):55-61; ISSN: 0016-5107.

Dai N, Gubler C Hengstler P Meyenberger C Bauerfeind P. Improved capsule endoscopy after bowel preparation. Gastrointestinal Endoscopy. 2005; 61(1):28-31; ISSN: CN-00511167 otes: Publication Type: Clinical Trial; Controlled Clinical Trial; Journal Article; Research Support, Non-U.S. Gov't

Davis, B. R.; Harris, H., and Vitale, G. C. The evolution of endoscopy: wireless capsule cameras for the diagnosis of occult gastrointestinal bleeding and inflammatory bowel disease, eng. Surg Innov. 2005 Jun; 12(2):129-33; ISSN: 1553-3506.

De Leusse, A.; Landi, B.; Edery, J.; Burtin, P.; Lecomte, T.; Seksik, P.; Bloch, F.; Jian, R., and Cellier, C. Video capsule endoscopy for investigation of obscure gastrointestinal bleeding: feasibility, results, and interobserver agreement, eng. Endoscopy. 2005 Jul; 37(7):617-21; ISSN: 0013-726X .

Gal, I.; Gyenes, I.; Gerdan, J.; Plosz, J.; Kiss, G., and Szegedi, L. [Wireless capsule endoscopy and its role in gastroenterology: our results and a review of the literature] [Kapszulas

endoszkópia helye a gasztroenterológiai diagnosztikában: irodalmi áttekintés saját eredményeink tükrében.], *hun. Orv Hetil.* 2005 Sep 25; 146(39):2023-8; ISSN: 0030-6002.

Jones, B. H.; Fleischer, D. E.; Sharma, V. K.; Heigh, R. I.; Schiff, A. D.; Hernandez, J. L., and Leighton, J. A. Yield of repeat wireless video capsule endoscopy in patients with obscure gastrointestinal bleeding, *eng. Am J Gastroenterol.* 2005 May; 100(5):1058-64; ISSN: 0002-9270.

Kalantzis, N.; Papanikolaou, I. S.; Giannakouloupoulou, E.; Alogari, A.; Kalantzis, C.; Papacharalampous, X.; Gabriel, P.; Alexandrakis, G., and Apostolopoulos, P. Capsule endoscopy; the cumulative experience from its use in 193 patients with suspected small bowel disease, *eng. Hepatogastroenterology.* 2005 Mar-2005 Apr 30; 52(62):414-9; ISSN: 0172-6390.

Kesari, A.; Bobba, R. K., and Arsura, E. L. Video capsule endoscopy and celiac disease, *eng. Gastrointest Endosc.* 2005 Nov; 62(5):796-7; ISSN: 0016-5107.

Knebel P, Hummel F Boecker U Antoni C Loehr M Weiss C Singer MV. [Video capsule endoscopy: a randomised, controlled, single-blind study on preparation with Prepacol (R) versus the standard preparation] [Videokapselendoskopie: eine randomisierte, kontrollierte, einfach-blinde Studie zur Vorbereitung mit Prepacol (R) versus Standardvorbereitung.]. *Zeitschrift Fur Gastroenterologie.* 2005; 43(8):940. CODEN: RCT; ISSN: CN-00547110.

Legnani, P. and Kornbluth, A. Video capsule endoscopy in inflammatory bowel disease 2005, *eng. Curr Opin Gastroenterol.* 2005 Jul; 21(4):438-42; ISSN: 0267-1379.

Marmo, R.; Rotondano, G.; Piscopo, R.; Bianco, M. A.; Siani, A.; Catalano, O., and Cipolletta, L. Capsule endoscopy versus enteroclysis in the detection of small-bowel involvement in Crohn's disease: a prospective trial, *eng. Clin Gastroenterol Hepatol.* 2005 Aug; 3(8):772-6; ISSN: 1542-3565.

Mata, A.; Llach, J.; Castells, A.; Rovira, J. M.; Pellise, M.; Gines, A.; Fernandez-Esparrach, G.; Andreu, M.; Bordas, J. M., and Pique, J. M. A prospective trial comparing wireless capsule endoscopy and barium contrast series for small-bowel surveillance in hereditary GI polyposis syndromes, *eng. Gastrointest Endosc.* 2005 May; 61(6):721-5; ISSN: 0016-5107.

Moreno, C.; Arvanitakis, M.; Deviere, J., and Van Gossum, A. Capsule endoscopy examination of patients with obscure gastrointestinal bleeding: evaluation of clinical impact, *eng. Acta Gastroenterol Belg.* 2005 Jan-2005 Mar 31; 68(1):10-4; ISSN: 0001-5644.

Papadakis, K. A.; Lo, S. K.; Fireman, Z., and Hollerbach, S. Wireless capsule endoscopy in the evaluation of patients with suspected or known Crohn's disease, *eng. Endoscopy.* 2005 Oct; 37(10):1018-22; ISSN: 0013-726X

Qvigstad, G.; Flottum, O., and Waldum, H. L. [Capsule endoscopy—a new method for the diagnosis of diseases of the small intestine] [Kapselendoskopi - en ny metode for diagnostikk av sykdom i tynntarm.], *nor. Tidsskr Nor Laegeforen.* 2005 Jan 20; 125(2):163-6; ISSN: 0807-7096.

Schulmann, K.; Hollerbach, S.; Kraus, K.; Willert, J.; Vogel, T.; Moslein, G.; Pox, C.; Reiser, M.; Reinacher-Schick, A., and Schmiegel, W. Feasibility and diagnostic utility of video capsule endoscopy for the detection of small bowel polyps in patients with hereditary polyposis syndromes, *eng. Am J Gastroenterol.* 2005 Jan; 100(1):27-37; ISSN: 0002-9270.

Signorelli, C.; Villa, F.; Rondonotti, E.; Abbiati, C.; Beccari, G., and de Franchis, R.

Sensitivity and specificity of the suspected blood identification system in video capsule enteroscopy, eng. *Endoscopy*. 2005 Dec; 37(12):1170-3; ISSN: 0013-726X.

Viazis, N.; Papaxoinis, K.; Theodoropoulos, I.; Sgouros, S.; Vlachogiannakos, J.; Pipis, P.; Markoglou, C., and Avgerinos, A. Impact of capsule endoscopy in obscure small-bowel bleeding: defining strict diagnostic criteria for a favorable outcome, eng. *Gastrointest Endosc*. 2005 Nov; 62(5):717-22; ISSN: 0016-5107.

Wang, X.; -H Meng, M., and Chan, Y. Physiological factors of the small intestine in design of active capsule endoscopy, eng. *Conf Proc IEEE Eng Med Biol Soc*. 2005; 32942-5; ISSN: 1557-170X.

Ziegler, K. M.; Flamm, C. R., and Aronson, N. Wireless capsule endoscopy in patients with obscure small-intestinal bleeding, eng. *J Am Coll Radiol*. 2005 Oct; 2(10):818-20; ISSN: 1546-1440 .

Bresci, G.; Parisi, G.; Bertoni, M.; Tumino, E., and Capria, A. The role of video capsule endoscopy for evaluating obscure gastrointestinal bleeding: usefulness of early use, eng. *J Gastroenterol*. 2005 Mar; 40(3):256-9; ISSN: 0944-1174.

Studies excluded because less than 10 patients received WCE

Filippone, A.; Cianci, R.; Milano, A.; Valeriano, S.; Di Mizio, V., and Storto, M. L. Obscure gastrointestinal bleeding and small bowel pathology: comparison between wireless capsule endoscopy and multidetector-row CT enteroclysis, ENG. *Abdom Imaging*. 2007 Jul 6; ISSN: 0942-8925.

Johanssen S, Mariam B, Herbert L., Winfried V., The yield of wireless capsule endoscopy in the detection of neuroendocrine tumors in comparison with CT enteroclysis, *Gastrointestinal Endoscopy*, 2000; 63(4):660-665.

Appendix 7

Author questions

Answer 1	Answer 2
<p>"At the time of the study, PE and enteroclysis were investigations commonly available in the structure to investigate the extent of small bowel disease. We chose the same group of patients as one of our aims was to compare diagnostic yield of the different investigation modalities in the same cohort of patients (i.e. suspected small bowel Crohn's disease). If we were to do the study again today, we would probably choose MRI enteroclysis as the comparator."</p>	
<p>"A few years ago wireless capsule endoscopy was a new method to evaluate the whole small bowel. Every new method have to compare with the standard procedures. This was the reason to perform a study to compare wireless capsule endoscopy is the gold standard, the intraoperative enteroscopy."</p>	
<p>"Crossover design was selected to ensure that each patient was its own control."</p>	<p>"CT and selective angiography are the two angiographic modalities currently used in our hospital."</p>
<p>"We wanted to determine how accurate WCE was compared to another test (standard endoscopy) in assessing polyps counts and sizes. We had a defined segment of small bowel marked with a tattoo that would allow us to assess how many polyps and the size of the polyps in this segment."</p>	<p>"We used standard endoscopy as the comparator since it is the "gold standard" and was felt to be more accurate than other comparators (enteroclysis, SBFT etc)."</p>
<p>"If some groups were selected on the study for the comparison of the new different devices, and the skill and knowledge of endoscopy were different, accurate comparison could not be done because of the difference of the technique. All our members were educated for endoscopic technique almost equally. Although the new devices were different, the examiners with equal skills of endoscopy could take part in the comparison. Our group, the department of gastroenterology has several subgroups. The capsule endoscopy and its comparator were performed by the member of different subgroup."</p>	<p>"In Japan, double balloon endoscopy (DBE) was introduced earlier than capsule endoscopy. We thought DBE was actually excellent and Some Japanese doctors have said that it was useful than capsule endoscopy. Thus we planned the comparison of the good devices."</p>

<p>"By introducing a new method it is of utmost importance to compare with other standard methods, of course in the same group of patients."</p>	<p>"In our hospital, CT enteroclysis is the standard method for diagnosing Crohn's disease. I hope I could answer your questions to your satisfaction."</p>
<p>"As any new diagnostic mean, we felt that a gold standard was of importance to determine efficiently the clinical usefulness of capsule endoscopy."</p>	<p>"Push enteroscopy was at this time the only available not so invasive although this comparator was used by one german team. Please contact the first writer of this email if you require further information or clarification."</p>

APPENDIX 8

Responding Centres

Region	Responding Centre	Manager of department	In charge of compilation
Piemonte	ASL BIELLA	GIUSEPPE MALFITANA	GIUSEPPE MALFITANA
	ASO ORDINE MAURIZIANO	RODOLFO CAVALIERE	RAFFAELLO SOSTEGNI
	ASL ALESSANDRIA	CARLO GEMME	CARLO GEMME
	ASO SANTA CROCE	RENZO FERRARIS	RAFFAELLA PULITANO'
	AO MAGGIORE DELLA CARITA'	MARIO DEL PIANO	STEFANIA CARMAGNOLA
	CASA DI CURA FORNACA	FRANCESCO PAOLO ROSSINI	FRANCESCO PAOLO ROSSINI
	OSPEDALE MARIA VITTORIA	ARNALDO FERRARI	PAOLA SECRETO
	OSPEDALE MOLINETTE	MARIO RIZZETTO	GIORGIO SARACCO
	OSPEDALE SAN GIOVANNI AS	ALBERTO FOGO	MARCO PENNAZIO
	OS SS TRINITA (PRESIDIO ASL13)	PIETRO OCCHIPINTI	SILVIA SAETTONE
	OSPEDALE SAN LAZZARO	GIACOMO PRANDI	SABINA MARTINI
Valle d'Aosta	OSPEDALE BEAUREGARA	SERGIO CROTTA	ROBERTO LOLLI
Lombardia	CASA DI CURA S.PIOX	MARCO DAL FANTE	MARCO DAL FANTE
	IRCSS FONDAZIONE POLICLINICO MANAGIAGALLI	ROBERTO DE FRANCHIS	EMANUELE RONDONOTTI
	AO VALTELLINA E VALCHIAVENNA	GIANFRANCO TRINCA	CARLO PANSONI
	AO SAN CARLO BORROMEO	DOMINGO SPOTTI	MARCO SONCINI
	OSPEDALE SAN GIUSEPPE	EDOARDO FESCE	EDOARDO FESCE
	FONDAZIONE POLIAMBULANZA	ALESSANDRO PATERLINI	PIETRO CESARI
	AO CREMA	ALESSANDRO ZAMBELLI	GUIDO LUPINACCI
	AO DI CIRCOLO MELEGNANO P.O MELLO	IVANA RAGUZZI	PASQUALE DI VITAGLIANO
	OSPEDALE CIRCOLO BUSTO ARSIZIO	EUGENIO LIMIDO	GIRELLI
Veneto	AO VERONA	LUCIANO BITI	CARLO MANFRINI
	AO DI PADOVA	GIACOMO CARLO STURNIOLO	RENATA D'INCA
	ASL 5 OVEST VICENTINO	ENRICO BOTTONA	MAURIZIO PANTALENA
	ULSS 2 FELTRE	MICHELE DE BONI	MICHELE DE BONI
Friuli Venezia Giulia	CENTRO RIFERIMENTO ONCOLOGICO	RENATO CANNIZZARO	RENATO CANNIZZARO
	IRCC BURLO GAROFALO CL. PEDIATRICA	STEFANO MARTELLOSI	STEFANO MARTELLOSI
Liguria	AZIENDA OSPEDALIERA SANTA CORONA	ROBERTO TESTA	CESARINA RAINISIO

Emilia Romagna	ARCISPEDALE SANTA MARIA NUOVA	ROMANO SASSATELLI	CRISTINA TIOLI
	ASL OSP BELLARIA MAGGIORE	NICOLA D'IMPERIO	ANGELA ALBERANI
	ARCISPEDALE SANTA ANNA	SERGIO GULLINI	FRANCO PEZZOLI
	OSPEDALE MORGAGNI - PIERANTONI	RICCI ENRICO	LIONELLO GANDOLFI
Toscana	AO UNIVERSITARIA PISANA	SANTINO MARCHI	LINDA CECCARELLI
	DIP GASTROENTEROLOGIA E MAL RICAMBIO	ALFONSO CAPRIA	EMANUELE TUMINO
Marche	AO OSPEDALI RIUNITI	IVANO LORENZINI	IVANO LORENZINI
Lazio	AZIENDA OSPEDALIERA POLICLINICO UMBERTO I	PAOLO PAOLUZI	PAOLO PAOLUZI
	POLICLINICO GEMELLI	GUIDO COSTAMGNA	MARIA ELENA RICCIONI
	AO SAN CAMILLO FORLANINI	COSIMO PRANTERA	TOMMASO PANTANELLA
	POLICLINICO TOR VERGATA	FRANCESCO PALLONE	CARMELINA PETRUZZIELLO
	ACO SAN FILIPPO NERI	LUCIO CAPURSO	ROBERTO LUCCHETTI
Abruzzo	ASL L'AQUILA PO SAN SALVATORE	ANTONIETTA PISTOIA	LORETO LOMBARDI
Molise	ASR OSPEDALE S S ROSARIO	TOMMASO GAGLIONE	ROBERTO CHIAVERINI
Campania	OSPEDALE MERCATO SAN SEVERINO ASL SA 2	ATTILIO MAURANO	GELSONIMO QUAGLIARIELLO
	AORN SAN G. MOSCATI	GAETANO IAQUINTO	SIMONE DI BELLA
	OSPEDALE SAN GENNARO ASL NA1	SANTO MONASTRA	GIANCARLO CAVARELLI
	ASL SALERNO 3 PO POLLA	RICCARDO MARMO	RICCARDO MARMO
	AO DI RILIEVO NAZIONALE ANTONIO CARDARELLI	GIAN BATTISTA FORTE	MARIA PACELLI
Puglia	AZIENDA OSPEDALI RIUNITI DI FOGGIA	VINCENZO DI FRANCESCO	VINCENZO DI FRANCESCO
	OSPEDALE CIVILE UMBERTO I	GIUSEPPE SCACCIANOCE	GIUSEPPE SCACCIANOCE
	ISTITUTO TUMORI BARI	ANTONIO PELLECCCHIA	FRANCESCO SCOTTO
	ASL1 TARANTO OSP. SANT'ANNUNZIATA	ANDREA FRUNZIO	ANDREA FRUNZIO
Calabria	AO ANNUNZIATA	PIETRO LEO	PIETRO LEO
	OSPEDALE SAN GIOVANNI DI DIO	ENRICO CILIBERTO	CESARE CAVALIERE
Sicilia	ASL 5 MESSINA	SALVATORE OCERA	SALVATORE OCERA
	OSPEDALE VITTORIO EMANUELE	ANTONIO MAGNANO	ANTONIO MAGNANO
Sardegna	AUSL 7 CARBONIA OSP. S. BARBARA	SERGIO CADONI	PAOLO GAUTIN

APPENDIX 9



Questionnaire

Wireless Capsule Endoscopy

Institution	
Address	
Region	

Type of institution	Public	Private	Private (operating within the National Health Service)
	<input type="checkbox"/> Hospital	<input type="checkbox"/> Hospital	<input type="checkbox"/> Hospital
	<input type="checkbox"/> Outpatient	<input type="checkbox"/> Outpatient	<input type="checkbox"/> Outpatient
	<input type="checkbox"/> Other:	<input type="checkbox"/> Other:	<input type="checkbox"/> Other:

Manager of department	Phone	
		E-mail	

In charge of compilation	Phone	
		E-mail	

Information related to the examinations with Video Endoscopic Capsule (WCE)

1. Indicate the total number of examination with WCE-year 2006	N°
---	----------

2. Indicate the number of WCE for regime of health service admission	N°
Hospitalization	
Outpatient treatment	
Day Hospital	

3. Indicate the number of patients for age group	N°
<30	
30-50	
>50	

4. Incomplete/inadequate preparation:				
	N°		%	
- Repeated for inadequate preparation		<input type="checkbox"/> Real data		<input type="checkbox"/> Estimate
- Incomplete		<input type="checkbox"/> Real data		<input type="checkbox"/> Estimate
- Other				
		<input type="checkbox"/> Real data		<input type="checkbox"/> Estimate
		<input type="checkbox"/> Real data		<input type="checkbox"/> Estimate
		<input type="checkbox"/> Real data		<input type="checkbox"/> Estimate

5. Diagnostic test workup pre WCE:	N°
- Colonoscopy (CS)	
- Rectoscopy (RT)	

- FOBT	
- EGDS	
- RX small intestine	
- Ileoscopy	
- Double balloon enteroscopy	
- Push enteroscopy	
- Jejunoscopy	
- Arteriography	
- Other	

6. Motivation of WCE:	N°
- FOBT(+)	
- FOBT(-)	
- Familiar Polyposis	
- Diagnosed IBD	
- Suspected IBD	
- Intestinal Neoplasm	
- Angiodysplasia	
- Peutz-Jeghers Syndrome	
- Hepatic metastasis	
- Other	

7. Principal pathology identified with WCE:	N°
- Angiodysplasia	
- Polyposis	
- IBD	
- Coeliac disease	
- NSAID Lesion	
- Gist jejunum	
- Lipoma	
- Gastric Bleeding	
- Duodenal Ulcer	
- Other:	

8. Complications of the procedure:		N°
- Intestinal occlusion		
- Other:		
9. Type of regime of health service admission for complications :		
Outpatient treatment	Day Hospital	Hospitalisation

10. Is a diet recommended before the examination?		<input type="checkbox"/> Yes	<input type="checkbox"/> No
11. If yes, specify			
12. Is an enema recommend of before the examination?		<input type="checkbox"/> Yes	<input type="checkbox"/> No
13. Which solution is used for the intestinal preparation?			
<input type="checkbox"/> Poliethilenglicole (PEG)			
<input type="checkbox"/> Sodium-phosphate			
<input type="checkbox"/> Other (specify)			
14. What percentage is furnished free of charge from the hospital?			
– Outpatient treatment			
– Day Hospital			

15. Indicate the clinical or surgical decisions following the WCE:	
1)	
2)	
3)	

16. Are drugs used before the WCE examination?		
<input type="checkbox"/> Yes <input type="checkbox"/> No		
17. If yes, specify:		
	Unit quantity	Unit cost
-		
-		

18. Staff time (minutes) for one WCE procedure:			
	WCE	Diagnosis	Consultation
<u>Physician</u>			
- Number			
- Middle time dedicated (minutes)*			
<u>Nurse</u>			
- Number			
- Average time dedicated (minutes)*			
<u>Support (auxiliaries)</u>			
- Number			
- Average time dedicated (minutes)*			
<u>Administrative</u>			
- Number			
- Average time dedicated (minutes)*			
Total time			

*for patient

19. Consumables for one standard WCE procedure:					
	Unit quantity	Unit cost	Manufacturer (only WCE)		
Capsule Endoscopy					
Test Capsule Endoscopy					
Surgical gauze					
Surgical gloves					
Disinfectant					
Sheet				<input type="checkbox"/> Disposable	<input type="checkbox"/> Reusable
Other:					
				<input type="checkbox"/> Disposable	<input type="checkbox"/> Reusable
				<input type="checkbox"/> Disposable	<input type="checkbox"/> Reusable
				<input type="checkbox"/> Disposable	<input type="checkbox"/> Reusable

20. Indicate the stationery:					
	Unit quantity	Unit cost			
Toner					
Cartridge					
Sensitised paper					
Other:					
			<input type="checkbox"/> Disposable	<input type="checkbox"/> Reusable	<input type="checkbox"/> Both
			<input type="checkbox"/> Disposable	<input type="checkbox"/> Reusable	<input type="checkbox"/> Both
			<input type="checkbox"/> Disposable	<input type="checkbox"/> Reusable	<input type="checkbox"/> Both

21. Indicate the equipment:					
	Unit	year	Unit cost	Maintenance cost	Year of amortization
Hardware + software*					
Tools					
Software					
Monitor					
Printing					
Computer					
Equipped trolley					
Other:					

* Total cost

APPENDIX 10



Wireless capsule and traditional endoscopy:
patient acceptability

1. The ingestion of the capsule has been:

- Very easy
- Easy
- Tolerable
- Difficult
- Very difficult

2. Did you experience pain during the procedure?

- No pain
- Mild
- Moderate
- Severe
- Extreme

3. Did you experience pain after the procedure?

- No pain
- Mild
- Moderate
- Severe
- Extreme

4. During the hours of tracking which of the following inconveniences did you have?:

<i>A) Difficulty to move</i>	<input type="checkbox"/> Yes <input type="checkbox"/> No	<i>B) Impossibility to go in some places:</i>	<input type="checkbox"/> Yes <input type="checkbox"/> No	<i>C) State of anxiety</i>	<input type="checkbox"/> Yes <input type="checkbox"/> No
<input type="checkbox"/> Minimum		<input type="checkbox"/> Minimum		<input type="checkbox"/> Minimum	
<input type="checkbox"/> Medium		<input type="checkbox"/> Medium		<input type="checkbox"/> Medium	
<input type="checkbox"/> Severe		<input type="checkbox"/> Severe		<input type="checkbox"/> Severe	
<input type="checkbox"/> Very Severe		<input type="checkbox"/> Very Severe		<input type="checkbox"/> Very Severe	

5. How would appraise the overall tolerability of this type of procedure?

- High
- Middle
- Low

6. Time subtracted from normal activities

- 0-2 hours
- 3-4 hours
- 5-6 hours
- 7-8 hours
- > 8 hours

7. How would you evaluate the way the results were communicated?

- Optimal
- Good
- Mean
- Insufficient
- Bad

8. Have you undergone other endoscopic procedures?

- Colonoscopy/Ileoscopy
- EGDS

The questions that follow concern the endoscopic procedure referred to in question 8

9. The procedure CS/EGDS was:

- Very easy
- Easy
- Tolerable
- Difficult
- Very difficult

10. Did you experience pain during the procedure?

- No pain
- Mild
- Moderate
- Severe
- Extreme

11. Did you experience pain after the procedure?

- No pain
- Mild
- Moderate
- Severe
- Extreme

12. Difficult to move and state of anxiety of CS/EGDS

- | | | | |
|--------------------------------------|------------------------------|--------------------------------------|------------------------------|
| A) <i>Difficulty to</i> | <input type="checkbox"/> YES | C) <i>State of</i> | <input type="checkbox"/> YES |
| <i>move:</i> | <input type="checkbox"/> NO | <i>anxiety</i> | <input type="checkbox"/> NO |
| <input type="checkbox"/> Minimum | | <input type="checkbox"/> Minimum | |
| <input type="checkbox"/> Medium | | <input type="checkbox"/> Medium | |
| <input type="checkbox"/> Severe | | <input type="checkbox"/> Severe | |
| <input type="checkbox"/> Very Severe | | <input type="checkbox"/> Very Severe | |

13. Overall how would you evaluate the tolerability of this type of procedure?

- High
- Middle
- Low

14. Time subtracted from normal activities

- 0-2 hours
- 3-4 hours
- 5-6 hours
- 7-8 hours
- > 8 hours

15 How would you evaluate the way the results were communicated?

- Optimal
- Good
- Mean
- Insufficient
- Bad

Additional information

16. Age _____

17. Gender:

- M
- F

18. Status

- Single
- Married
- Cohabiting

19. Education:

- Primary school
- Secondary school
- Degree
- Master

20. Occupation:

- worker
- Employee
- Manager
- Trader
- Entrepreneur
- Student
- Housewife
- Consultant
- Retired
- Unemployed
- Other

age.na.s - Agenzia Nazionale per i Servizi Sanitari Regionali

Sezione A.G.P. - Centro Stampa

Via Puglie 23, 00187 – Roma .
Tel. 06.427491 – fax. 06.42749488
www.agenas.it e-mail info@agenas.it